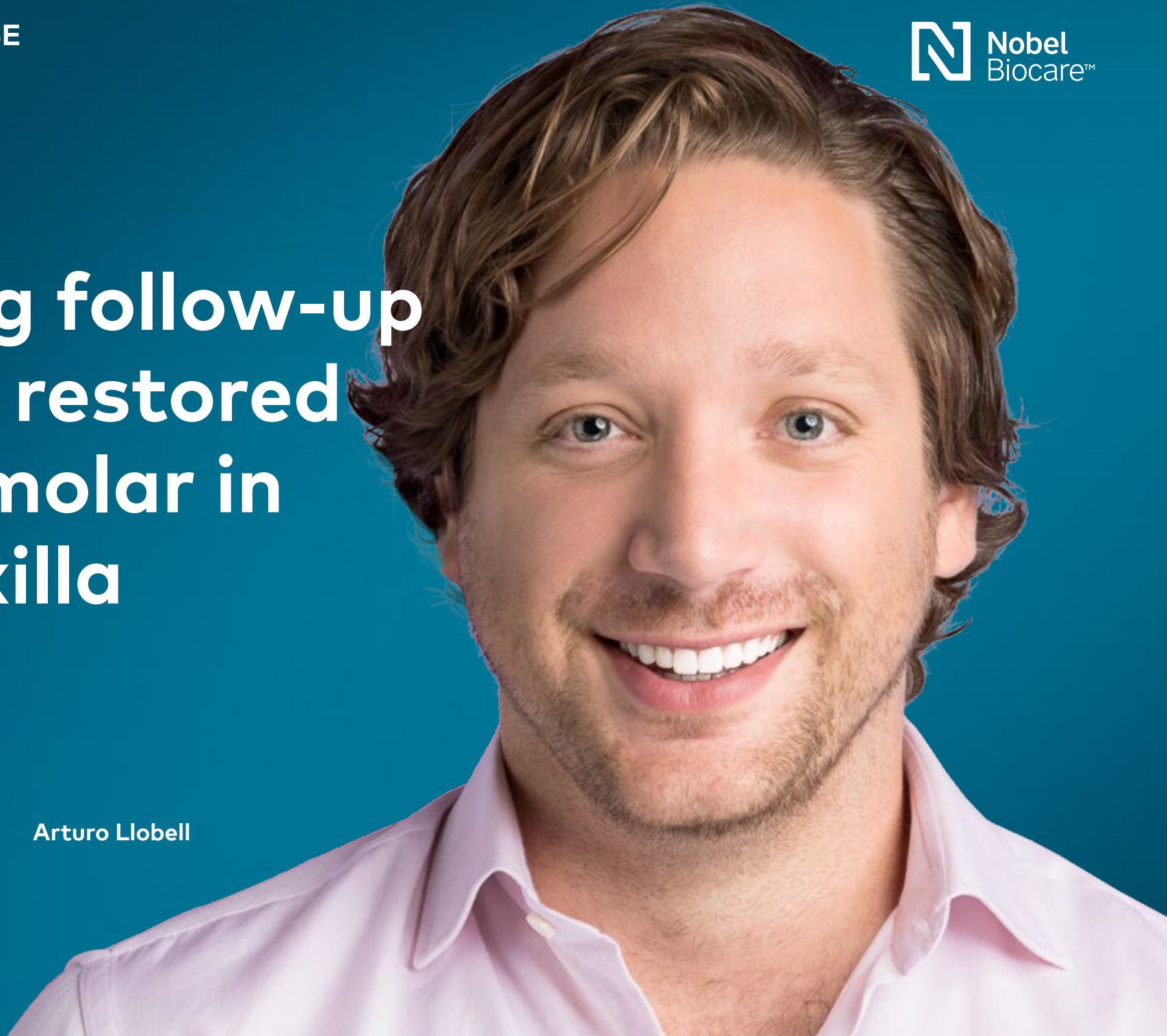

CLINICAL CASE



Long follow-up of a restored premolar in maxilla

Arturo Llobell





Arturo Llobell

Case description

57-month follow-up NobelParallel™ CC Implant

Patient

80 years, female, healthy dentition

Clinical situation

Medium to soft bone at healed site 14

Surgical solution

Full flap, NobelParallel™ CC

Restorative solution

NobelProcera® Zirconia Abutment and Coping

Surgery date

July 2014


Total treatment time

4 years 9 months

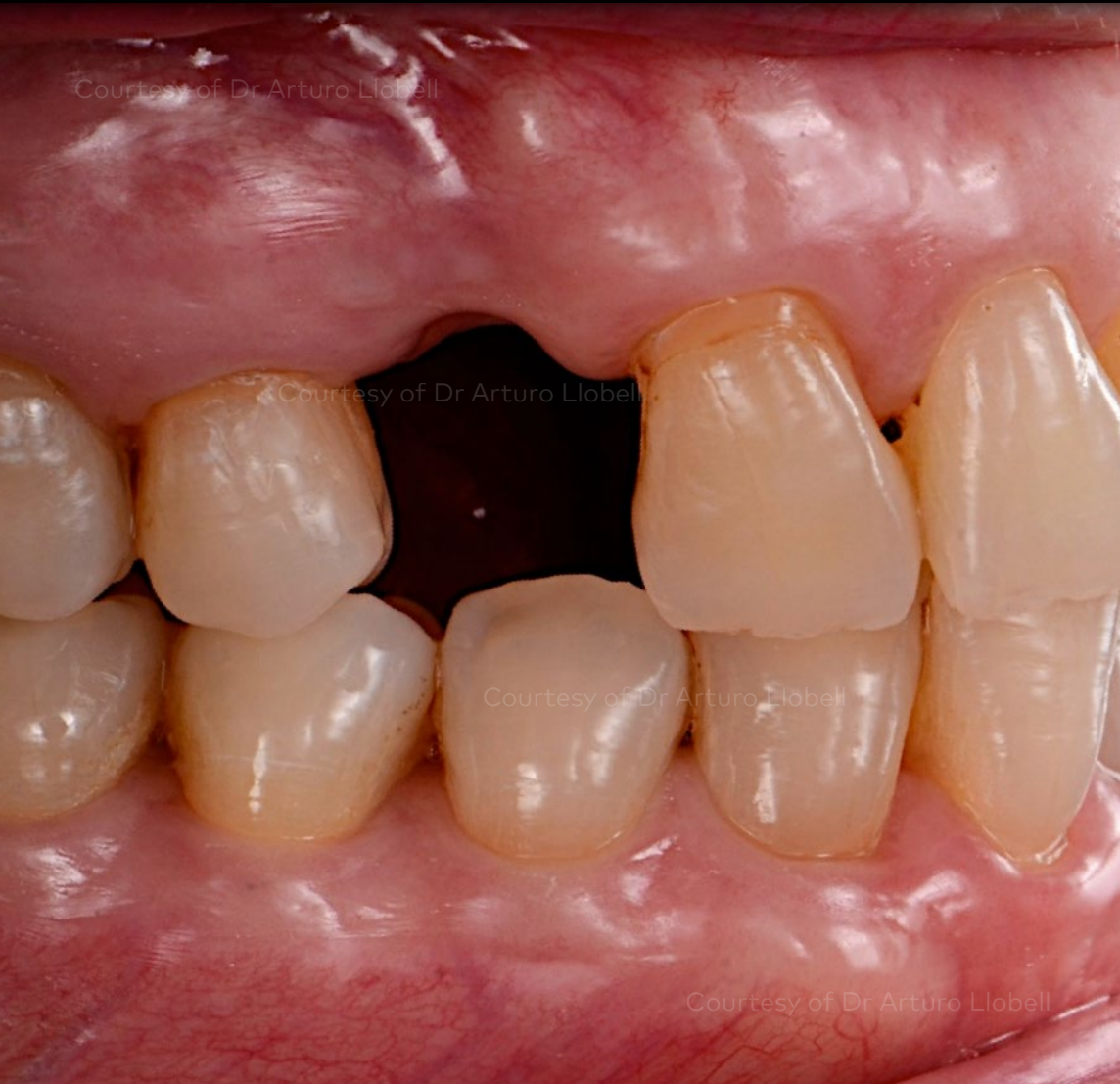Tooth position

14

Patient presented with a missing premolar and received NobelParallel™ CC implant upon raising a full flap, followed by the restoration with a NobelProcera® zirconia abutment and coping. Long-term follow-up demonstrates good bone and soft-tissue stability.



Initial clinical situation

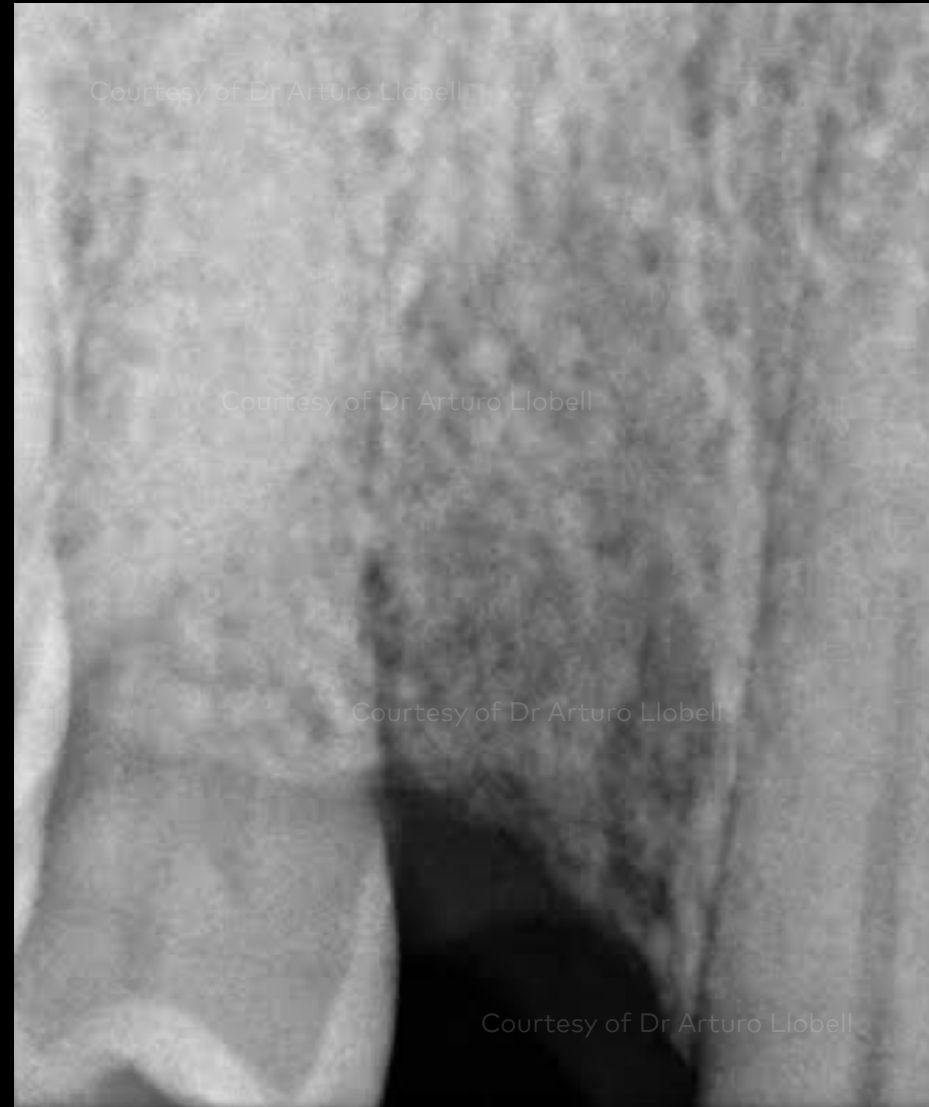

Healed site 14 with slight bone loss at position.
Soft tissue recession on site 13 is not a concern for the patient

Surgical procedure

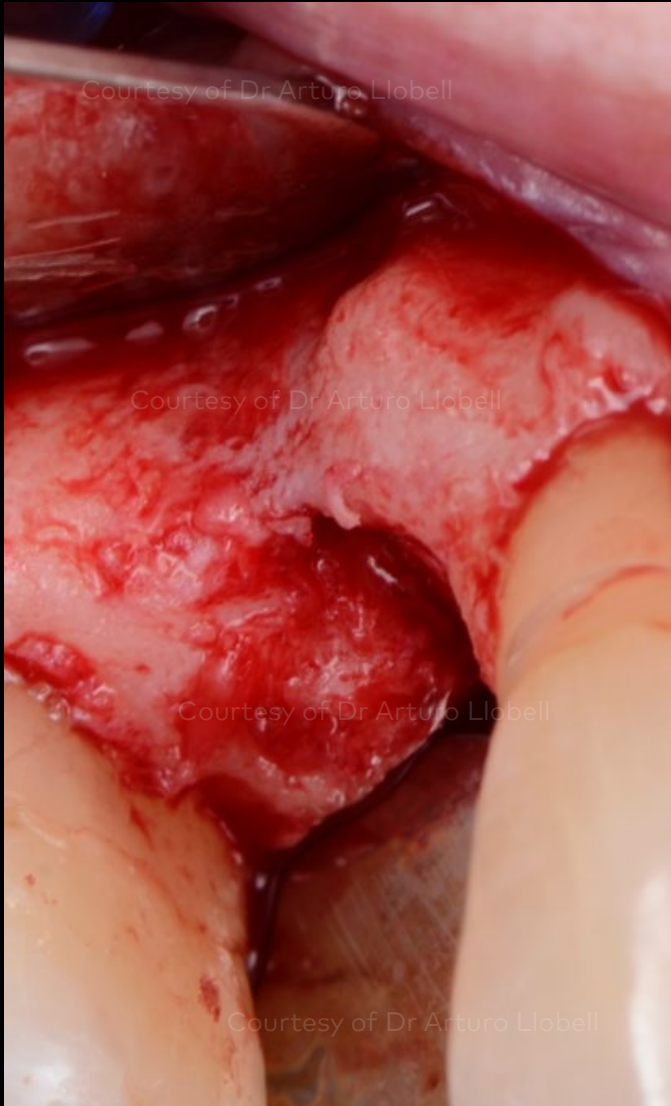Restorative procedure

Outcome



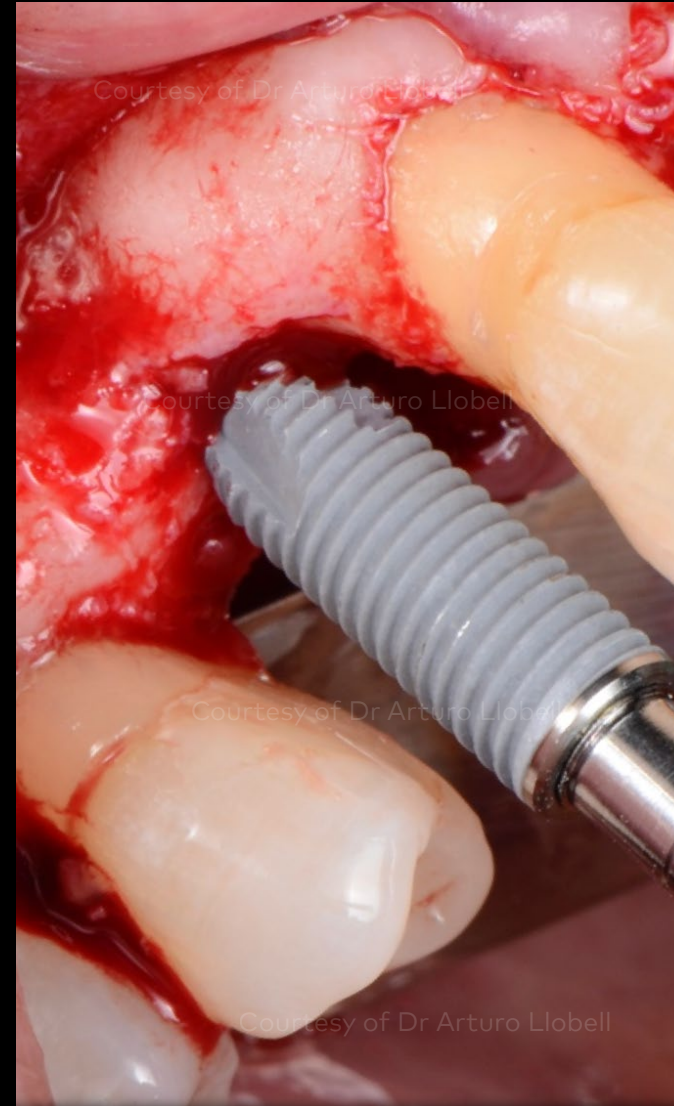Panoramic X-ray taken before the surgery

Initial clinical situation



Surgical site with flap raised.
Moderate bone quality is visible

Surgical procedure



Placing the NobelParallel™ CC RP 4.3x11.5 implant.
Insertion torque: 28 Ncm

Restorative procedure

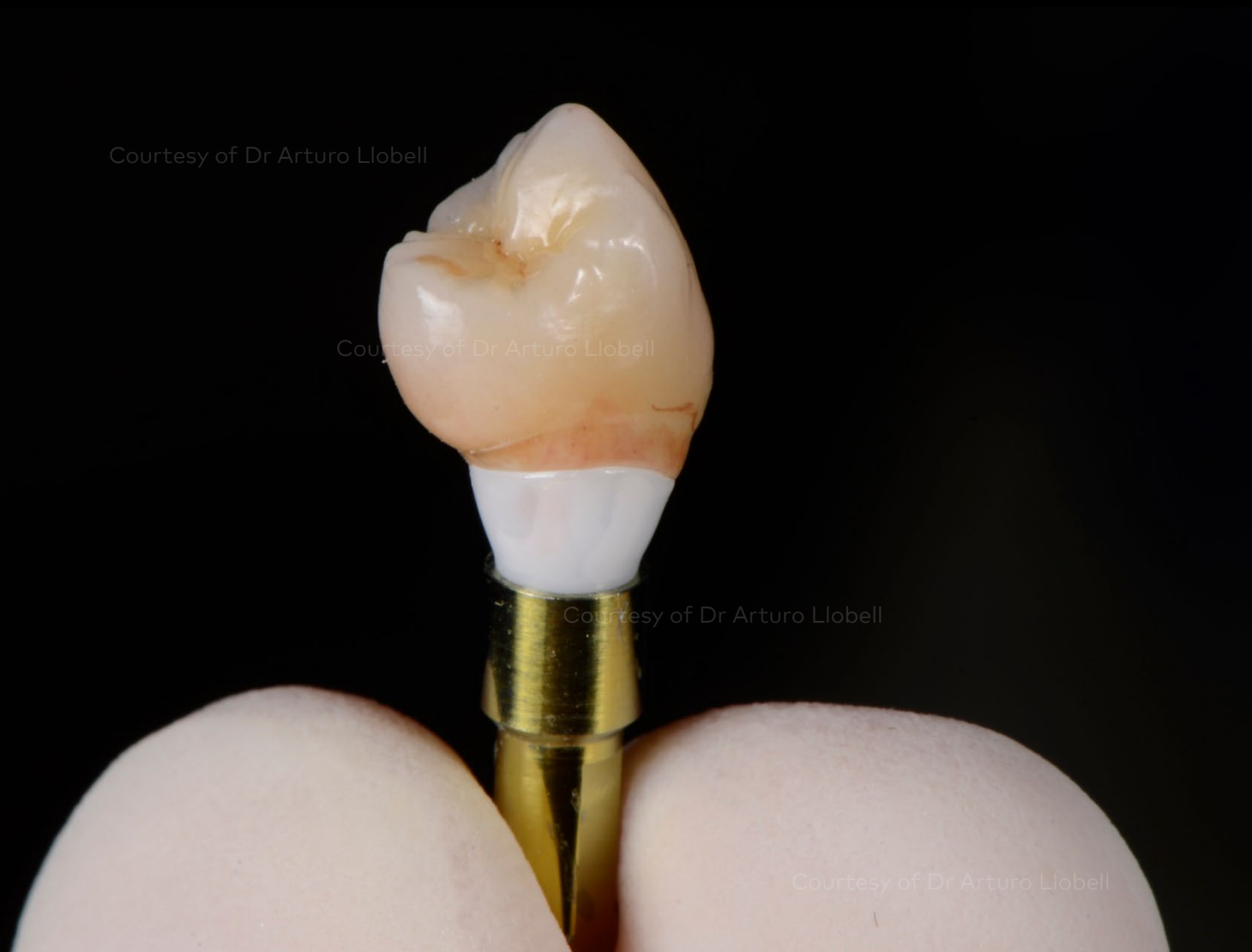Outcome

Initial clinical
situation

Surgical
procedure

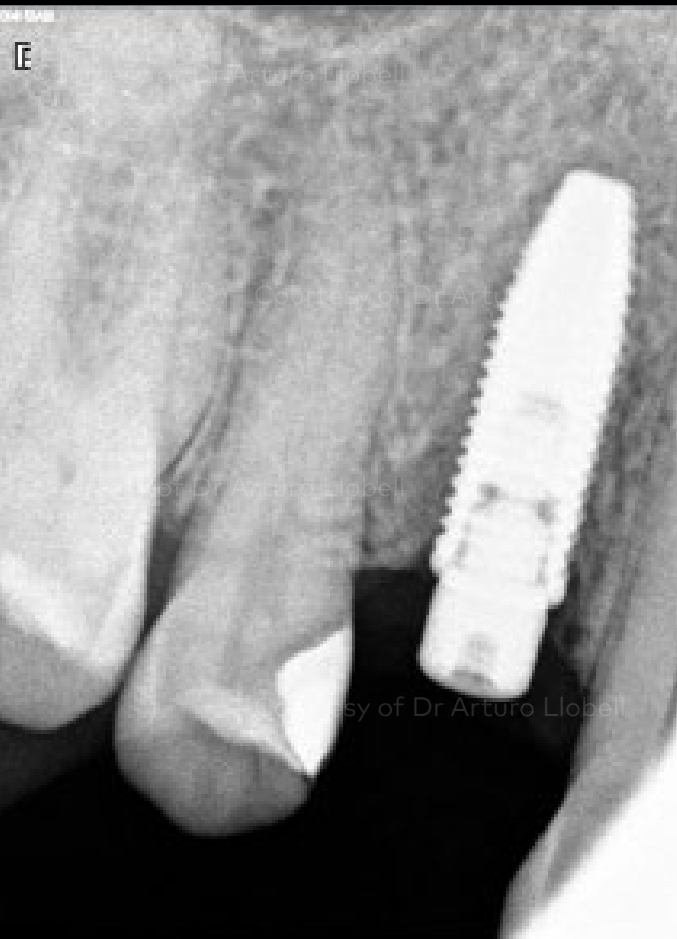Restorative
procedure

Outcome

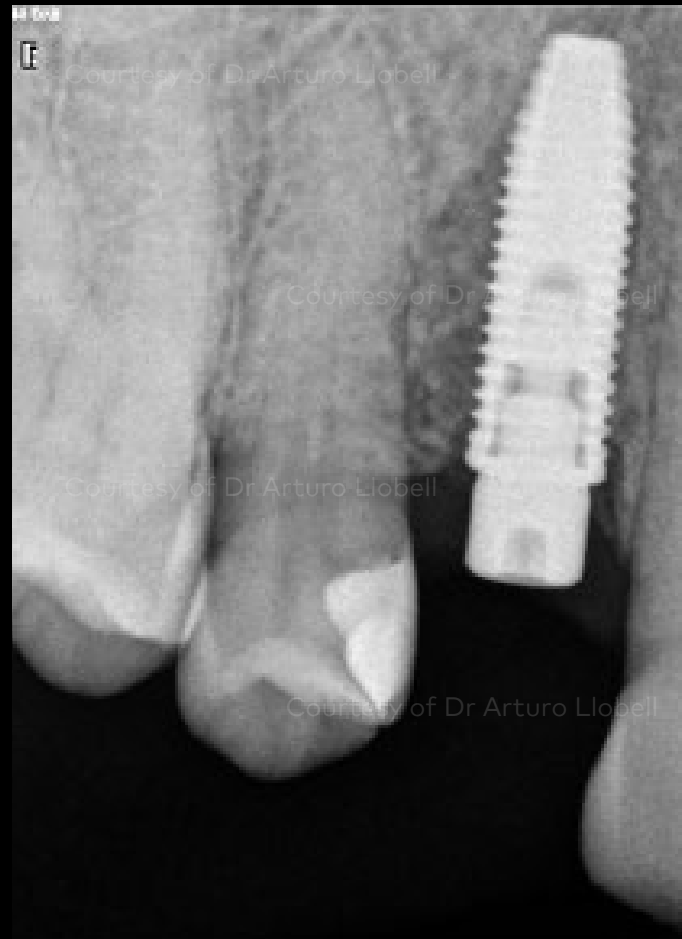

NobelProcera® crown FCZ with porcelain on NobelProcera® abutment

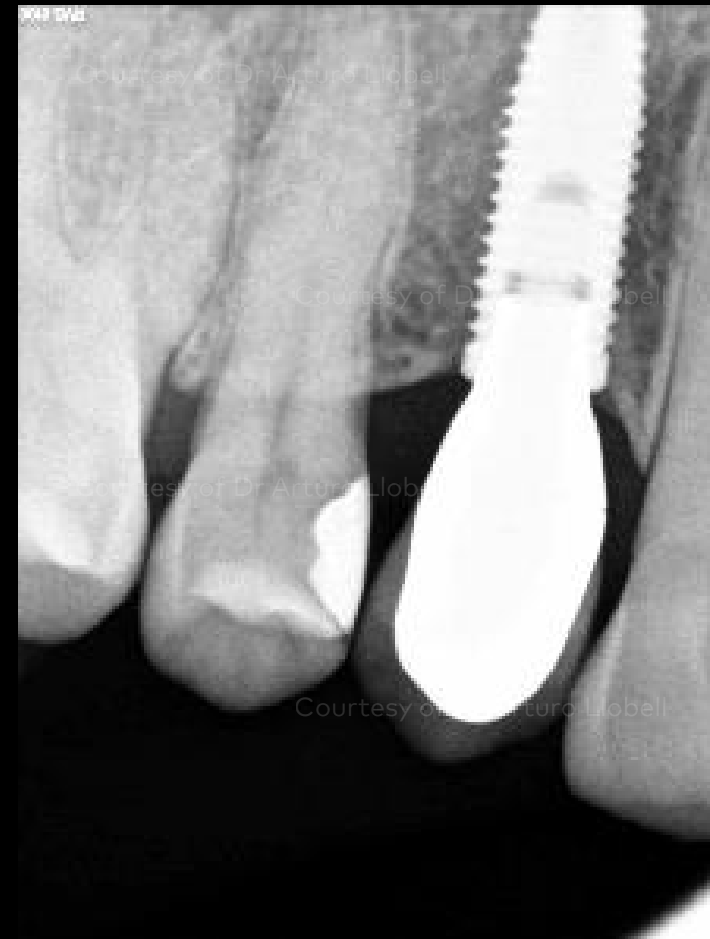Initial clinical situation



Surgical procedure



Restorative procedure



Outcome

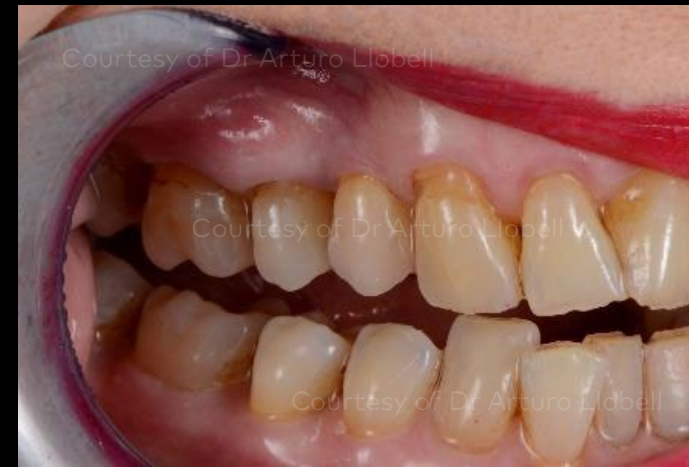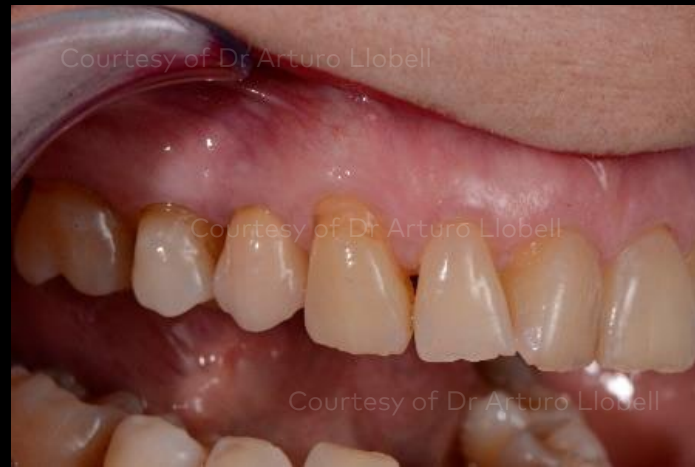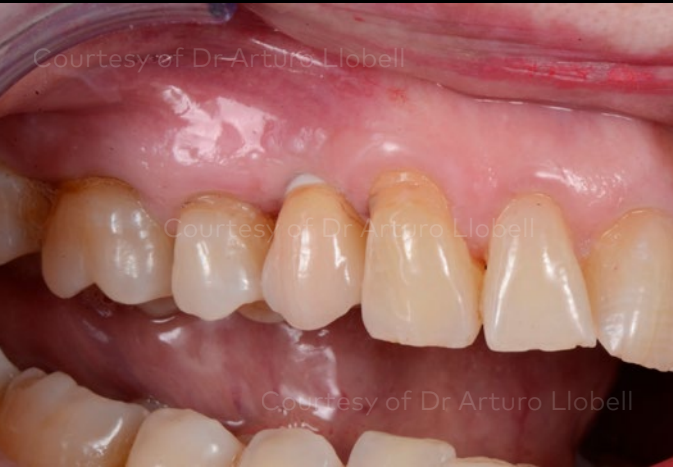X-rays taken at the day of surgery, at 4 and 54 months after the surgery

Initial clinical situation

Surgical procedure

Restorative procedure

Outcome



Clinical view at 7, 12 and 54 months after the surgery

Case courtesy of Arturo Llobell

