


Successful clinical outcomes with TiUltra™ surface: Emerging data

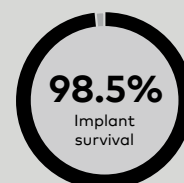
Why TiUltra? Design rationale¹

- Promote osseointegration and bone stability
- Reduce bacterial adhesion in the coronal region
- Limit peri-implantitis



Successful osseointegration

High mean implant survival of 98.5%²⁻⁹ with up to 3-year follow-up



12 Clinical studies



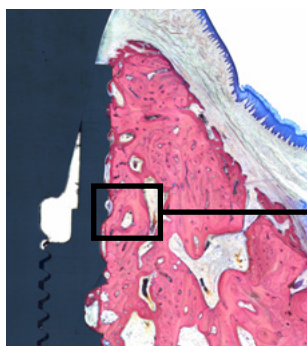
1,275 Patients




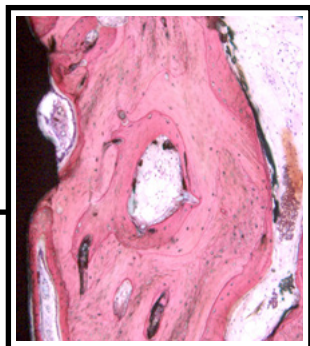
1,967 Implants

Early formation of bone-to-implant contact

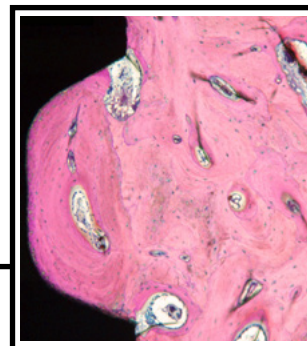
- Comparable to TiUnite™ as confirmed in the minipig animal model¹⁰




NobelActive TiUltra at 3 weeks after implant insertion



NobelActive TiUltra 13 weeks after implant insertion



TiUltra™ surface eliminates the risk of contamination from sand-blasting particles^{11,12}

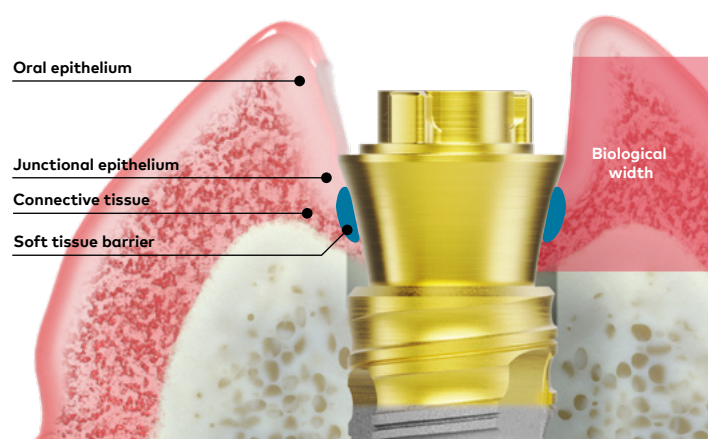


SEM images of moderately rough surfaces manufactured with different technologies. Left, sand-blasted and acid-etched surface; note the Al_2O_3 particles (black).¹² Right, anodized surface (Nobel Biocare, data on file).

Selected key factors to promote healthy marginal bone response

Soft tissue seal

Soft tissue attachment at implant/abutment system protects the underlying bone from the bacteria present in the oral environment. This attachment is created by peri-implant junctional epithelium that adheres to the abutment or implant surface via hemi-desmosomes.¹³ When an abutment or abutment base is placed on the day of surgery and left in place, a soft tissue barrier can form early in the process and will remain undisturbed, thus effectively protecting the underlying bone.¹⁴ Xeal surface additionally facilitates soft tissue adhesion by promoting epithelial cell proliferation.¹⁵



Prosthetic fit

Adequate fit of the prosthetic component on the implant minimizes the micro-gap at the implant junction. Conversely, a poorly fitting cover screw leads to a micro-gap that can result in increased leakage, which in turn may cause marginal bone loss and peri-implantitis.¹⁶

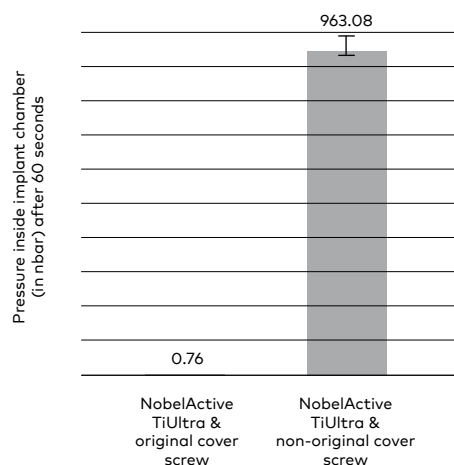


NobelActive TiUltra & original cover screw



NobelActive TiUltra & non-original cover screw

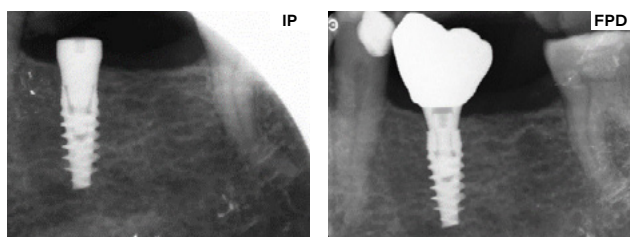
Leakage under static conditions



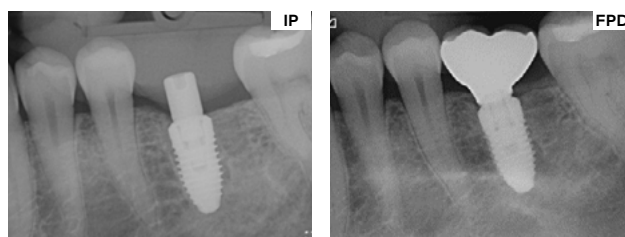
Watch the leakage test

Osseointegration of TiUltra™ implants: Clinical data

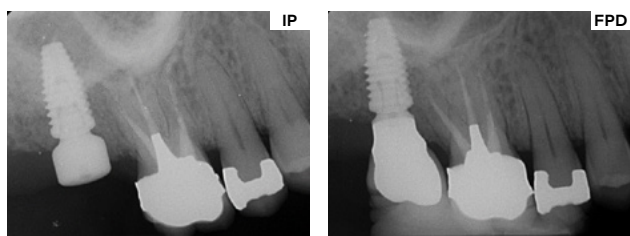
Clinical cases demonstrating excellent marginal bone response at TiUltra implants from implant placement (IP) to final prosthesis delivery (FPD). Periapical radiographs collected in the multi-center real-world prospective study with 1000 patients treated with TiUltra implants (T-192). Nobel Biocare, data on file.



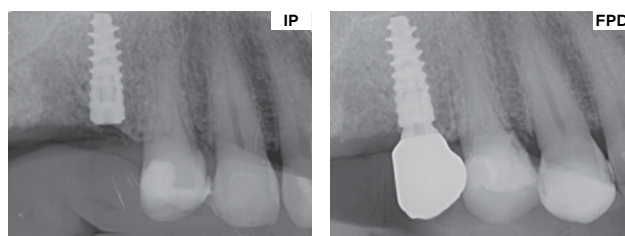
NobelActive TiUltra



NobelReplace CC TiUltra



NobelParallel CC TiUltra

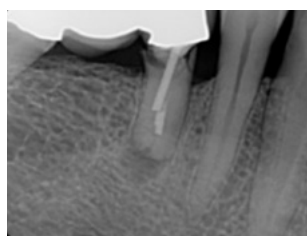


Nobel Biocare N1

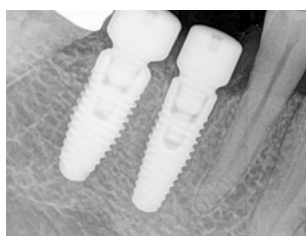Images courtesy of Drs M Roig, Spain; H Antoun, France; G Liddelow, Australia; and O Centrella, Switzerland

Clinical case: Immediate placement

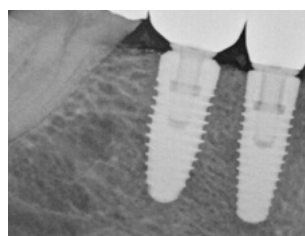
Stable marginal bone maintained throughout the follow-up in a patient treated with two TiUltra surface implants. Clinical case from the multi-center real-world prospective study with 1000 patients treated with TiUltra implants (T-192). A 49-year-old non-smoker male presented with a fractured, endodontically-treated tooth (FDI position 45) supporting a bridge, which needed to be removed. Immediately after the extraction of the premolar, a NobelReplace CC TiUltra was placed, and an additional NobelReplace CC TiUltra implant was inserted into the healed FDI 46 site. The final prosthesis delivery (FPD) took place 6.2 months later. Last follow-up visit, 14.9 months after the FPD, demonstrated excellent bone stability. Both, at FDP and FUP, there were no signs of inflammation (not shown).



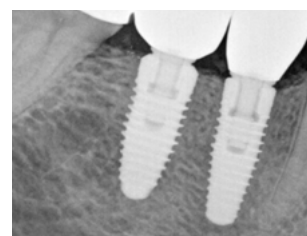
Pre-treatment



Implant placement



FPD

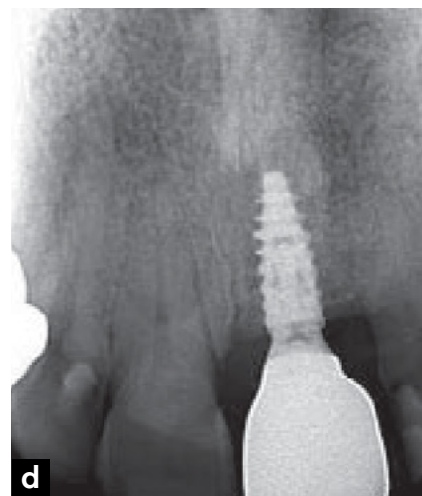
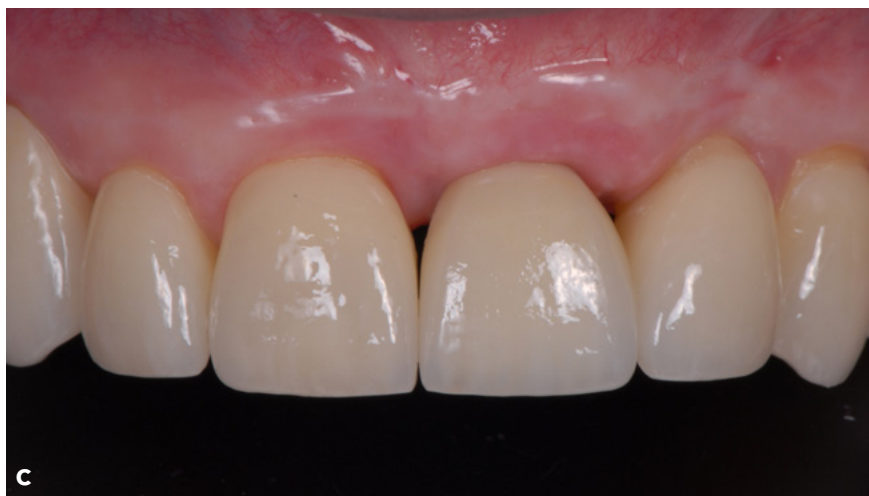
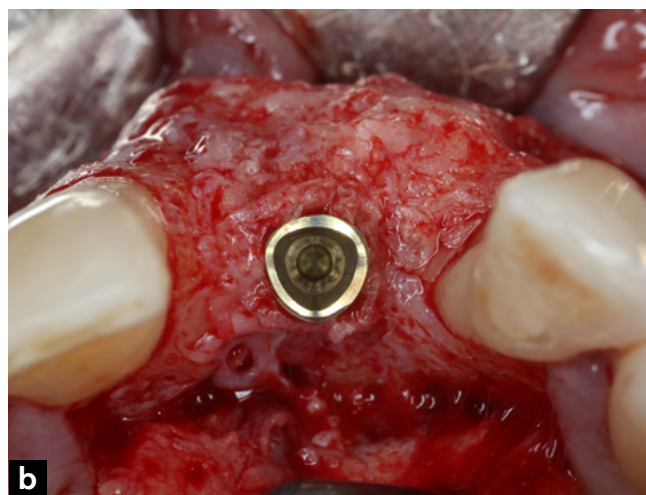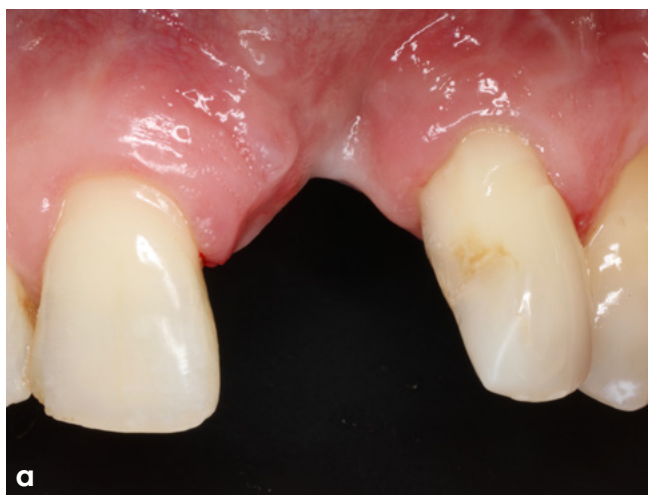1-year follow-up

Images courtesy of Dr T Eshraghi, USA

Clinical case: Placement after vertical ridge augmentation

Successful TiUltra surface implant osseointegration in an augmented ridge. A systemically healthy 55-year-old male patient diagnosed with peri-implantitis at the maxillary left lateral incisor position and with associated severe bone loss underwent implant removal (a), then vertical ridge augmentation, and periodontal regeneration procedures. Seven months after augmentation, the patient received a TiUltra surface implant (Nobel Biocare N1) (b), and the site was further augmented to increase both bone and soft tissue volume at the same time. An additional soft tissue graft was carried out six months later. The final prosthesis delivery took place two months after implant uncovering (c,d). Reprinted from Urban et al.¹⁷ with permission from Quintessence Publishing Company Inc.



Images courtesy of Dr I Urban, Hungary

Patients in 50 countries have been treated with TiUltra surface implants



Dr. Chad Cravatta
USA

"I have envisioned and hoped for an implant surface like Nobel Biocare's TiUltra for many years. I am excited to use this innovative design to enhance my patients' long-term implant success."



Dr. Ana Ferro
Portugal

"We have been conducting a prospective study on the All-on-4 with NobelParallel CC TiUltra and Xeal abutments since 2019. The results are exciting since we have 100% implant survival, low marginal bone loss and minimum bacterial plaque accumulation³ around Xeal abutments."



Dr. Hui Zhao
China

"Launched in China in 2021, the implant and abutment with newly engineered TiUltra and Xeal surfaces have achieved tremendous clinical success. The gradually anodized surface with increasing roughness has excelled across a wide variety of protocols and all indications, ensuring outstanding osseointegration and excellent soft tissue integration. The technology improvement originates from the solid practice and brilliant innovation. Thank you, Nobel Biocare!"



Dr. Cristiano Susin
USA

"We have conducted several preclinical studies comparing TiUnite and TiUltra, and we observed similar levels of osseointegration, crestal bone level, and soft tissue healing for these surfaces. From a clinical perspective, TiUltra seems to achieve similar clinical outcomes while providing reassurance regarding biofilm control."



Dr. Bobby Birdi
Canada

"We've had far fewer implant failures the past year. (Personally, I've had none.) We haven't changed any protocol or how we're loading implants; the one big change is converting to the new surfaces. So I think this could be a key factor in our improvement, and time will tell."



Dr. Tristan Staas
the Netherlands

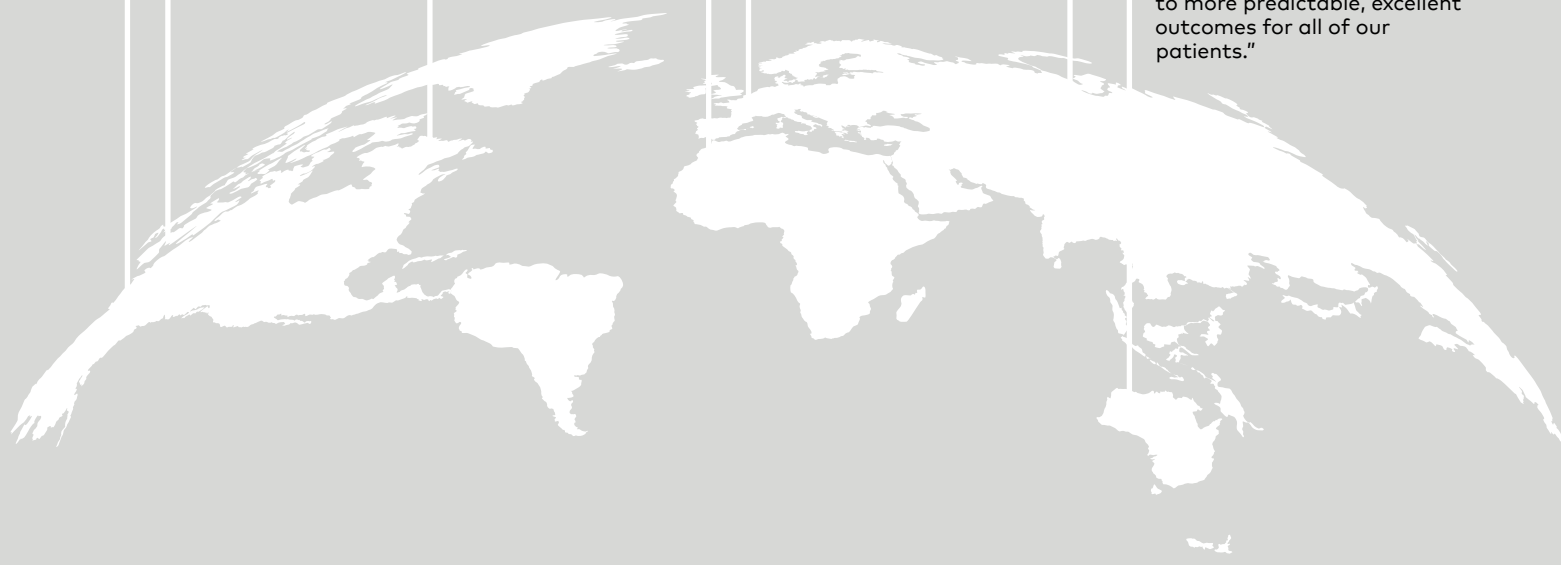"In our offices we use exclusively implants with the TiUltra surface over more than 5 years now, and together with the Xeal abutment surface we observe very stable hard and soft tissue levels, resulting in excellent esthetic outcomes."

The results of the prospective real-world T-192 study (we participate in 2 groups) confirm these clinical observations."



Dr. Glen Liddelow
Australia

"I've been using TiUltra implants for over 5 years now. They have performed exceptionally with bone consistently at or above the head of the implant. Whilst there have been no cases of peri-implantitis, I'm sure that if it occurs, it will be much more amenable to treatment. A 1000 patient study that we are part of, also shows exceedingly low levels of any inflammation. TiUltra is the culmination of well thought out science guiding the evolution of dental implants to more predictable, excellent outcomes for all of our patients."



References

1. Milleret V, Lienemann PS, Gasser A, Bauer S, Ehrbar M, Wennerberg A. Rational design and in vitro characterization of novel dental implant and abutment surfaces for balancing clinical and biological needs. *Clin Implant Dent Relat Res*. 2019 Mar;21 Suppl 1:15-24.
2. Robust papilla regeneration and marginal bone gain: 2-Year results from a prospective study. Fabbri G, Ban G, Lim HC, Noh K. *Clin Oral Impl Res*;34(S27):159-160.
3. All-on-4 concept using TiUltra surface implants and Multi-unit Xeal abutments: Report on the outcomes between 6 to 36 months. Ferro A, De Araújo Nobre M. *Clin Oral Impl Res*;34(S27):137-138.
4. A Retrospective Observational Study Assessing the Clinical Outcomes of a Novel Implant System with Low-Speed Site Preparation Protocol and Tri-Oval Implant Geometry. Fabbri G, Staas T, Urban I. *J Clin Med*. 2022 Aug 18;11(16):4859.
5. Navigation guided socket-shield technique for implant and pontic sites in the esthetic zone: A proof-of-concept 1-year prospective study with immediate implant placement and loading. Pozzi A, Arcuri L, Kan J, Londono J. *J Esthet Restor Dent*. 2022 Jan;34(1):203-214.
6. Dynamic navigation guided surgery and prosthetics for immediate loading of complete-arch restoration. Pozzi A, Hansson L, Carosi P, Arcuri L. *J Esthet Restor Dent*. 2021 Jan;33(1):224-236.
7. Evaluation of gradually anodized surface on four implant systems. A prospective, thousand-patient real-world study. Eshraghi et al. Poster presented at: AO 2024 annual meeting; March 7-9 2024; Charlotte, NC, USA.
8. Dynamic Navigation System for Immediate Implant Placement in the Maxillary Aesthetic Region. Battista E, Gasparro R, Cacciola M, Sammartino G, Marenzi G. *Applied Sciences*. 2022;12(11):5510.
9. Donker VJJ, Raghoobar GM, Vissink A, Meijer HJA. Digital Workflow for Immediate Implant Placement and Chairside Provisionalization in the Esthetic Zone. *Case Rep Dent*. 2022 Apr 1;2022:5114332.
10. Susin C, Finger Stadler A, Muszkopf ML, de Sousa Rabelo M, Ramos UD, Fiorini T. Safety and efficacy of a novel, gradually anodized dental implant surface: A study in Yucatan mini pigs. *Clin Implant Dent Relat Res*. 2019 Mar;21 Suppl 1:44-54.
11. Schupbach P, Glauser R, Bauer S. Al2O3 Particles on Titanium Dental Implant Systems following Sandblasting and Acid-Etching Process. *Int J Biomater*. 2019 Jun 2;2019:6318429.
12. Schupbach P, Glauser R., 2019, "Preventing aluminium oxide contamination of dental implant surfaces" Research OUTREACH (111). Available at: <https://researchoutreach.org/articles/preventing-aluminium-oxide-contamination-of-dental-implant-surfaces> (Accessed 2024/05/28).
13. Fischer NG, Aparicio C. Junctional epithelium and hemidesmosomes: Tape and rivets for solving the "percutaneous device dilemma" in dental and other permanent implants. *Bioact Mater*. 2022 Mar 19;18:178-198. doi: 10.1016/j.bioactmat.2022.03.019.
14. Fabbri G, Sorrentino R. A Biologically Driven Concept to Design the Emergence Profile Around Dental Implants: Surgical and Prosthetic Considerations to Optimize Hard and Soft Tissue Integration. *Int J Periodontics Restorative Dent*. 2021 Nov-Dec;41(6):913-921.
15. Nossowitz M, Teale M, Mathes S, Venturato A, Gasser A. Evaluation of anodized surfaces designed for improved soft tissue integration. *Foundation for Oral Rehabilitation (FOR)* 2019, pp. 1-7. www.for.org/scientificarticle/001
16. Sasada Y, Cochran DL. Implant-Abutment Connections: A Review of Biologic Consequences and Peri-implantitis Implications. *Int J Oral Maxillofac Implants*. 2017 Nov/Dec;32(6):1296-1307.
17. Urban IA, Tattan M, Ravid A, Saleh MH, Tavelli L, Avila-Ortiz G. Simultaneous Alveolar Ridge Augmentation and Periodontal Regenerative Therapy Leveraging Recombinant Human Platelet-Derived Growth Factor-BB (rhPDGF-BB): A Case Report. *Int J Periodontics Restorative Dent*. 2022 September/October;42(5):577-585.

More to explore



Watch roundtable
for discussing
Xeal and TiUltra
surfaces



See more
clinical cases



Summary
of scientific
literature



nobelbiocare/
xeal-tiultra

89337 EU 2407 © Nobel Biocare Services AG, 2024. All rights reserved. Distributed by: Nobel Biocare.

Disclaimer: Nobel Biocare, the Nobel Biocare logotype and all other trademarks are, if nothing else is stated or is evident from the context in a certain case, trademarks of Nobel Biocare. Please refer to nobelbiocare.com/trademarks for more information. Product images are not necessarily to scale. All product images are for illustration purposes only and may not be an exact representation of the product. Some products may not be regulatory cleared/released for sale in all markets. Please contact the local Nobel Biocare sales office for current product assortment and availability. Caution: Federal (United States) law or the law in your jurisdiction may restrict this device to sale by or on the order of a dentist or a physician. See Instructions For Use for full prescribing information, including indications, contraindications, warnings and precautions.

