

7-year follow-up of a central maxillary incisor restoration

Roberto Villa
Italy



Dr. Roberto Villa

Case description

7-year follow-up of a central maxillary incisor restoration

Patient

Female patient
19 years old

Implant

NobelReplace® CC RP
4.3x13 mm


Surgery date

October 2nd, 2011

Tooth position

Tooth 11

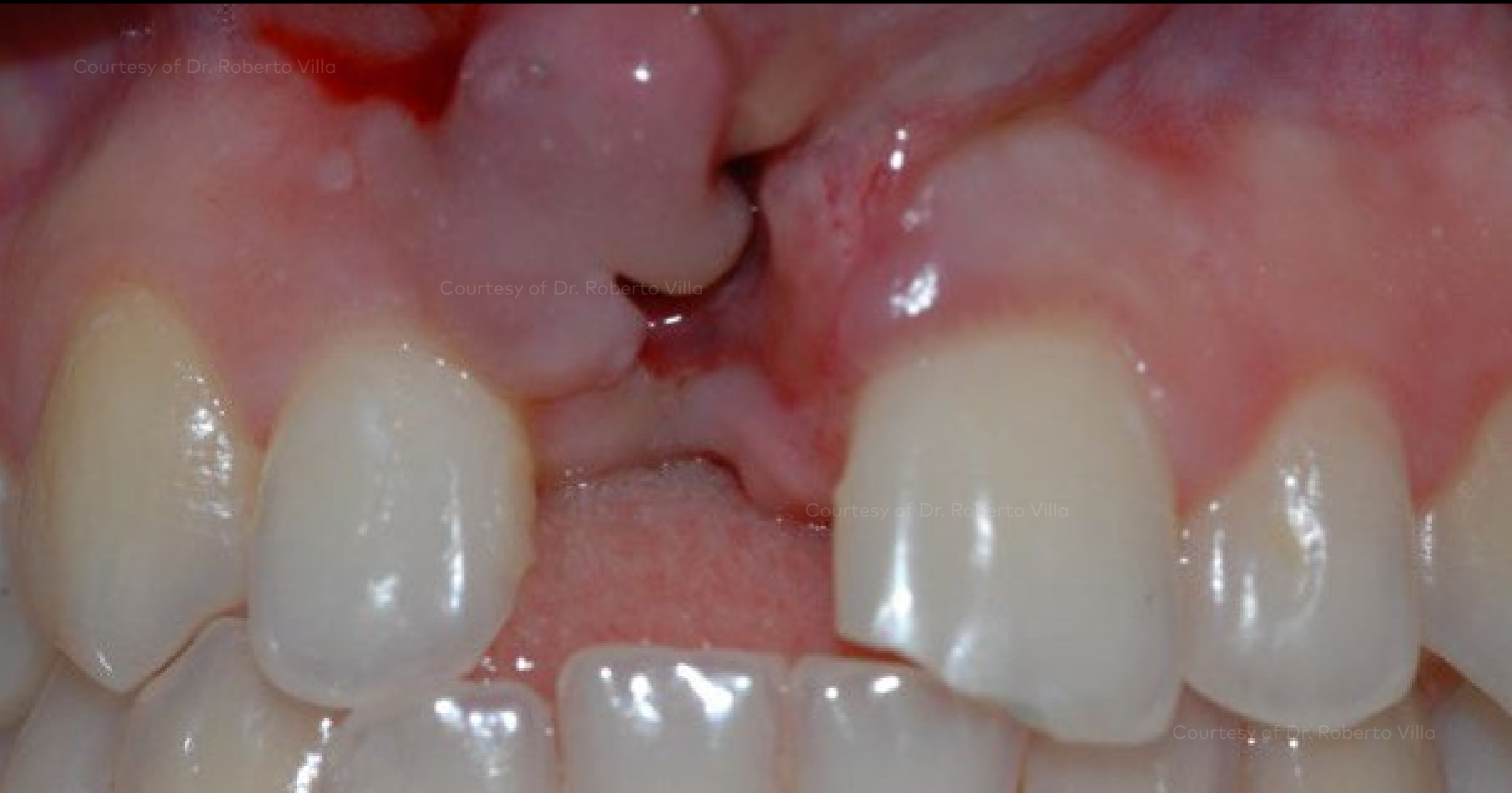Patient missing a central incisor due to trauma. Restored with a NobelReplace® CC implant using a flapped approach with soft tissue grafting to attain optimal esthetic results. At 7-year follow-up, bone levels and soft tissue health have been maintained.



Initial clinical situation

Surgical procedure

Outcome

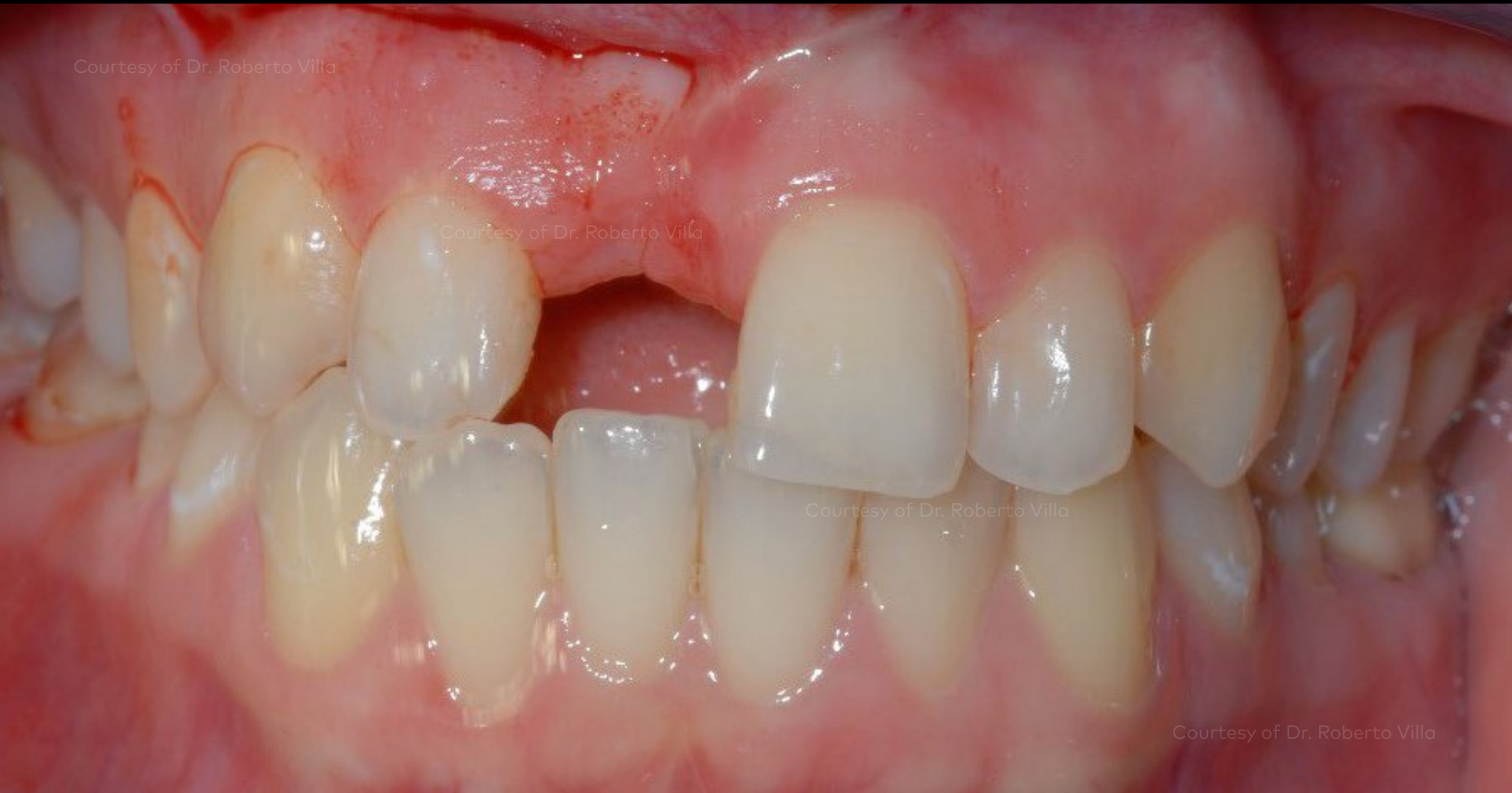

Loss of central incisor after trauma.

Initial clinical situation

Surgical procedure

Outcome

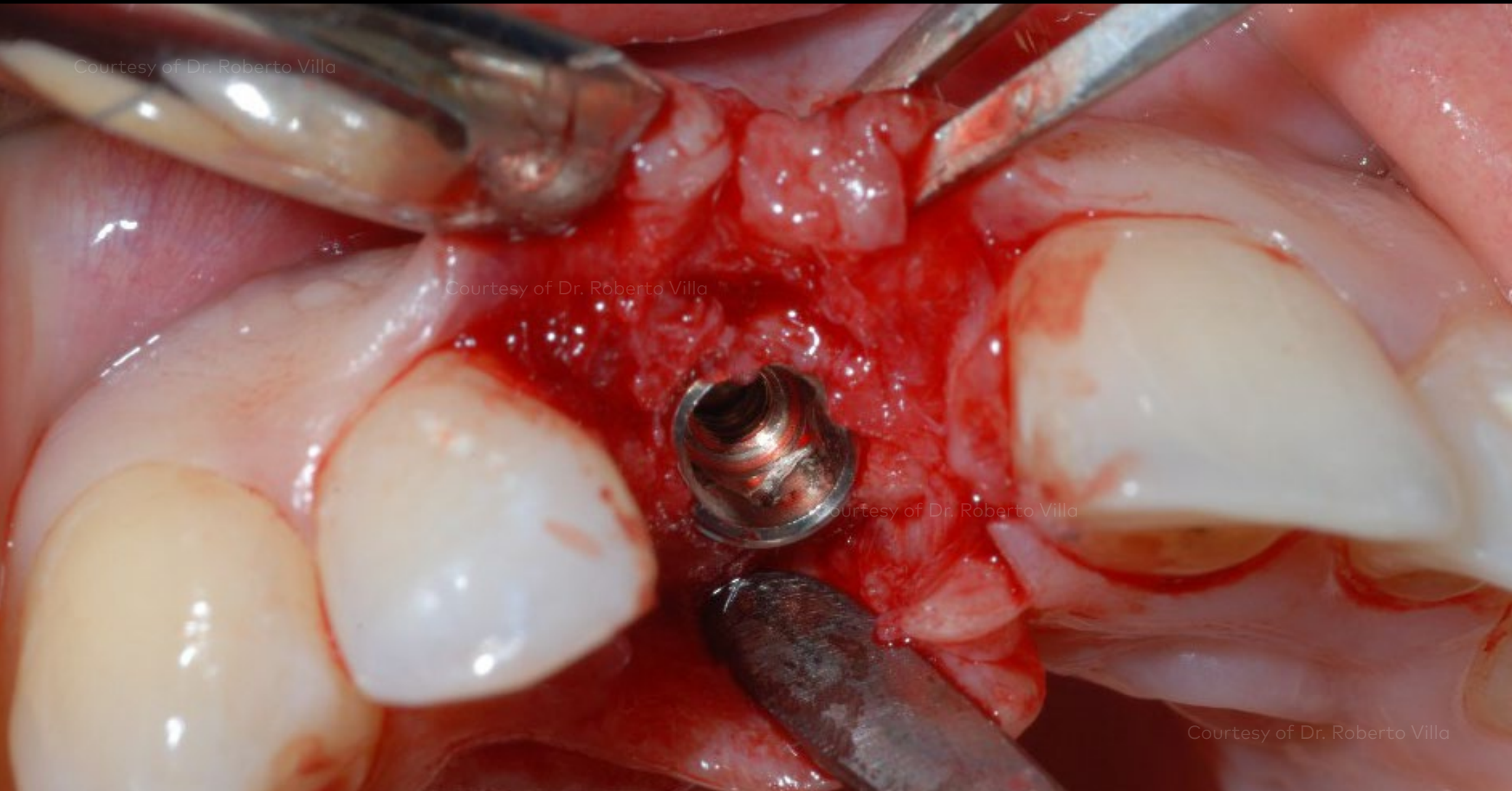


Initial clinical situation before implant placement.

Initial clinical situation

Surgical procedure

Outcome

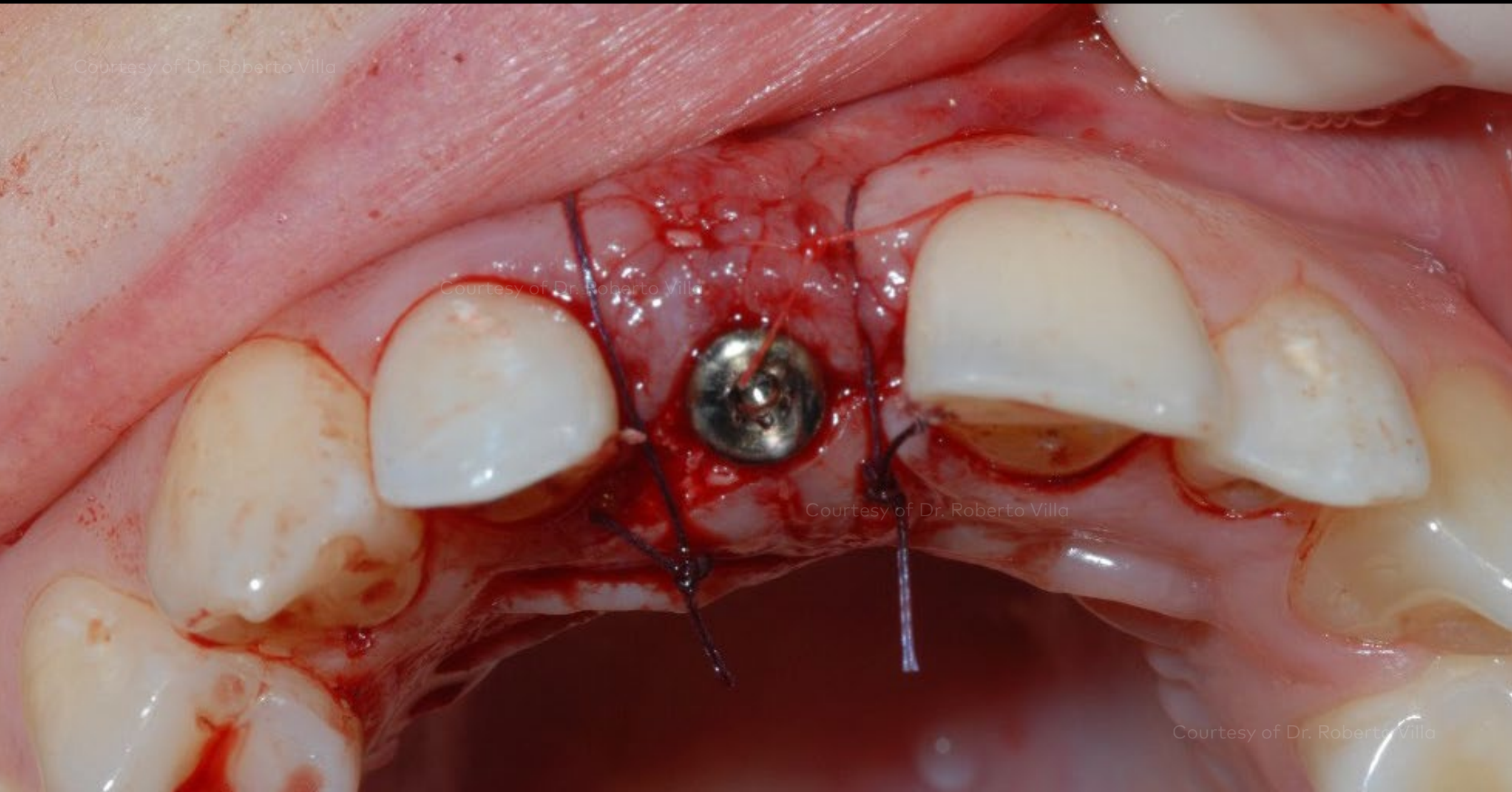


Placement of NobelReplace® Conical Connection implant.

Initial clinical situation

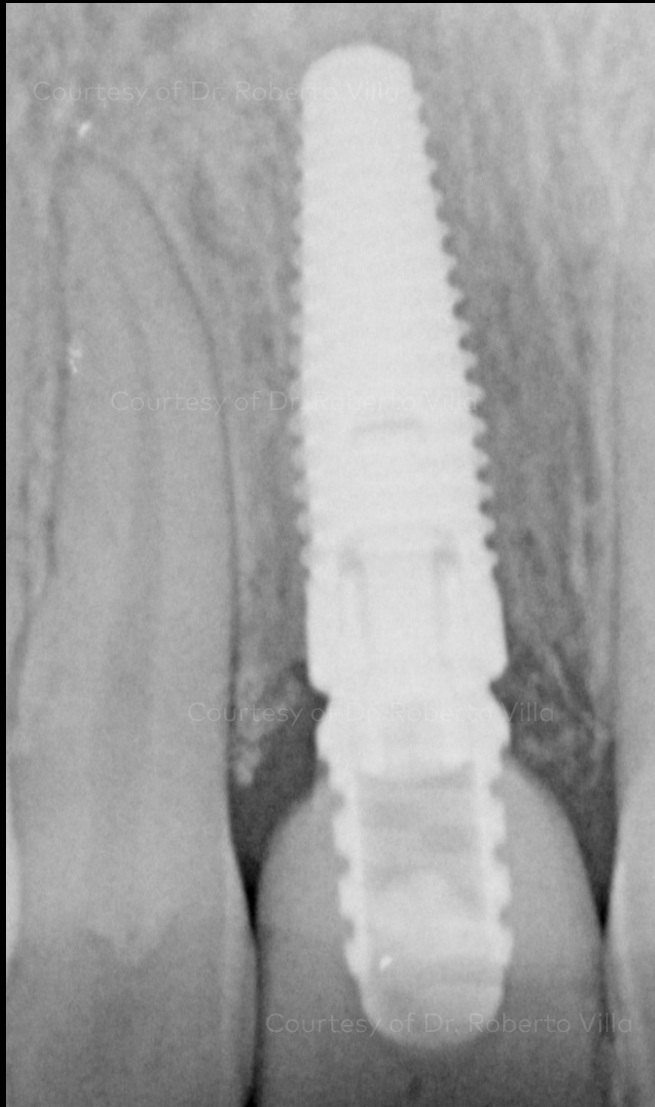
Surgical procedure

Outcome



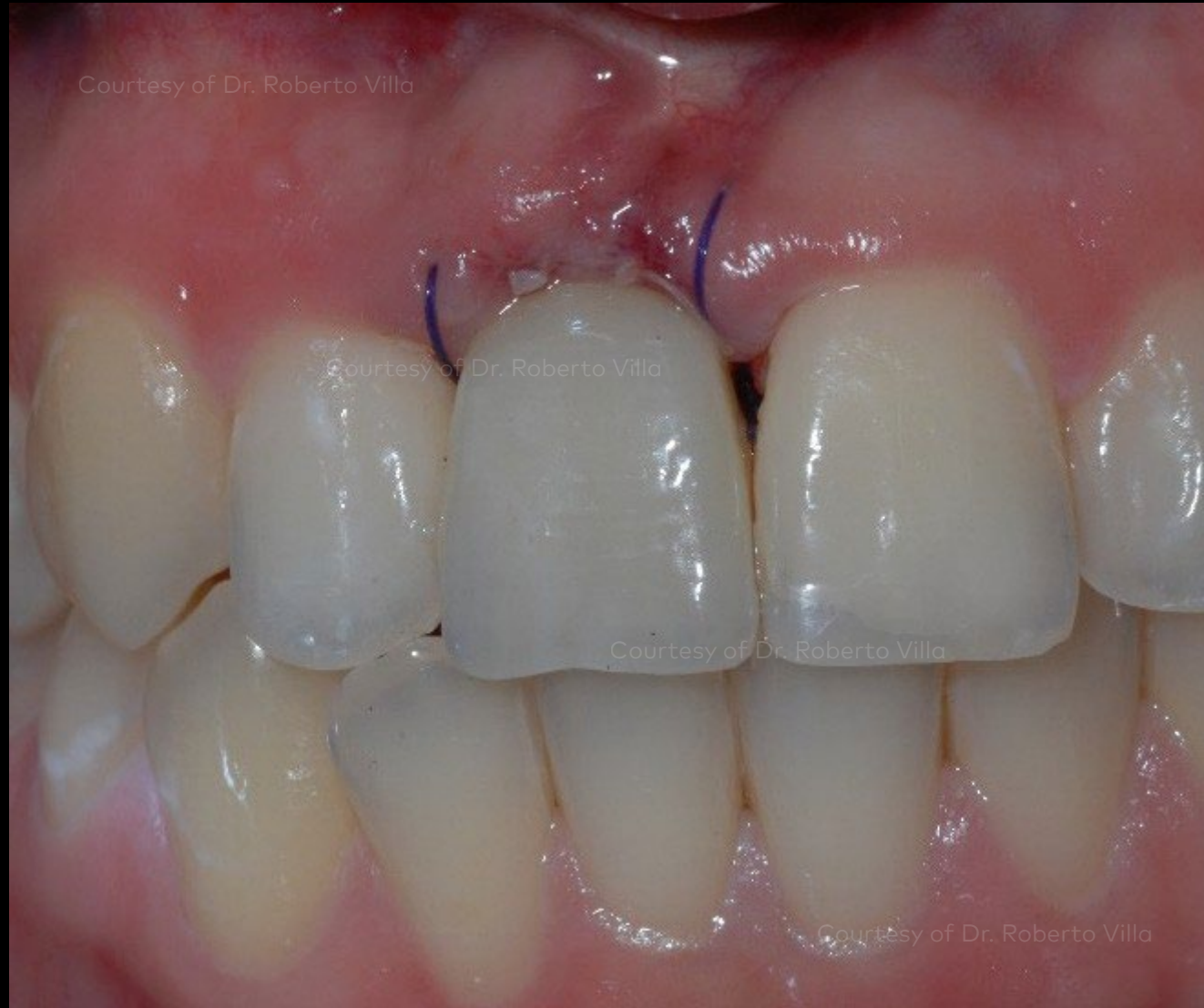Surgical site with soft tissue graft and healing abutment in place.

Initial clinical situation



X-ray following implant insertion and temporary restoration.

Surgical procedure



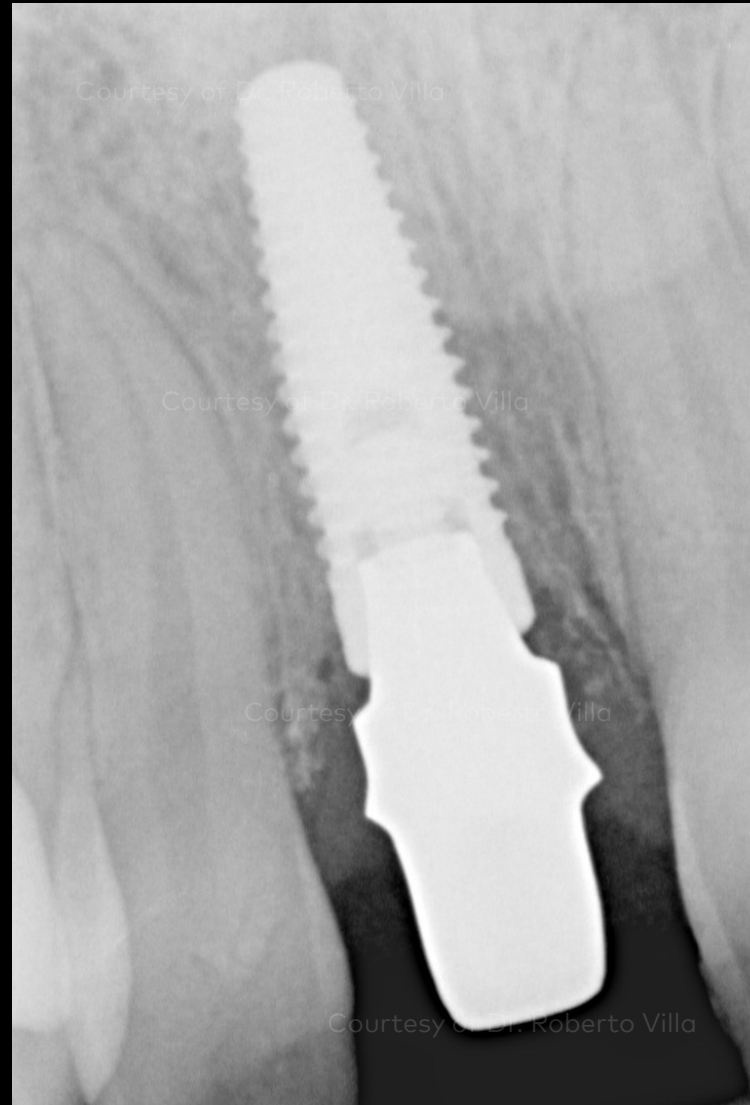Temporary restoration.

Outcome

Initial clinical situation

Surgical procedure

Outcome

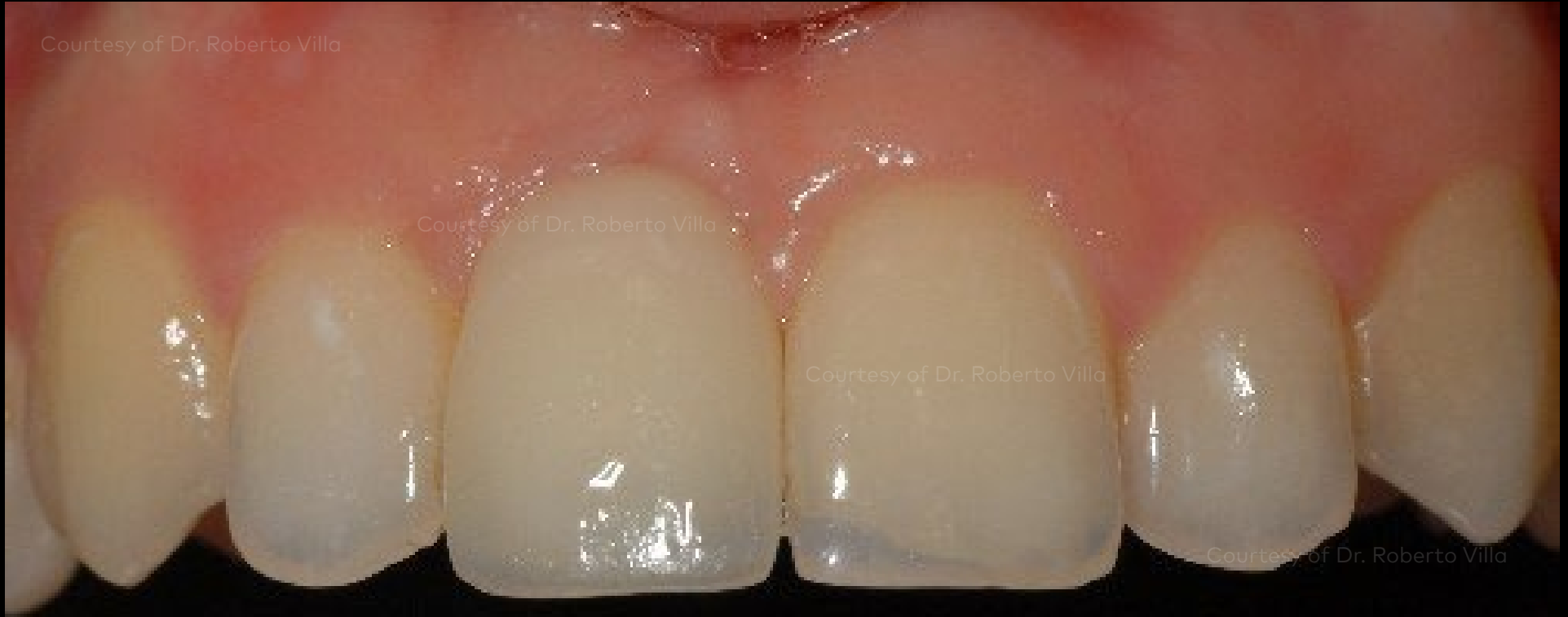

X-ray of implant and final restoration 5 months after surgery.

Initial clinical situation

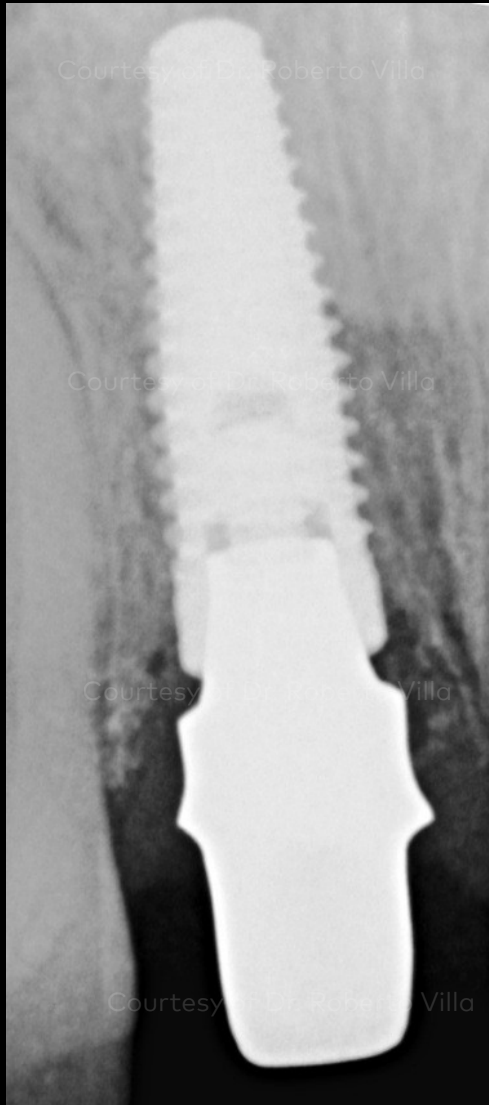Surgical procedure

Outcome



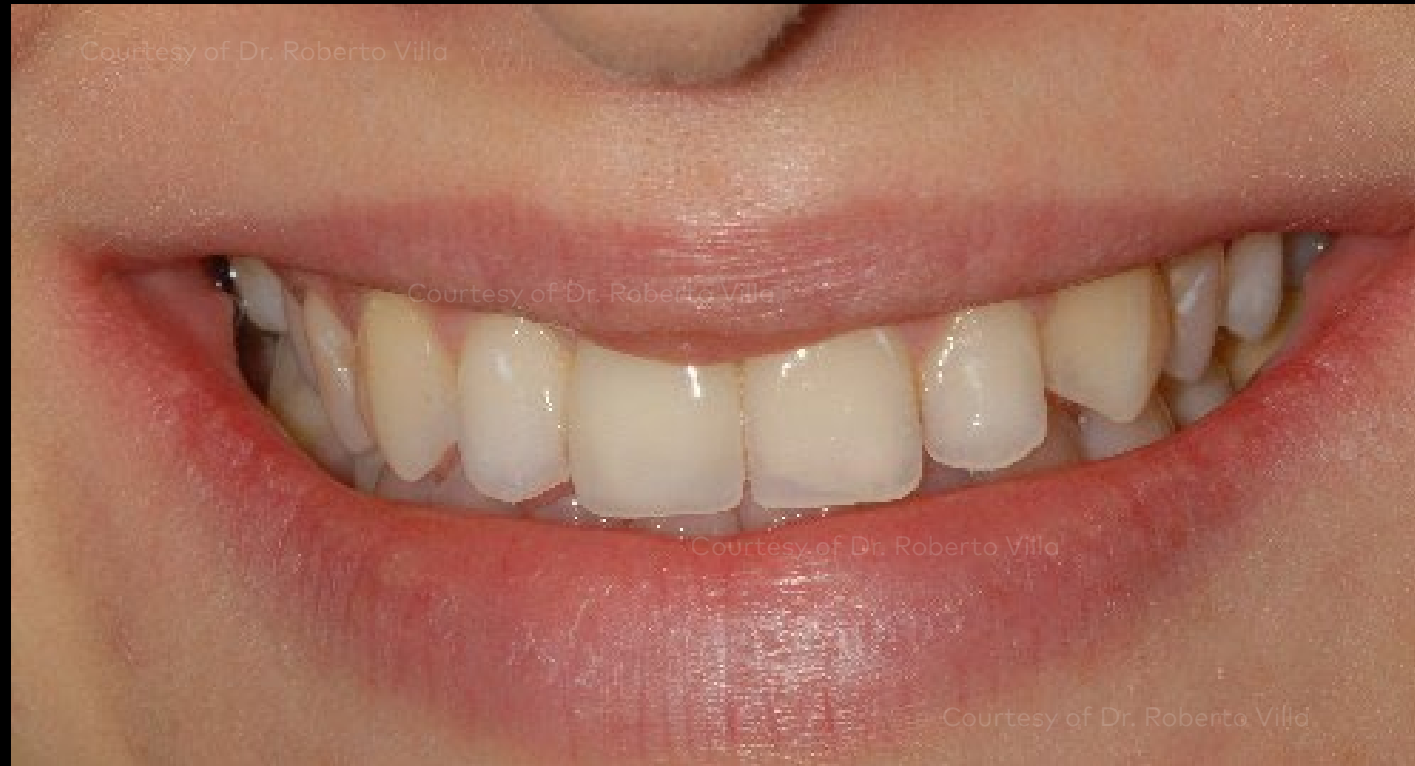Clinical view 1 year after implant insertion exhibits excellent soft tissue outcomes.

Initial clinical situation



X-ray 1 year after insertion

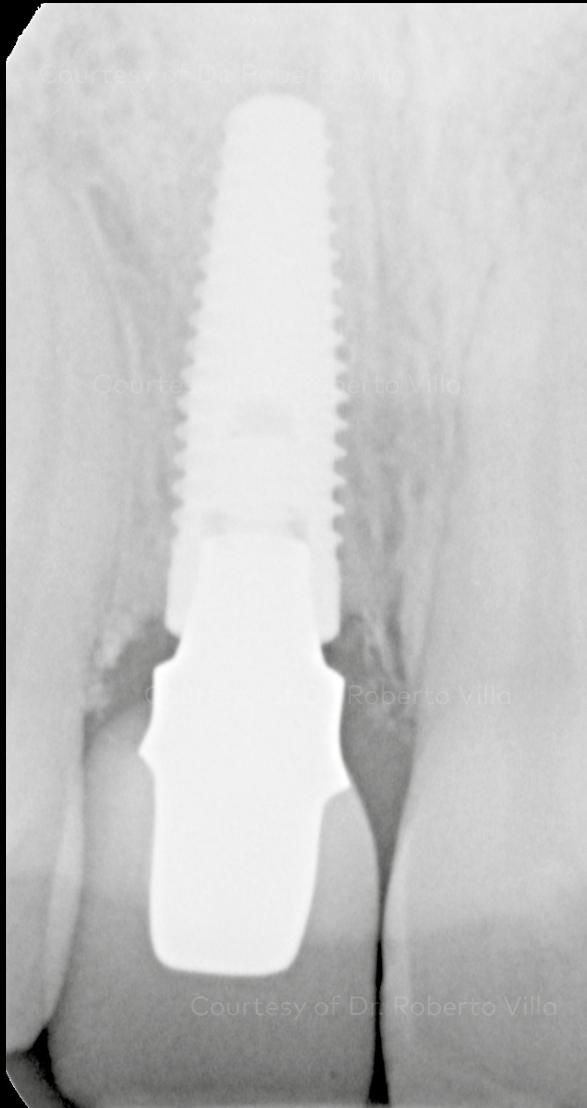
Surgical procedure



1 year follow-up

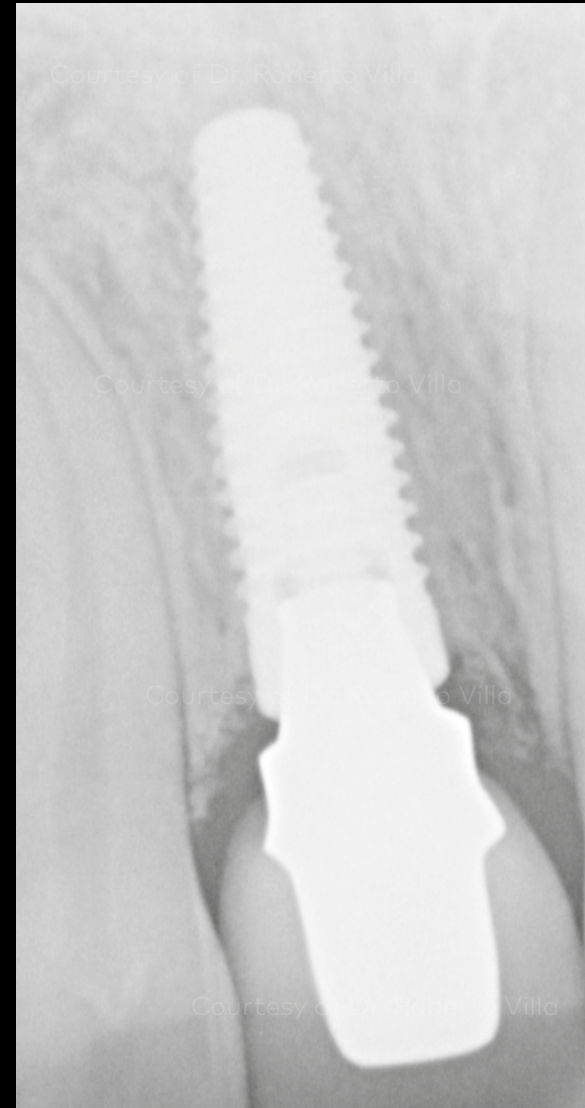
Outcome

Initial clinical situation



X-ray after 3 years of follow-up

Surgical procedure



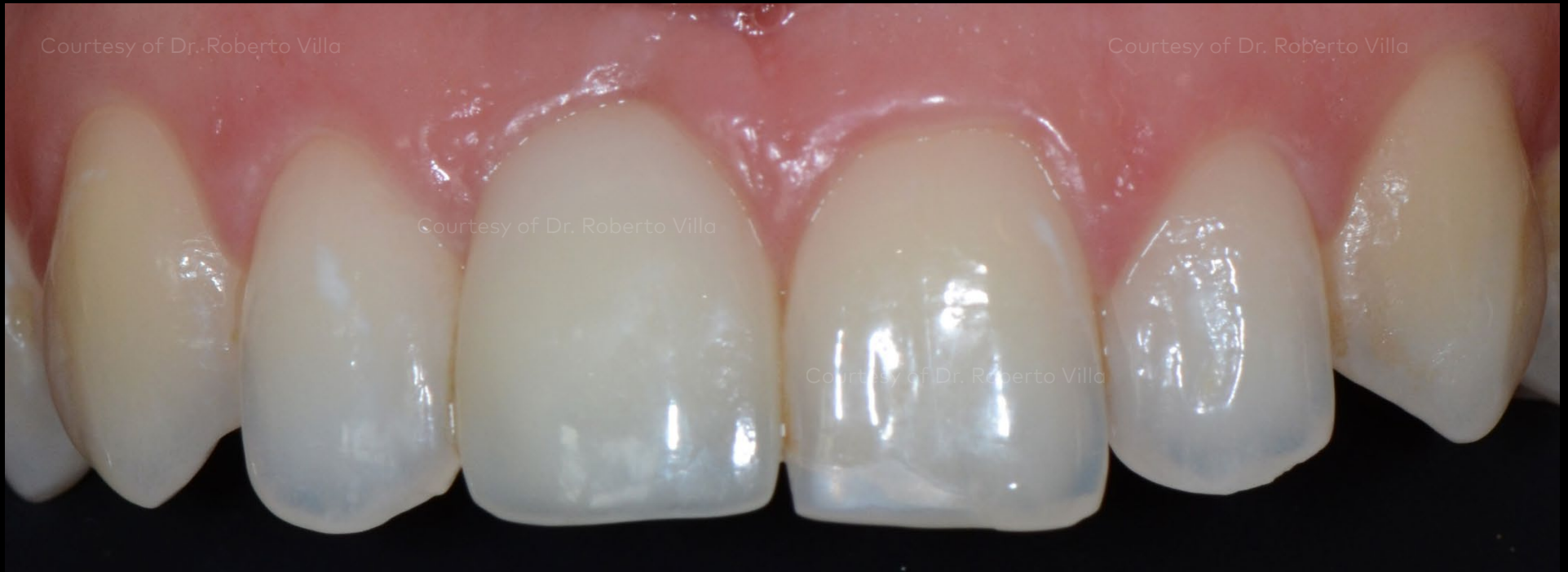X-ray after 5 years of follow-up

Outcome

Initial clinical situation

Surgical procedure

Outcome

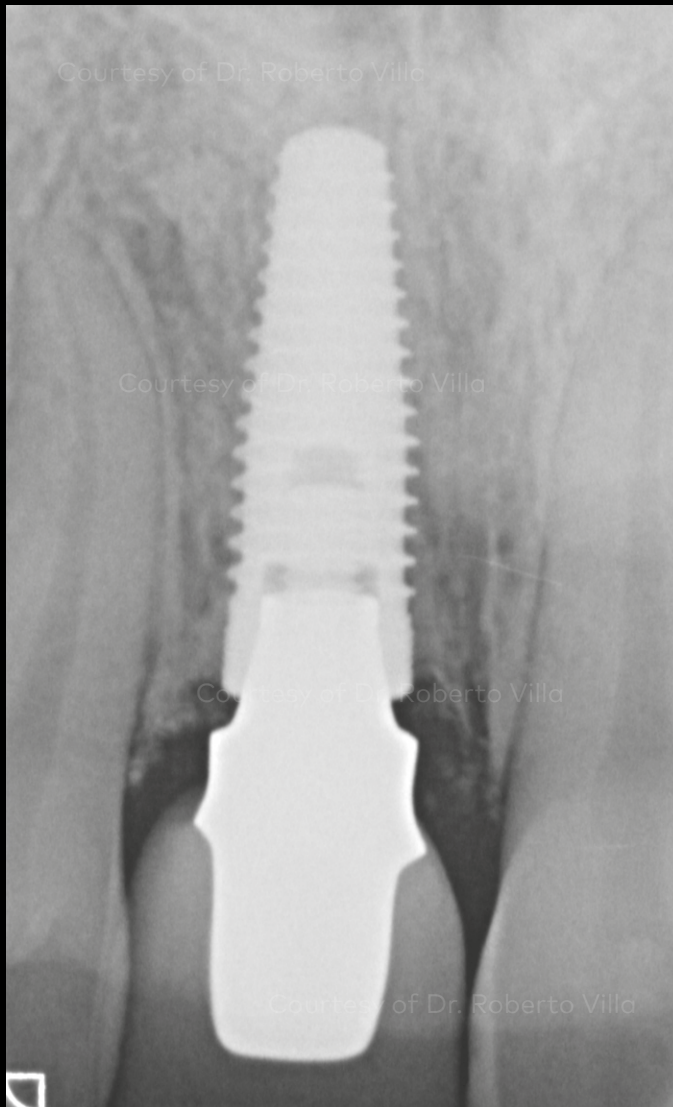


Clinical situation after 7 years of follow-up showing excellent papilla

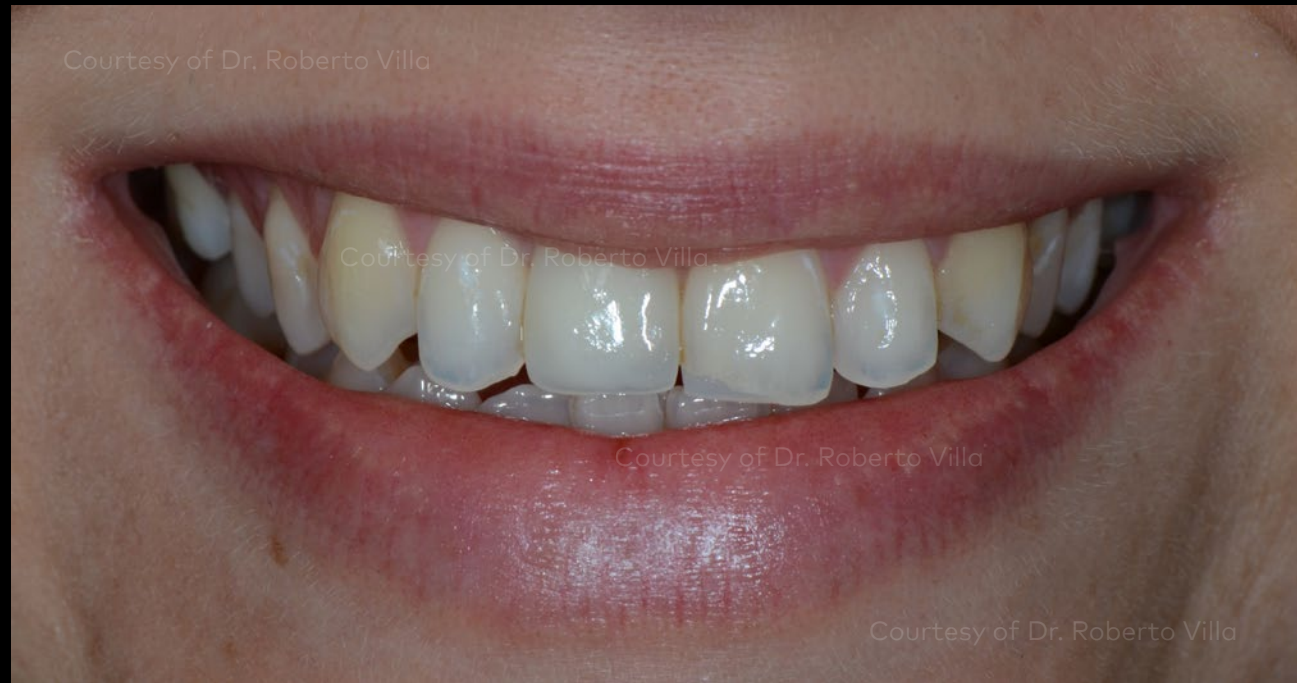Initial clinical situation

Surgical procedure

Outcome



X-ray after 7 years of follow-up showing healthy bone levels



Facial view and smile line after 7 years of follow-up

Case courtesy of Dr. Roberto Villa

