

Restoration of both lateral superior incisors with narrow platform implants

Juan Zufía and
Santiago Dalmau
Spain



Juan Zufia



Santiago Dalmau

Patient

Female patient, 29 years old

Surgical solution

NobelActive® RP 13 mm

Restorative solution

Two NobelActive® ASC Abutments directly veneered (screw-retained crowns).

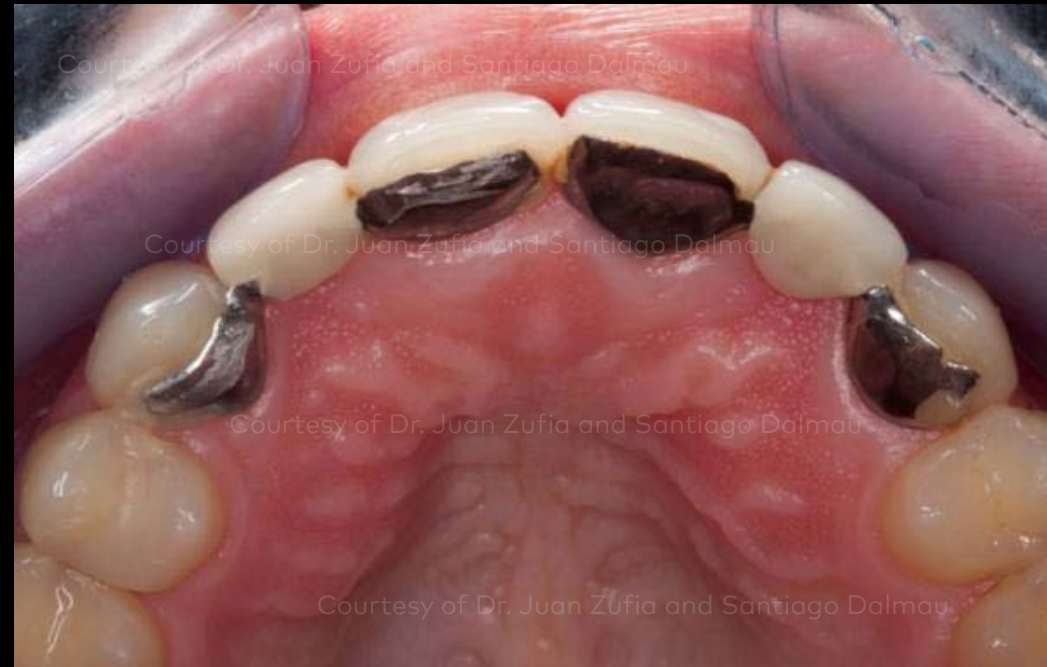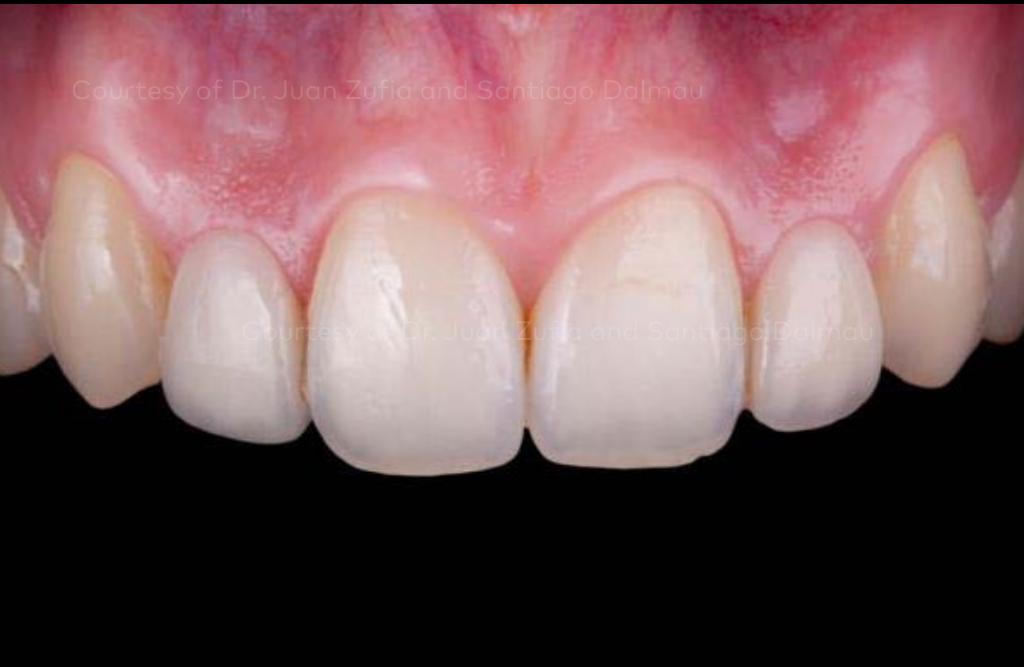Patient presented with congenitally missing lateral incisors, underwent bone and connective tissue grafting and received two narrow platform implants, NobelActive® ASC Abutments, and directly veneered screw-retained crowns.

Initial clinical situation

Surgical procedure

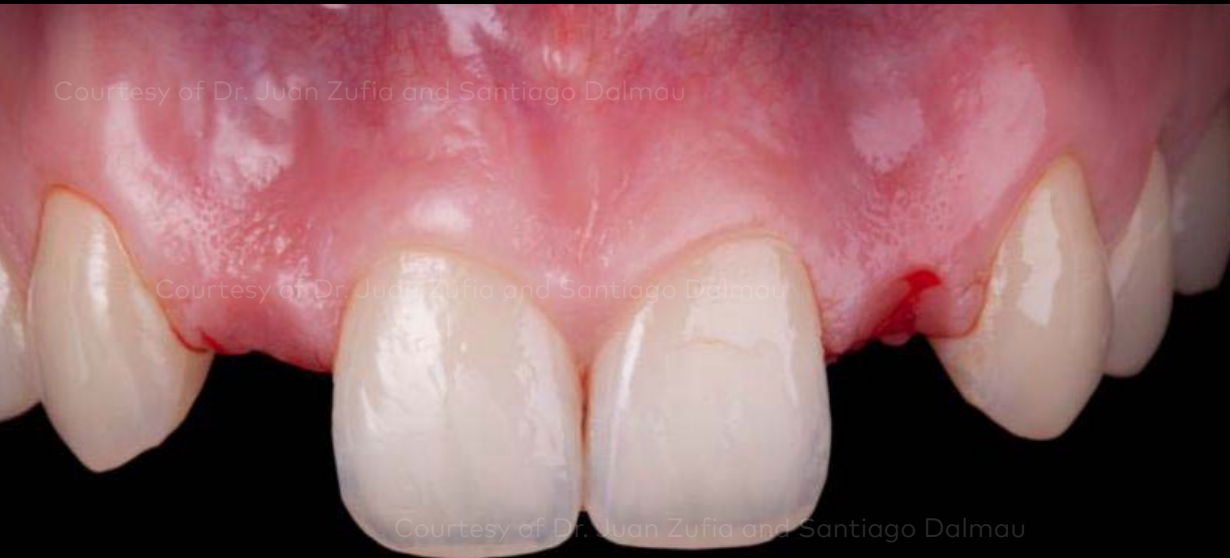Restorative procedure

Outcome

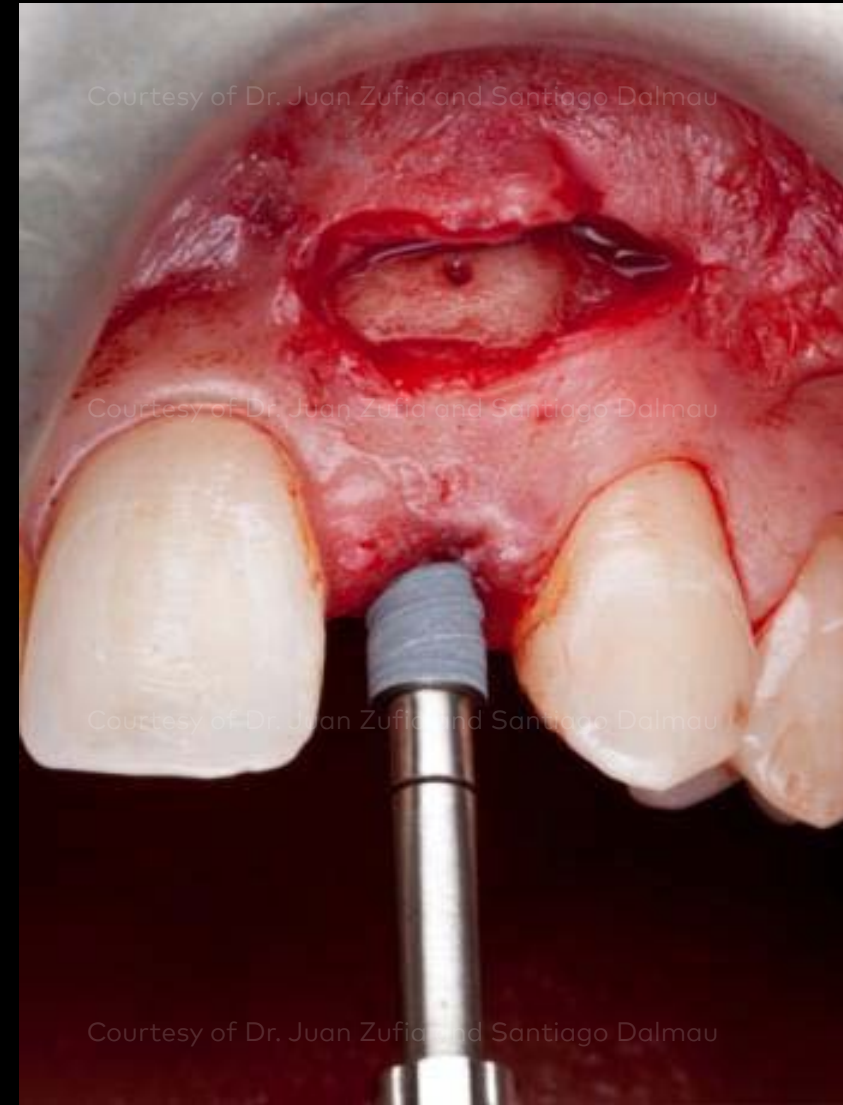


Initial clinical situation shows congenitally missing lateral incisors, deterioration of porcelain bridges and insufficient bone quantity.

Initial clinical situation



Surgical procedure

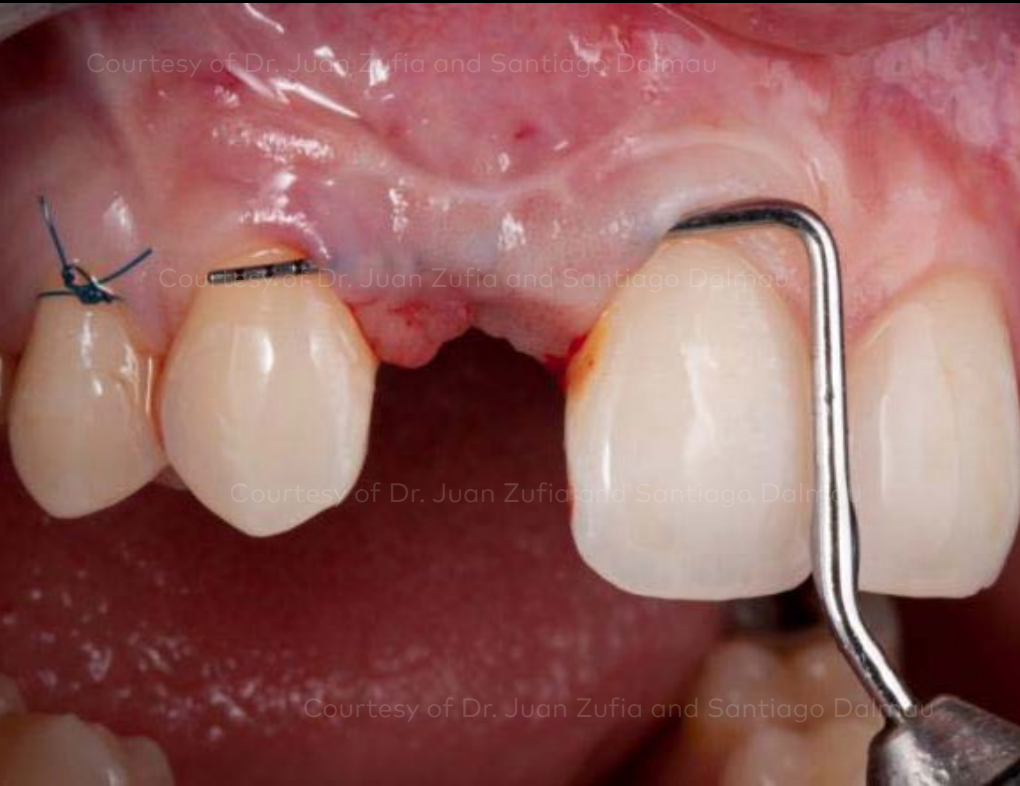

Restorative procedure

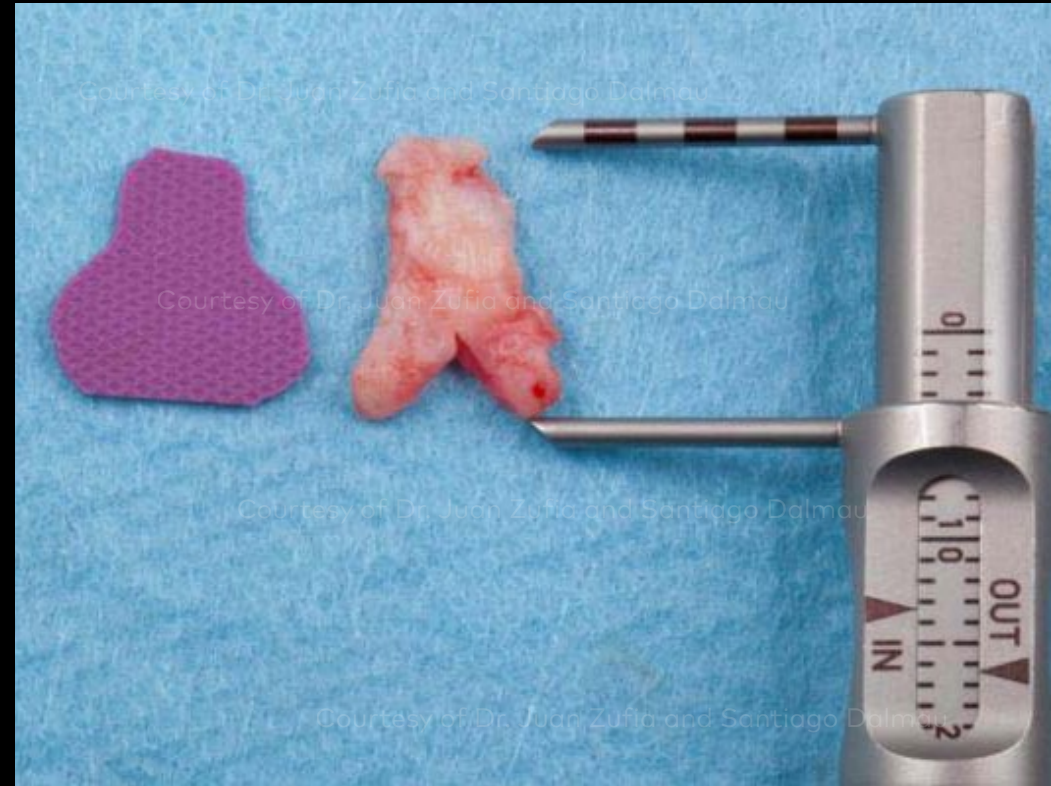Outcome

Removal of the Maryland Bridge (left image). A connective tissue graft was performed to change the biotype from thin to thick. This was followed by three months of healing. Then a guided bone regeneration with two blocks from the mandible ramus was completed, followed by eight months of healing. Two NobelActive® NP implants were placed (right image).

Initial clinical situation



Surgical procedure



Restorative procedure

Outcome

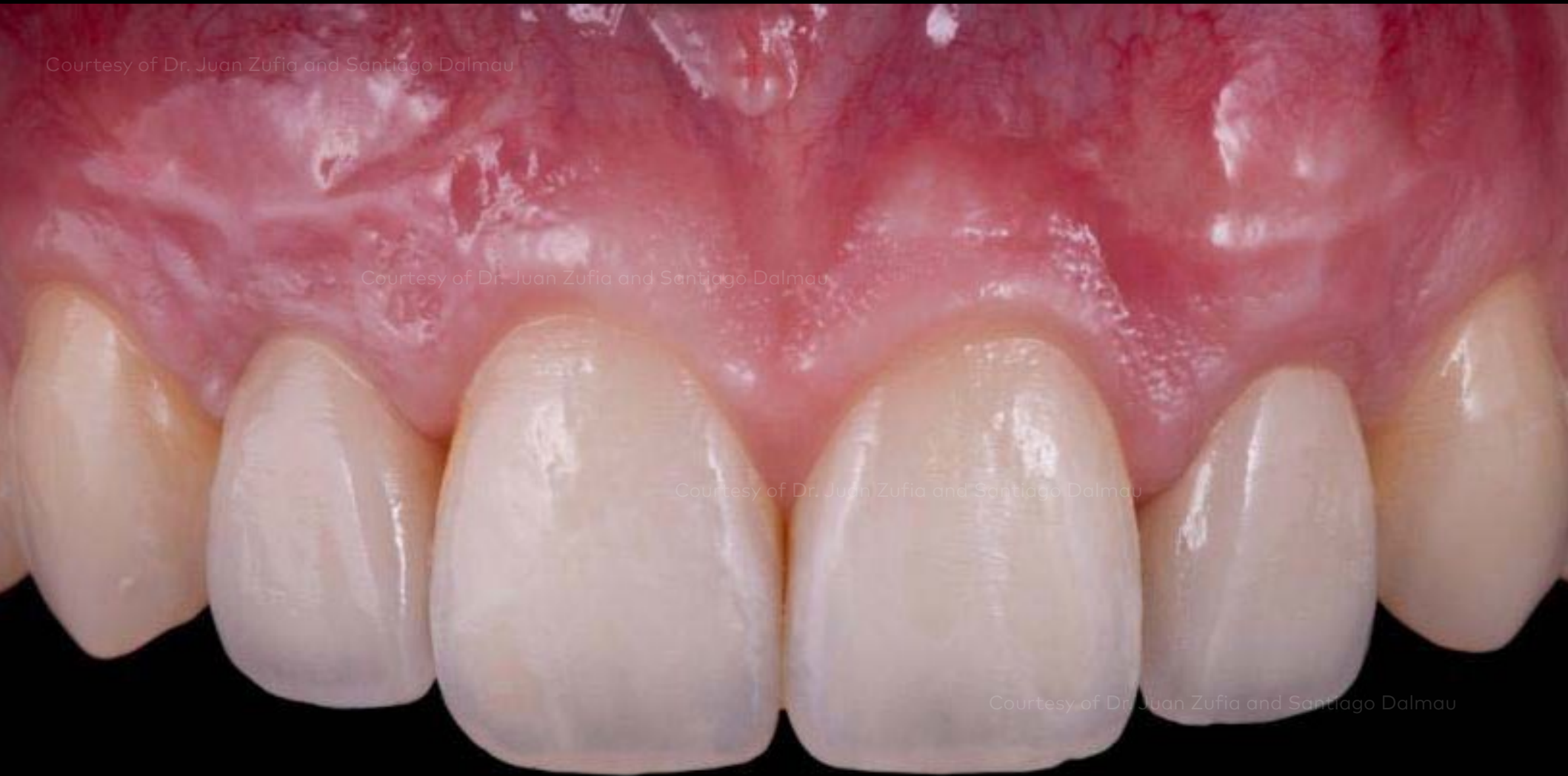A second connective tissue graft was performed to improve the height of the soft tissue.

Initial clinical situation

Surgical procedure

Restorative procedure

Outcome



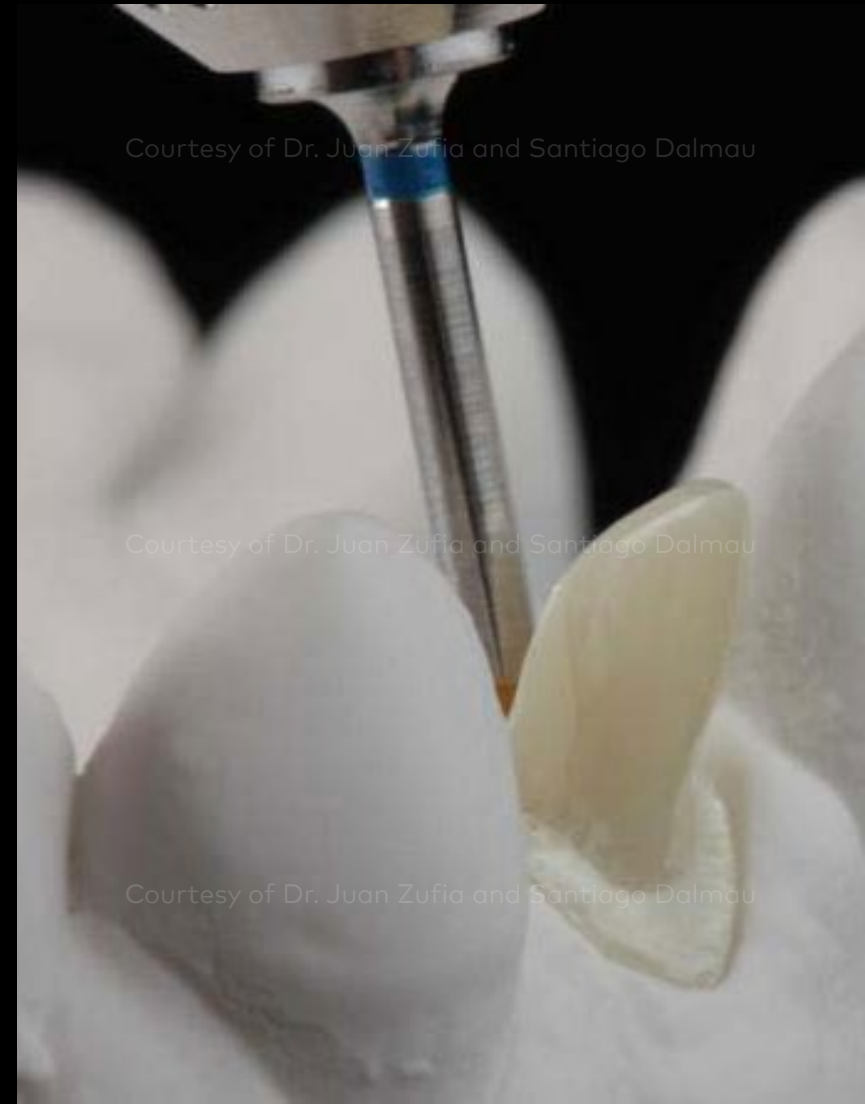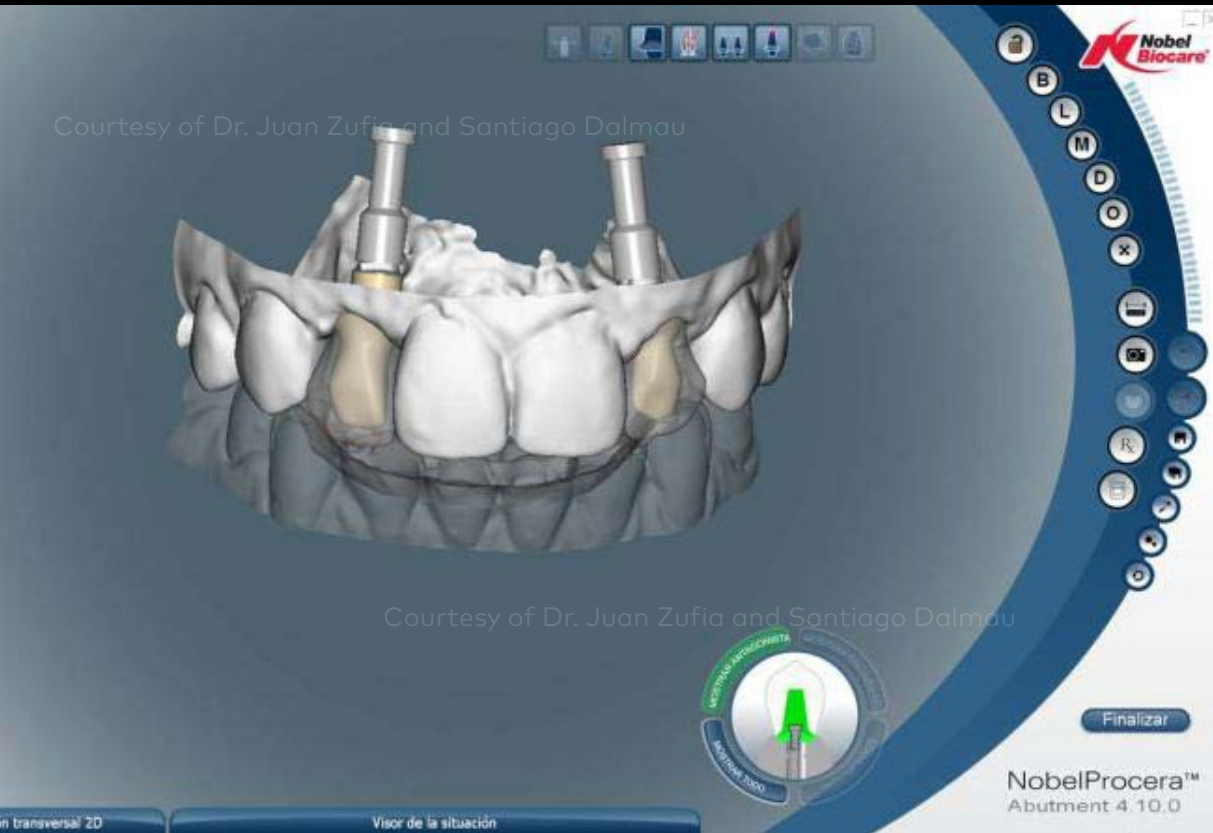Fixed provisional restorations were placed to shape the emergence profile.

Initial clinical situation

Surgical procedure

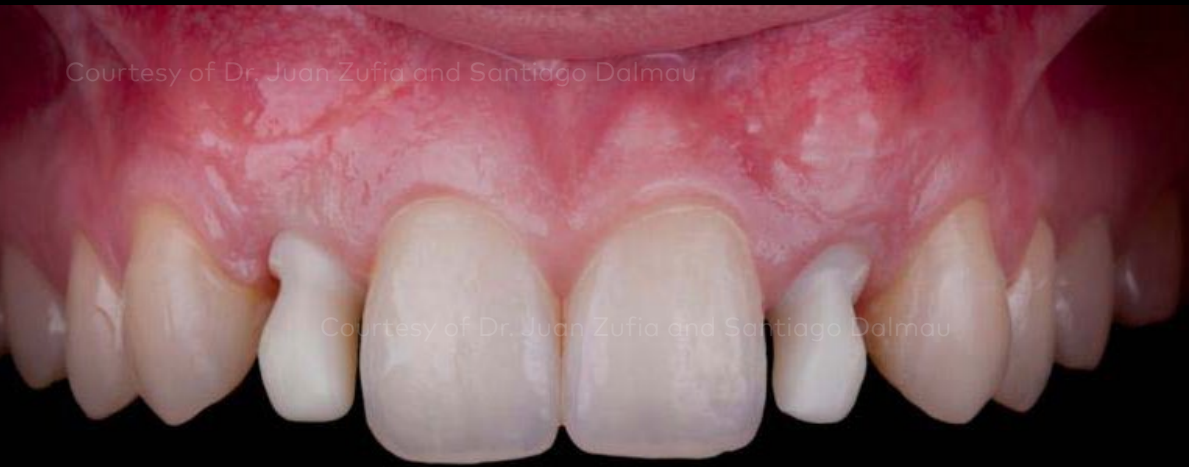Restorative procedure

Outcome



Abutments were designed from a diagnostic tooth set-up to create the ideal anatomical shape for optimal veneering.

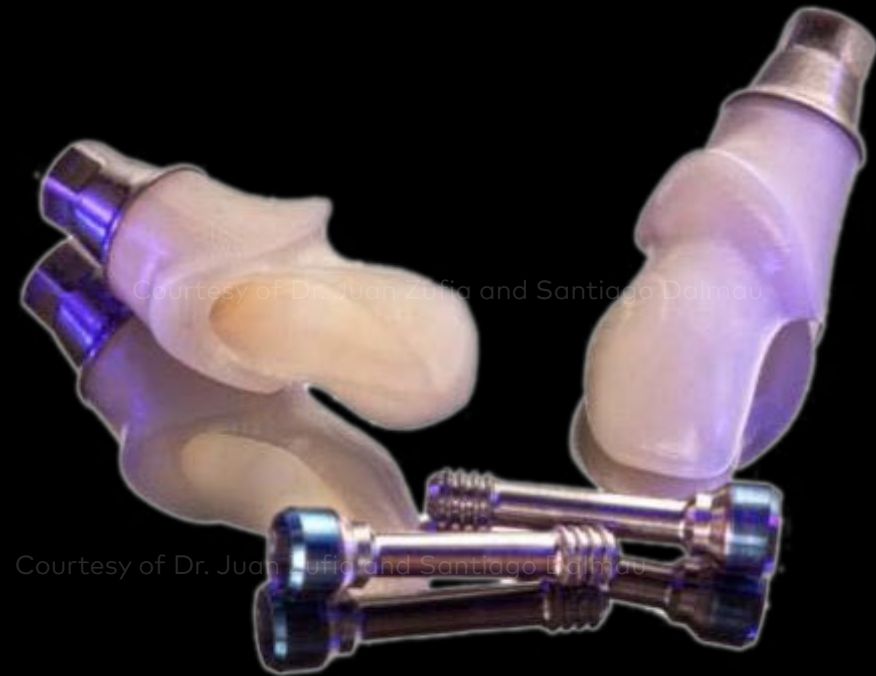Initial clinical situation



Surgical procedure

Restorative procedure

Outcome



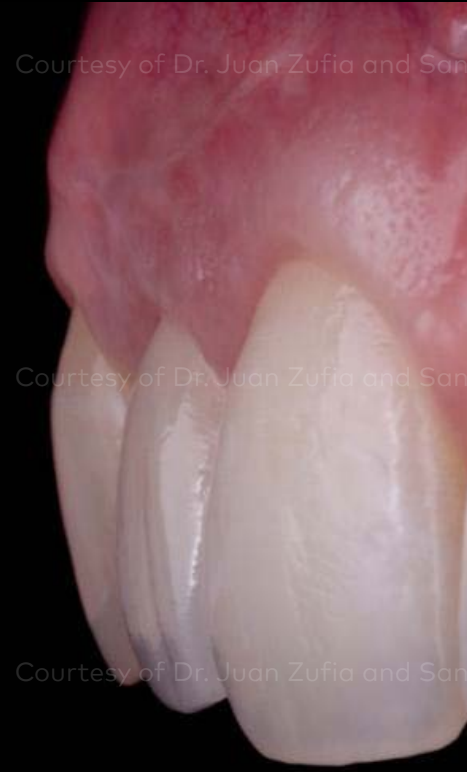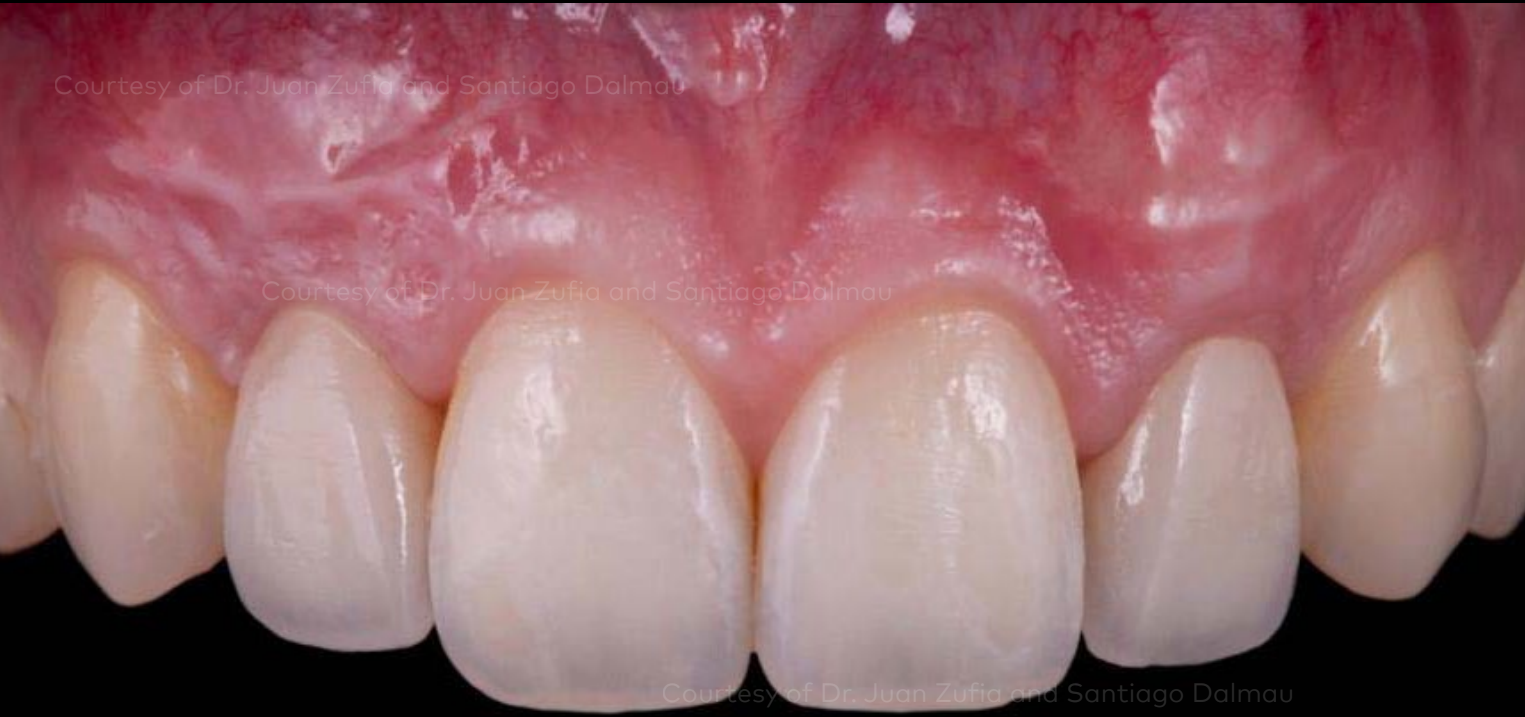Try-in of the two NobelProcera® ASC Abutments. The new Omnigrip™ Screwdriver with pick-up function securely holds the screw.

Initial clinical situation

Surgical procedure

Restorative procedure

Outcome



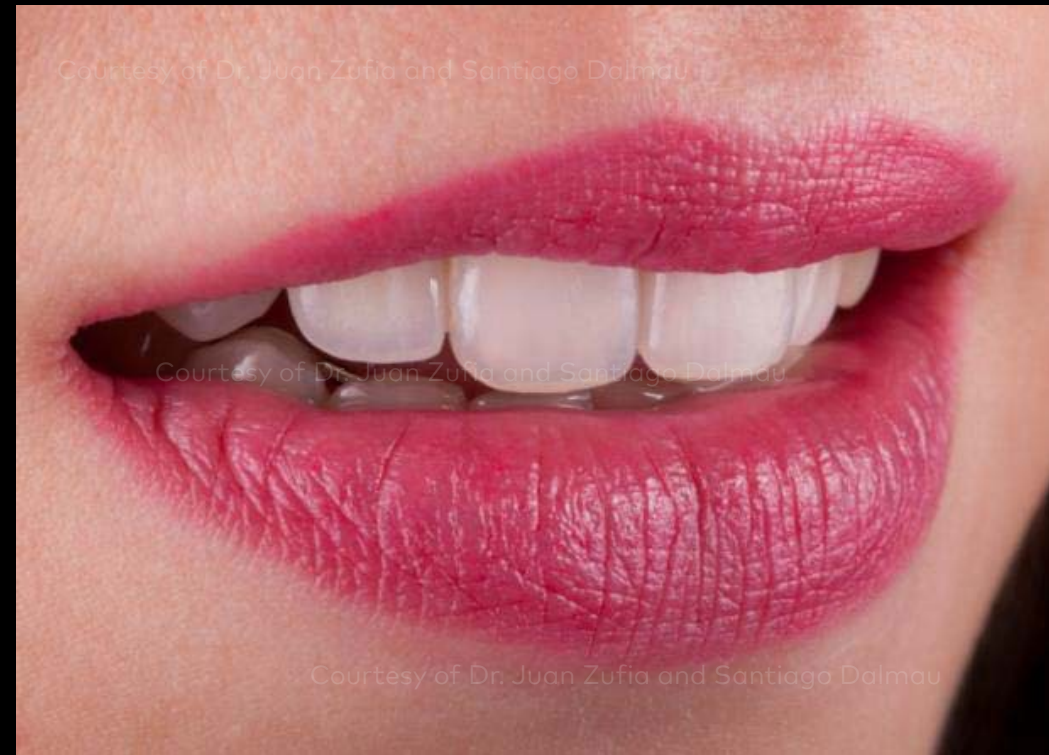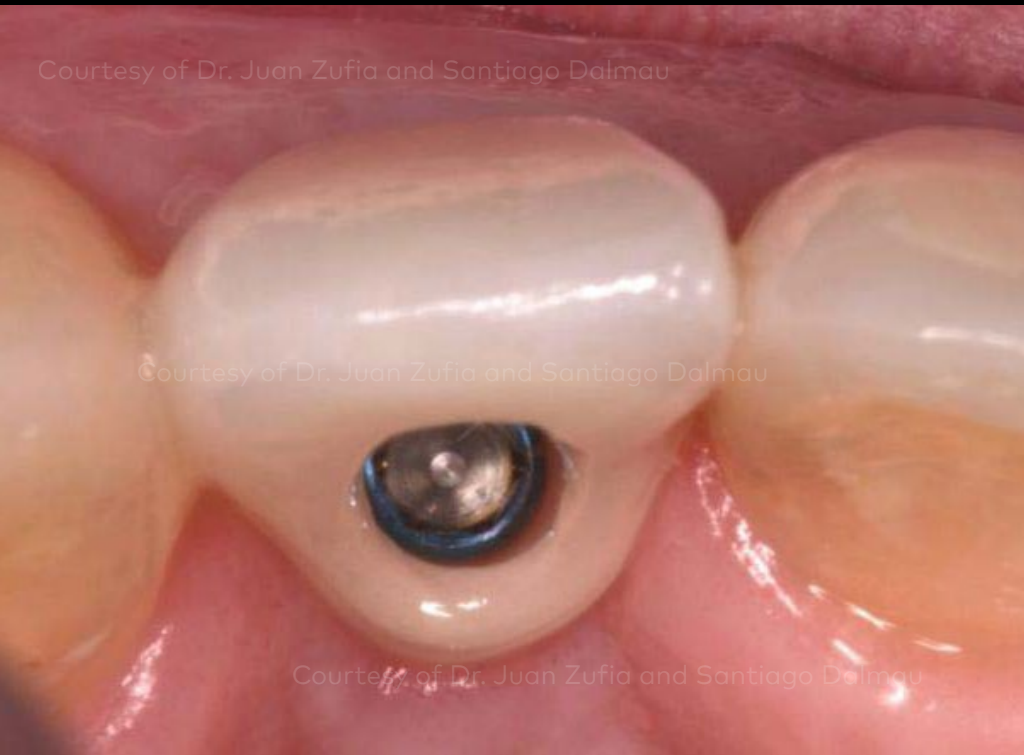Facial and lateral view of the final outcome.

Initial clinical situation

Surgical procedure

Restorative procedure

Outcome



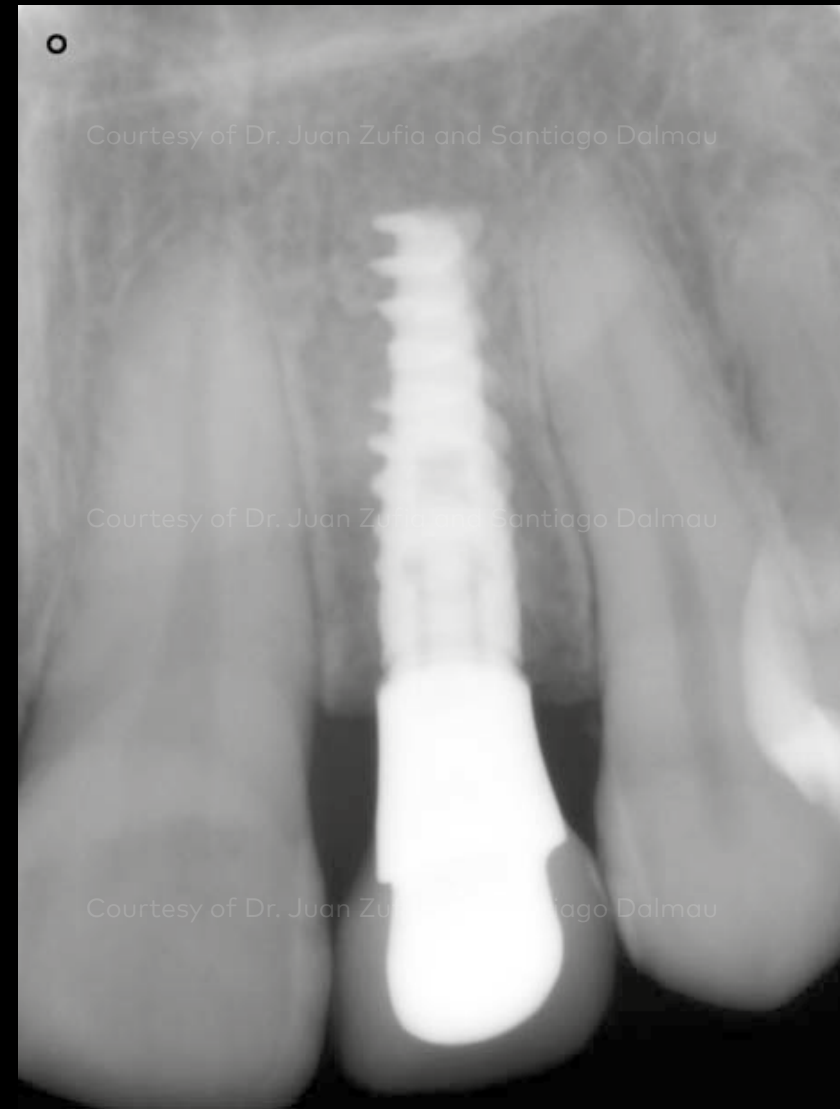
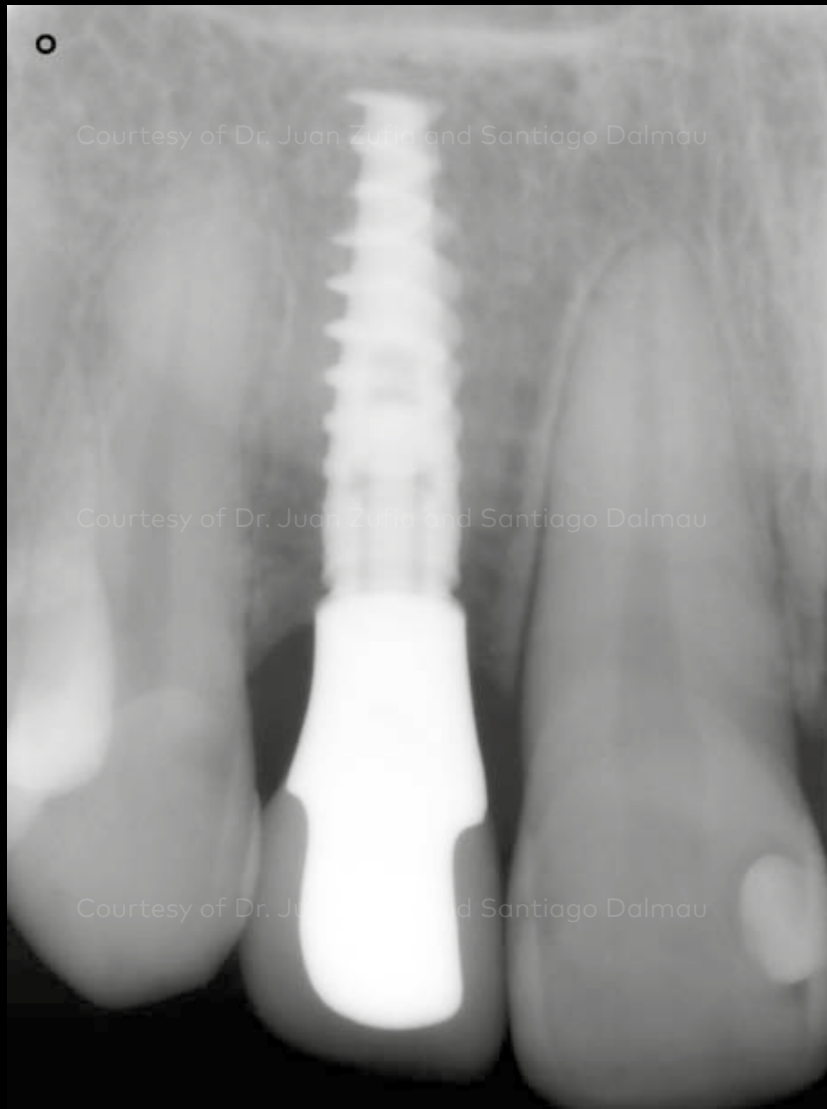
Occlusal view of the final restoration and patient smile.

Initial clinical situation

Surgical procedure

Restorative procedure

Outcome



On the day of ASC restoration placement, post-operative X-rays show the excellent fit of these screw-retained restorations.

Case courtesy of Dr. Juan Zufia and Santiago Dalmau

