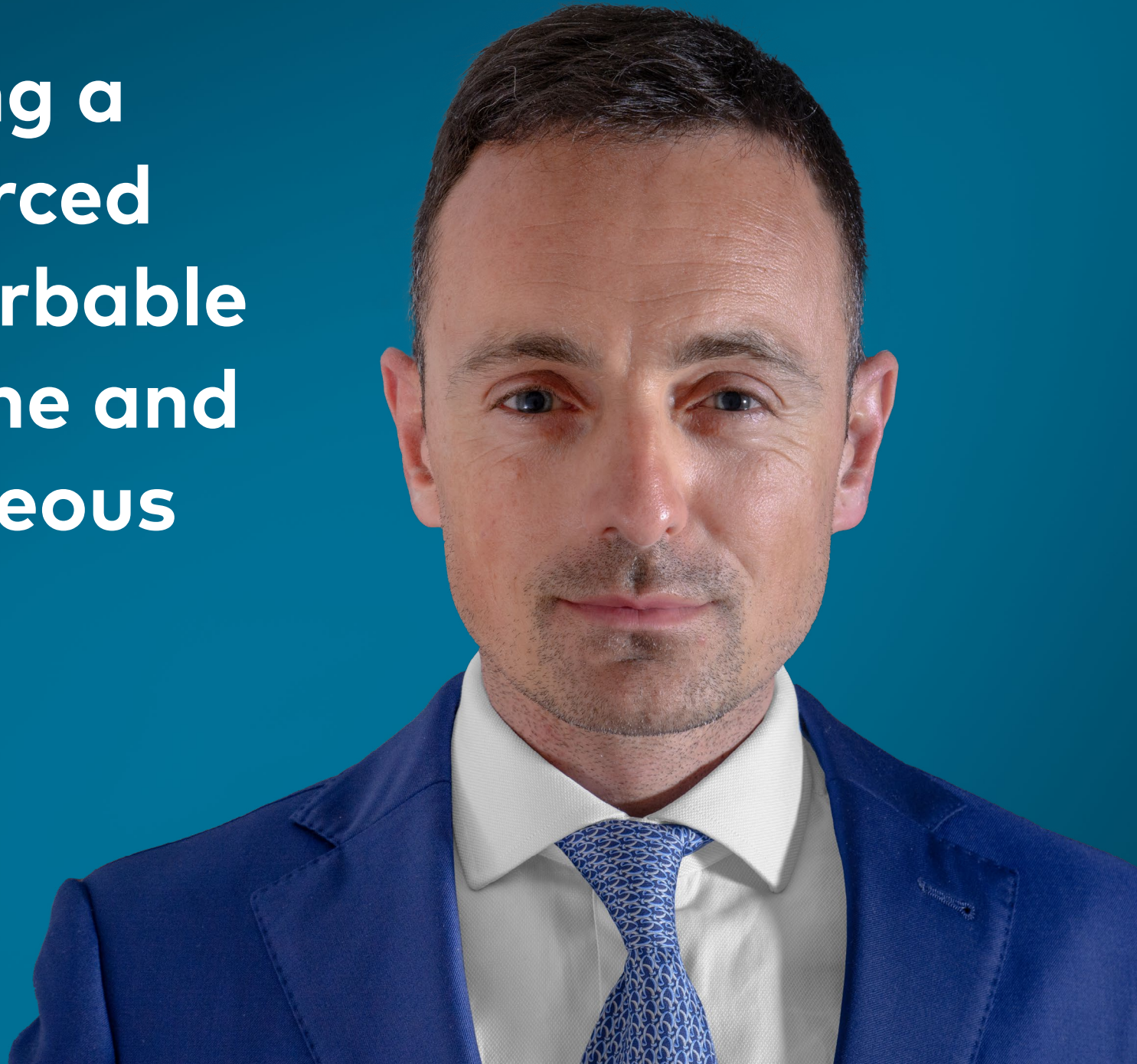

CLINICAL CASE



GBR using a Ti-reinforced non-resorbable membrane and simultaneous sinus lift

Dr. Fabrizio Colombo, DDS





**Dr. Fabrizio
Colombo, DDS**

Patient

62, F, No systemic diseases, no oral pathologies or dental problems other than the existing one.

Clinical situation

Absence of the dental elements from 1.3 to 1.7, horizontal atrophy of the I quadrant and vertical atrophy in the region of 1.4, 1.5, 1.6 and 1.7.

Surgical solution

GBR using creos™ syntoprotect Ti-reinforced PTFE membrane and a mixture of creos xenogain™ and autologous bone to improve the width of the alveolar ridge.

Sinus lift through lateral approach to reach the amount of bone useful to place implant in the posterior area.

Placement of 4 NobelReplace® CC implants after 8 months of healing.

Free gingival graft to get keratinized tissues around the implants.

Restorative solution

Provisional: [Acrylic (PMMA) screw retained temporary crowns.

Final: Metal-ceramic crowns.

Surgery date

October 23, 2018 (GBR/ sinus lift)

July 1, 2019 (implant placement)

October 17, 2019 (soft tissues management)

November 18, 2020 (final prosthesis)

Total treatment time

25 months

Tooth position

13-14-15-16



Initial clinical situation

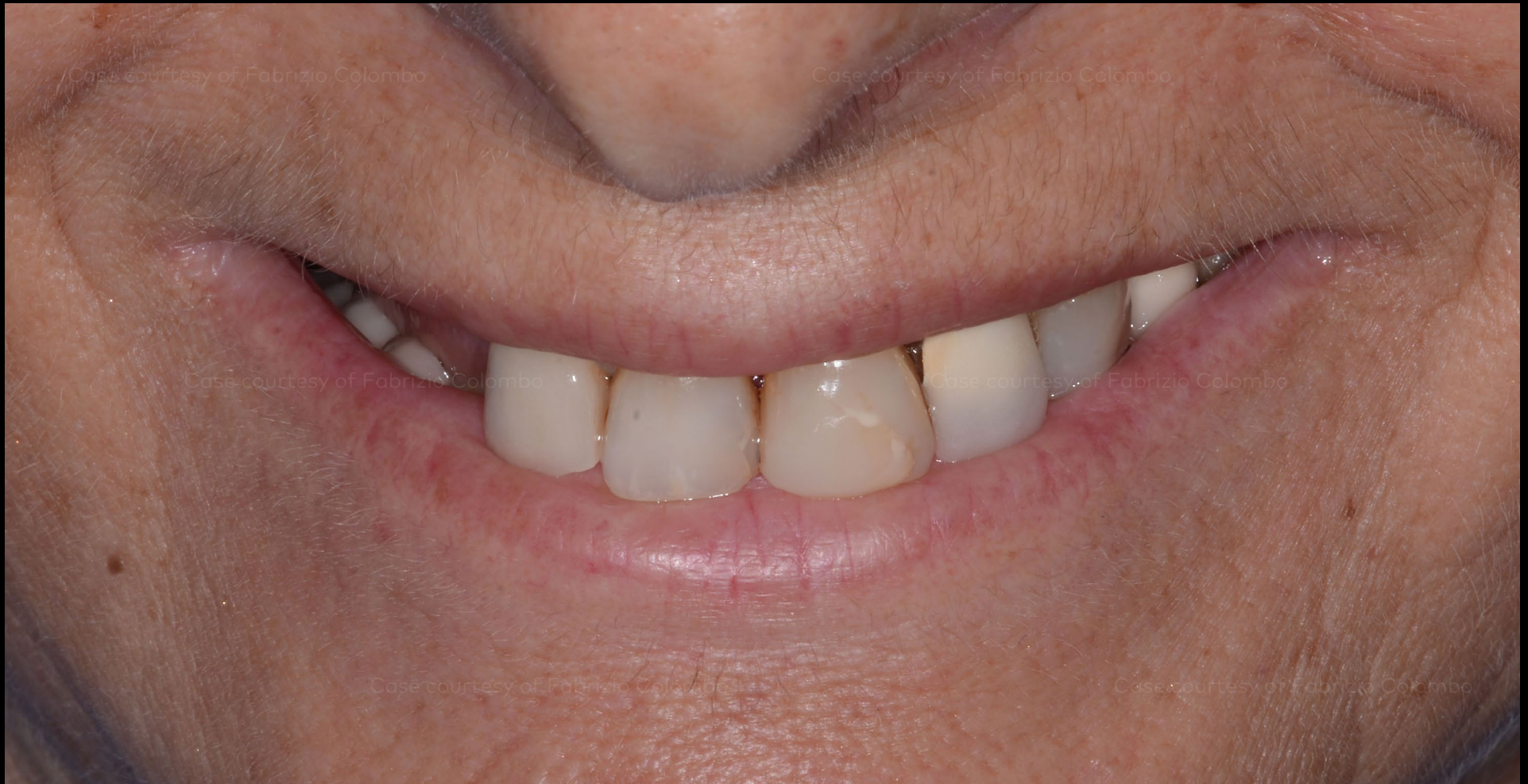Treatment planning

Surgical procedure

Restorative procedure

Outcome

GBR and sinus lift surgery



Extra-oral view: No gummy smile; slight asymmetry during spontaneous smile

Initial clinical situation

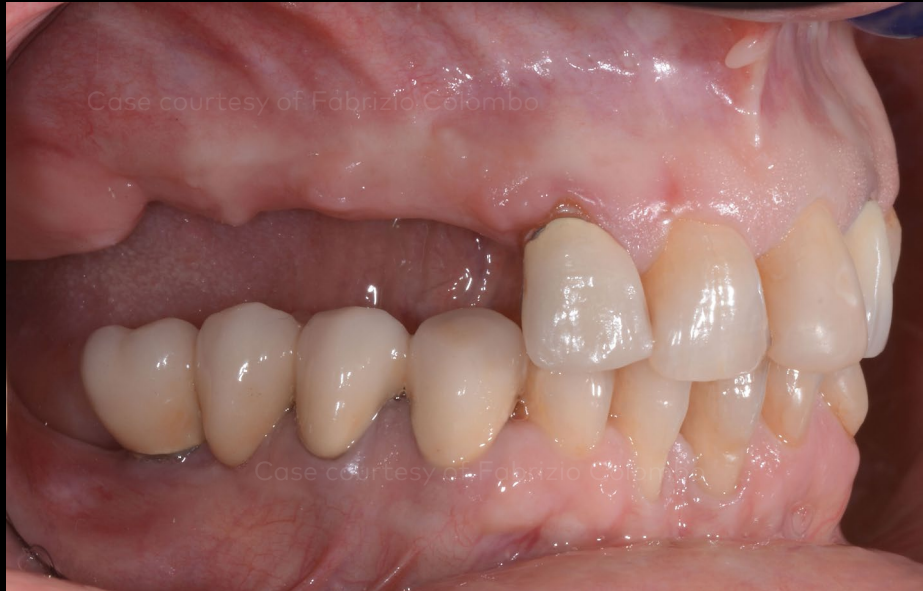Treatment planning

Surgical procedure

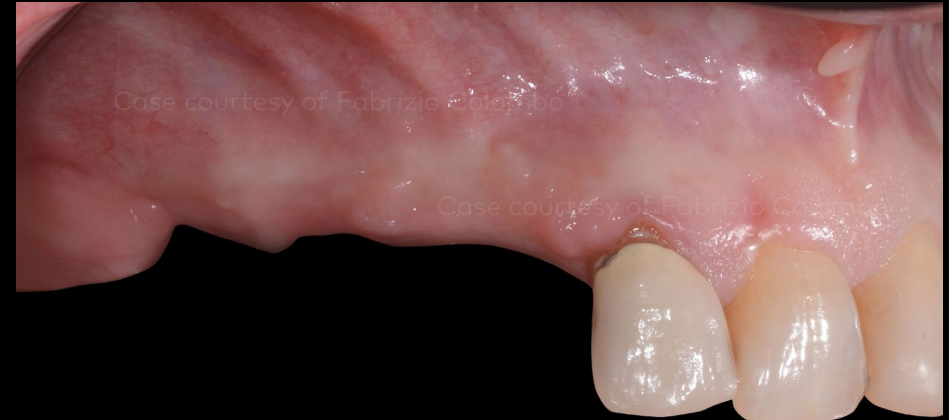Restorative procedure

Outcome

GBR and sinus lift surgery



Intraoral lateral view



Detail of the atrophy

Initial clinical situation

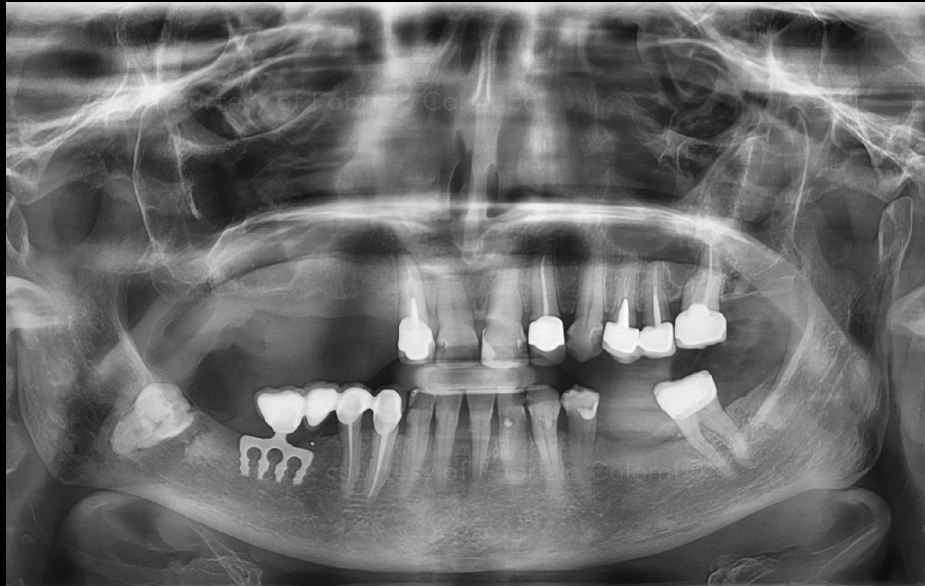
Treatment planning

Surgical procedure

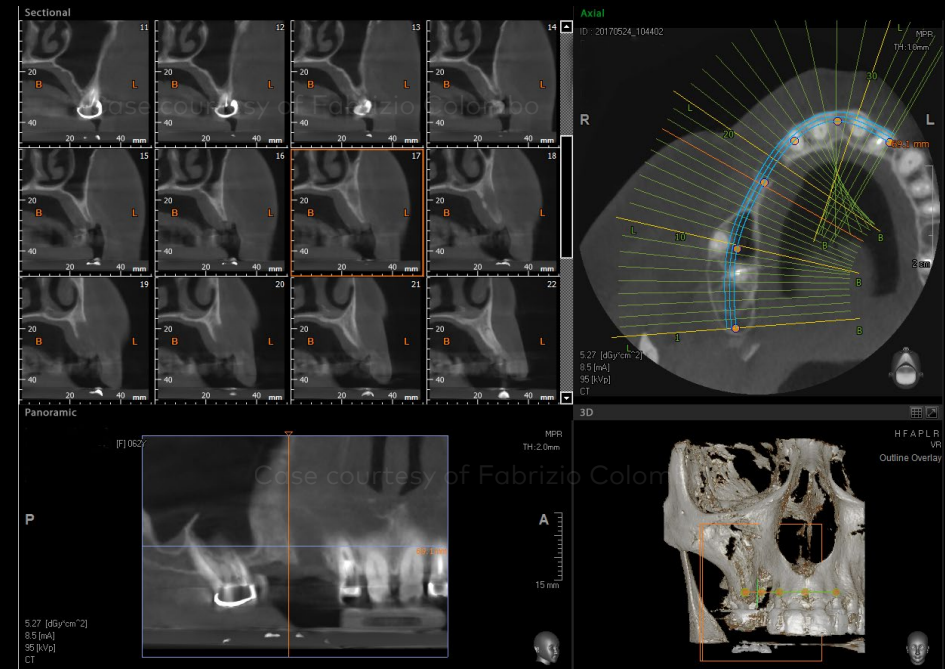
Restorative procedure

Outcome

GBR and sinus lift surgery



Presurgical OPG



CBCT showing horizontal atrophy of the alveolar ridge and pneumatization of the right maxillary sinus

Initial clinical situation

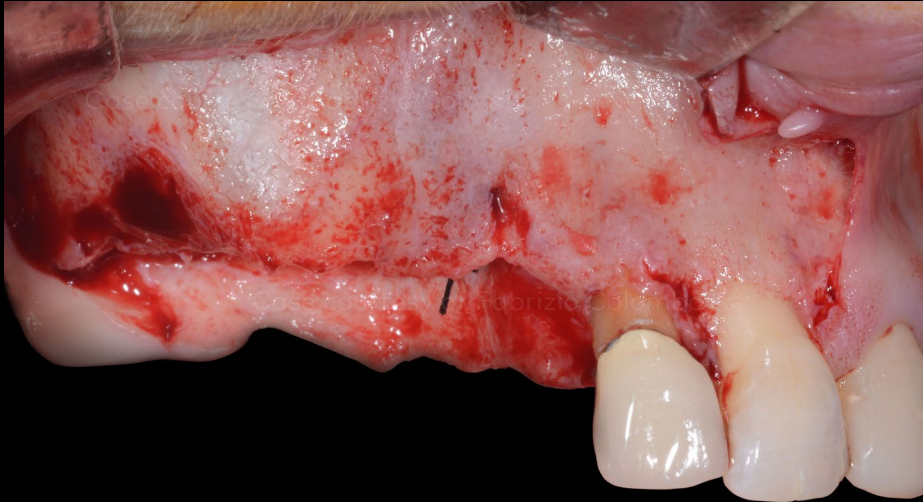
Treatment planning

Surgical procedure

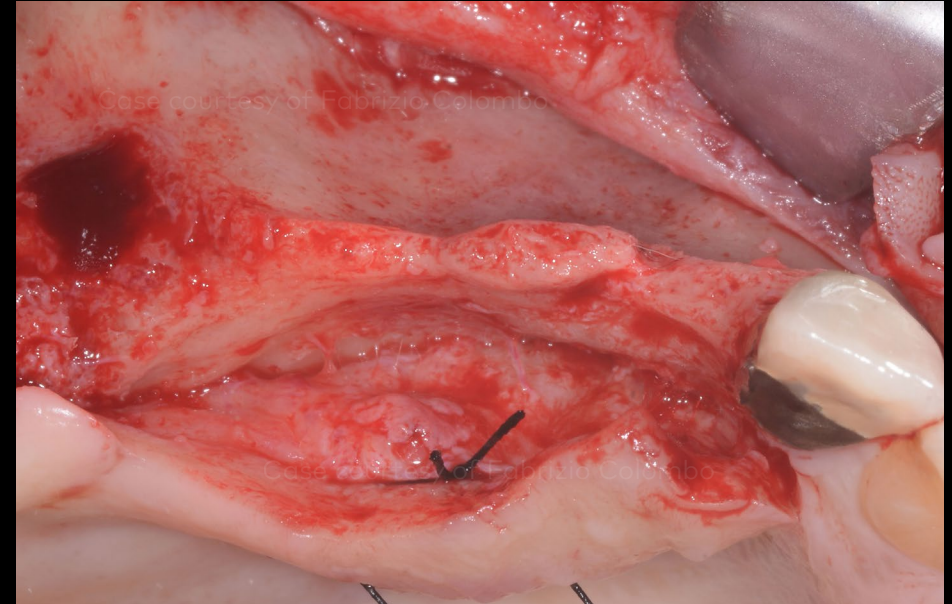
Restorative procedure

Outcome

GBR and sinus lift surgery



Opening of a full-thickness trapezoidal flap



Occlusal view of the horizontal atrophy

Initial clinical situation

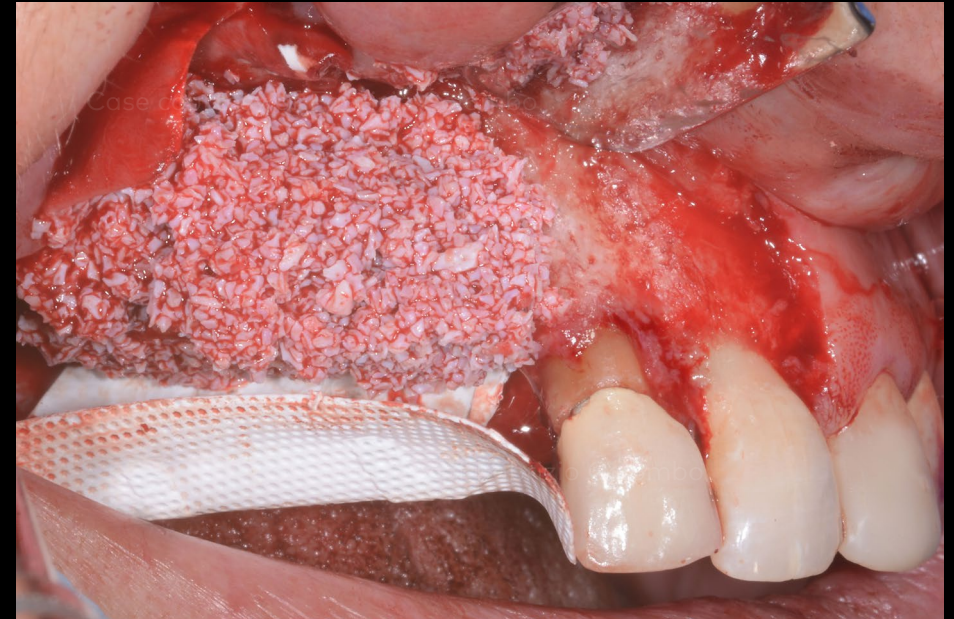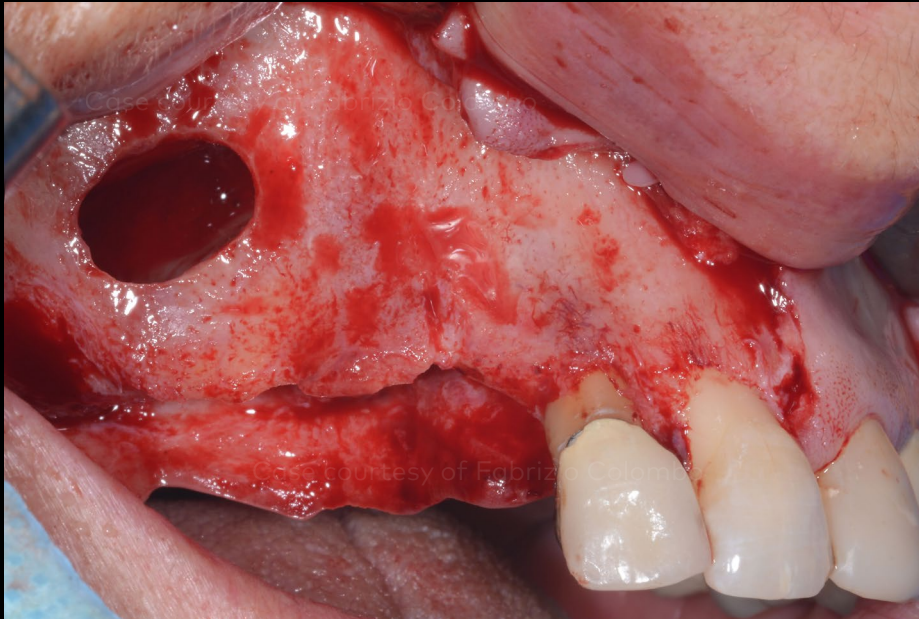
Treatment planning

Surgical procedure

Restorative procedure

Outcome

GBR and sinus lift surgery



Antrostomy

Ti-reinforced non-resorbable PTFE membrane (creos™ syntoprotect) already fixed on the palatal wall and grafting material in situ (mix of 50% autologous bone and 50% creos™ xenogain). At the top left of the picture the collagen membrane (creos™ xenoprotect) is placed to protect the Schneiderian membrane.

Initial clinical situation

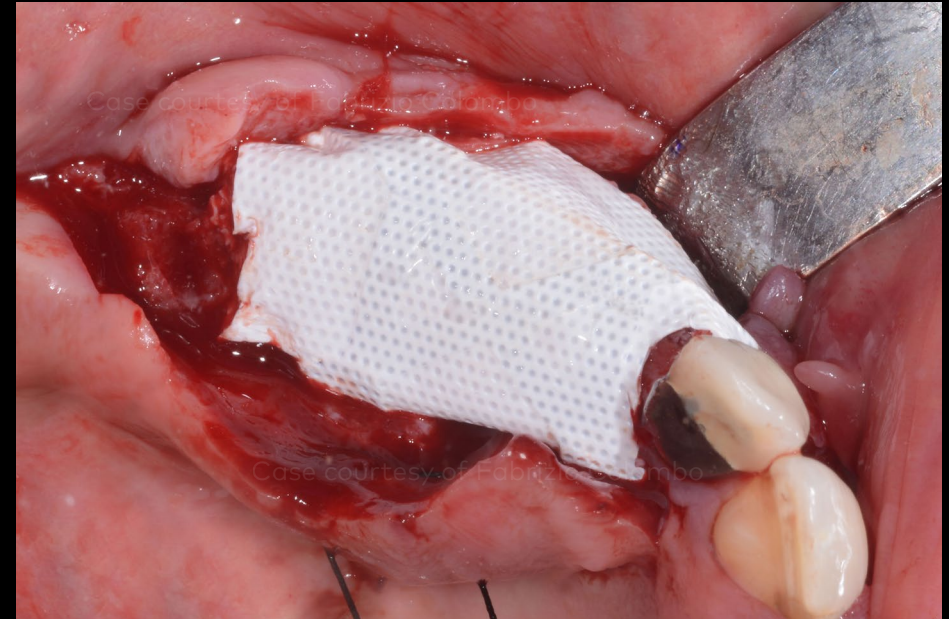
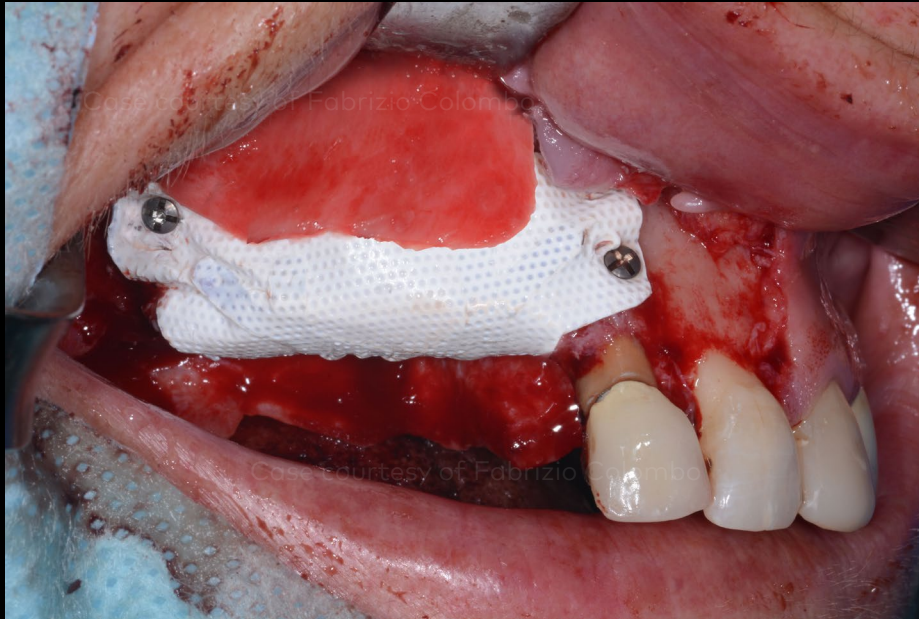Treatment planning

Surgical procedure

Restorative procedure

Outcome

GBR and sinus lift surgery



Resorbable and non-resorbable membranes in place. The Ti-reinforced non-resorbable PTFE membrane was fixed using self tapping screws

Occlusal detail of the membrane before closure of the wound

Initial clinical
situation

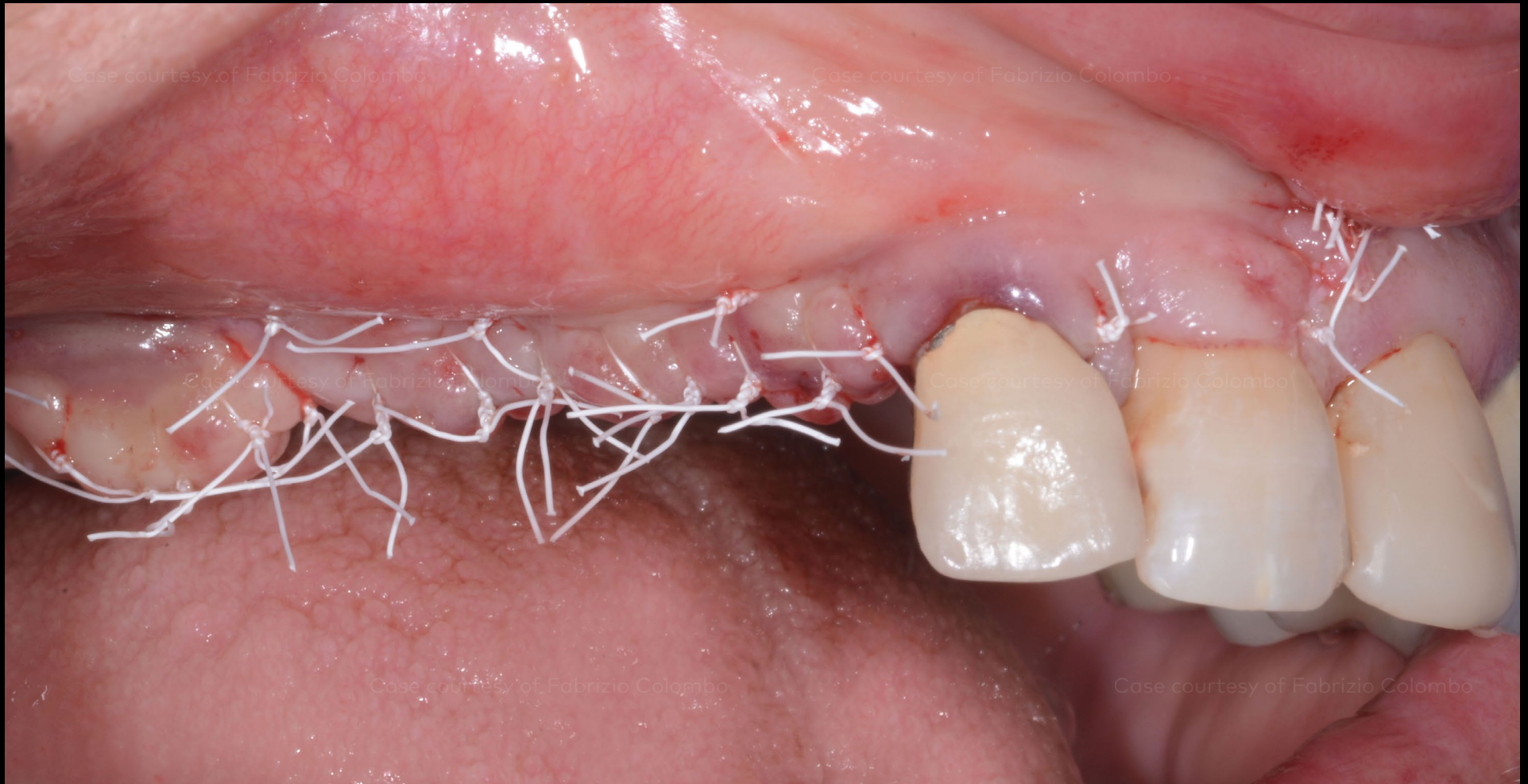Treatment
planning

Surgical
procedure

Restorative
procedure

Outcome

GBR and sinus lift surgery



Detail of the wound closed by primary intention

Initial clinical situation

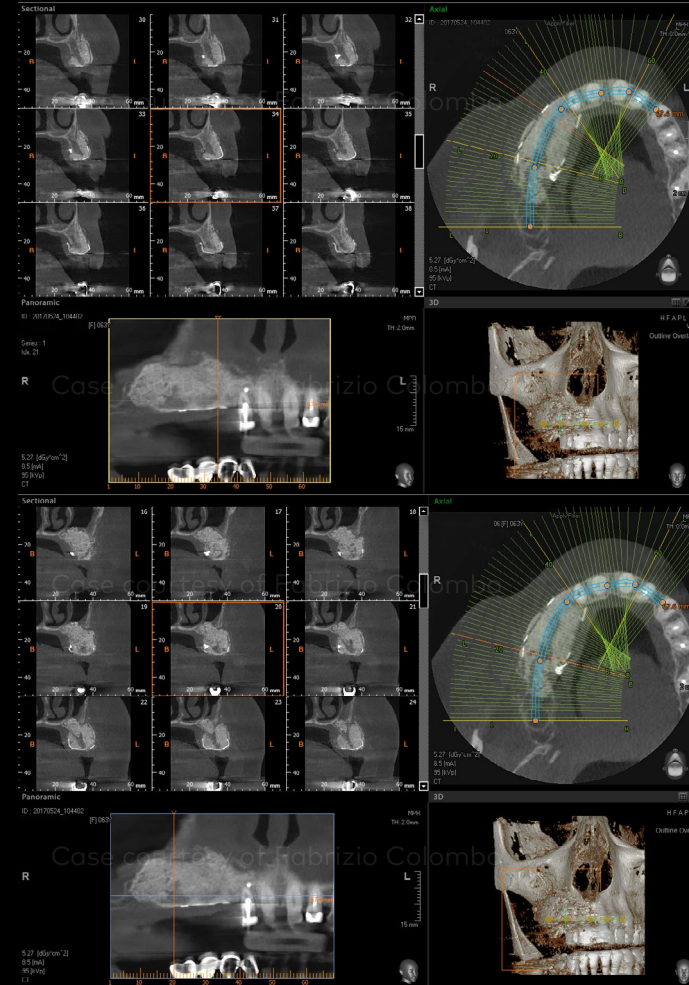
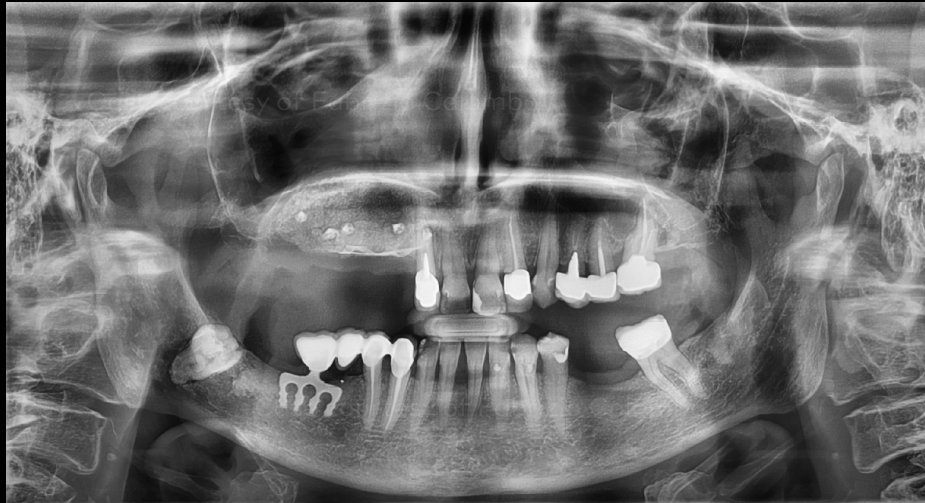Treatment planning

Surgical procedure

Restorative procedure

Outcome

GBR and sinus lift surgery



OPG immediatly after the surgery

CBCT after 8 months healing

Initial clinical situation

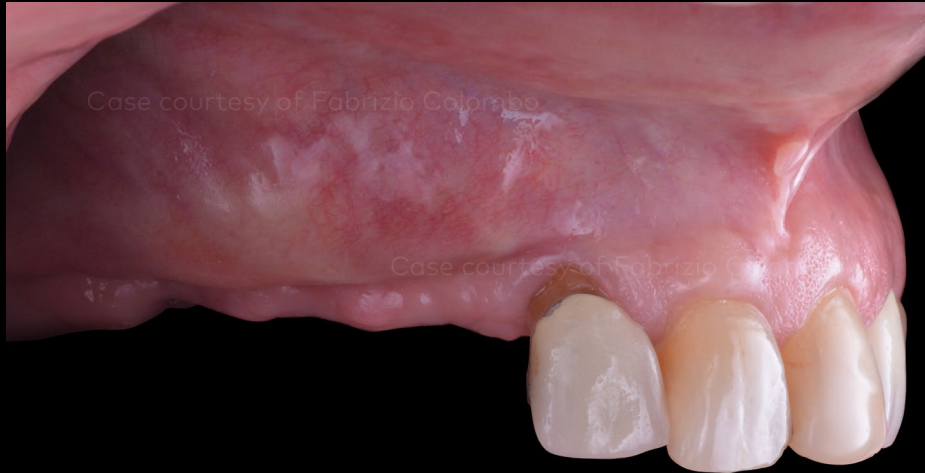Treatment planning

Surgical procedure

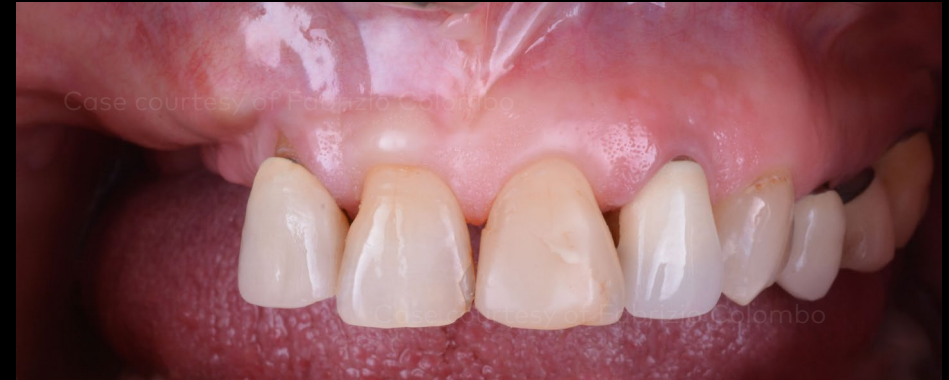Restorative procedure

Outcome

Implant placement



Clinical picture after 8 months of healing (lateral view)



Clinical picture after 8 months of healing (frontal view)

Initial clinical situation

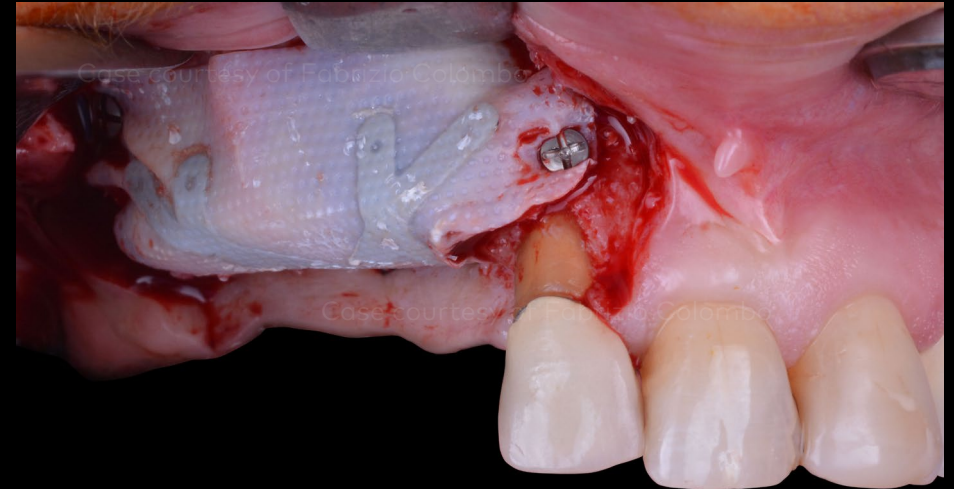
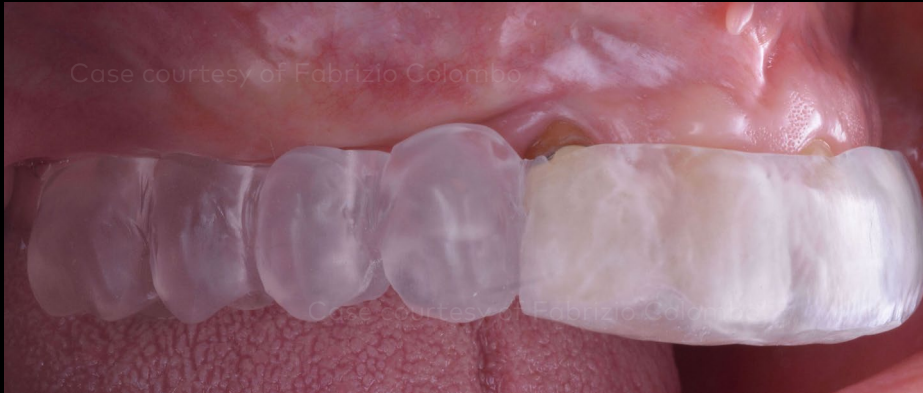Treatment planning

Surgical procedure

Restorative procedure

Outcome

Implant placement



Surgical guide in place

Reopening

Initial clinical situation

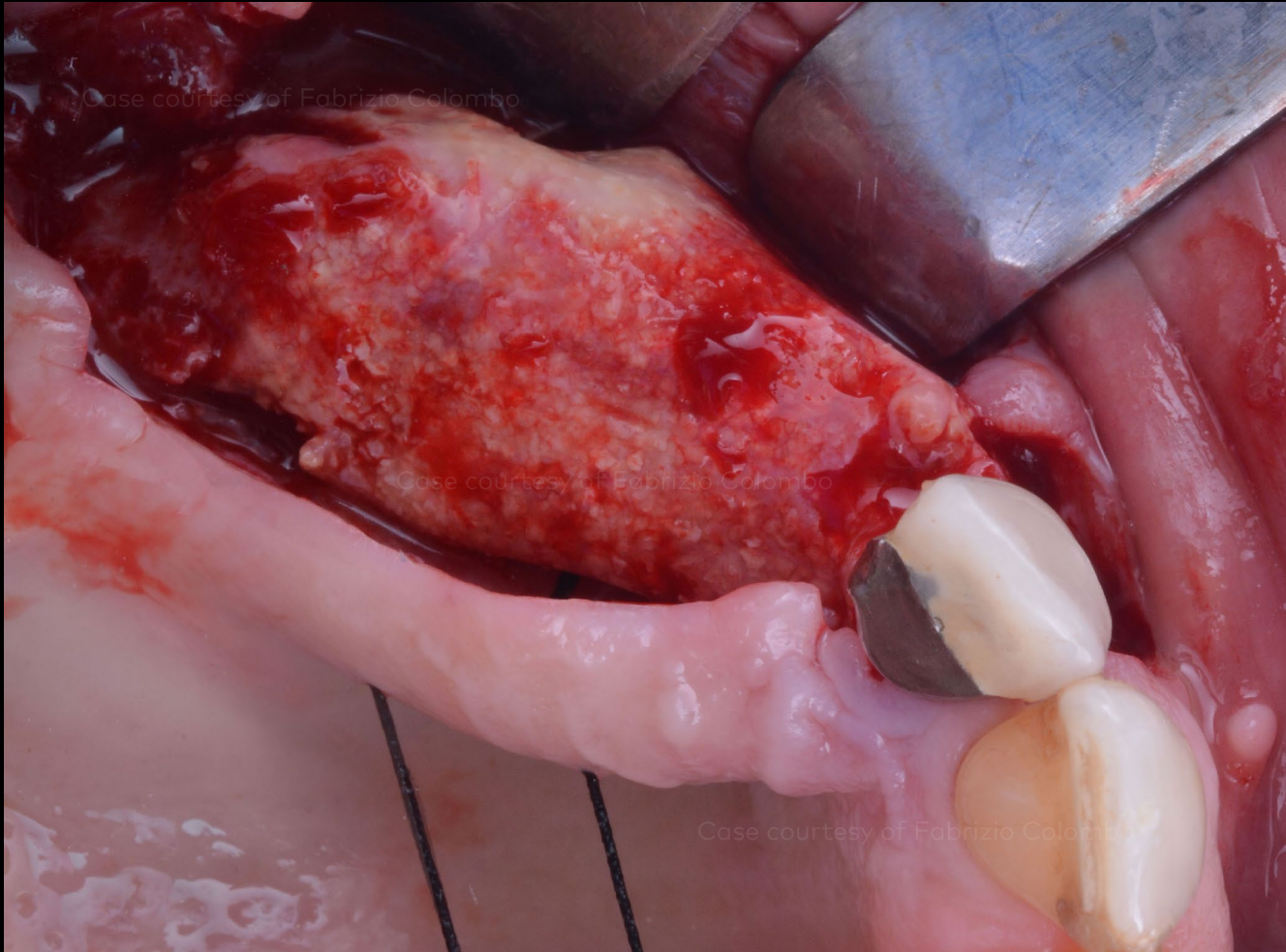
Treatment planning

Surgical procedure

Restorative procedure

Outcome

Implant placement



Detail of the regenerated bone (occlusal view)

Initial clinical situation

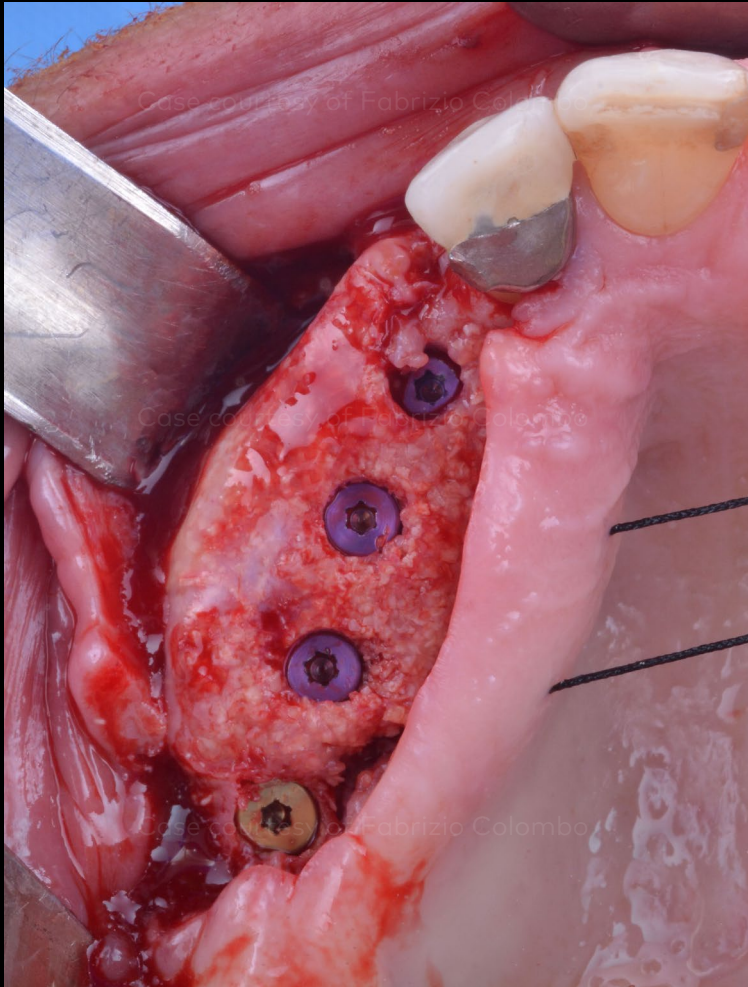
Treatment planning

Surgical procedure

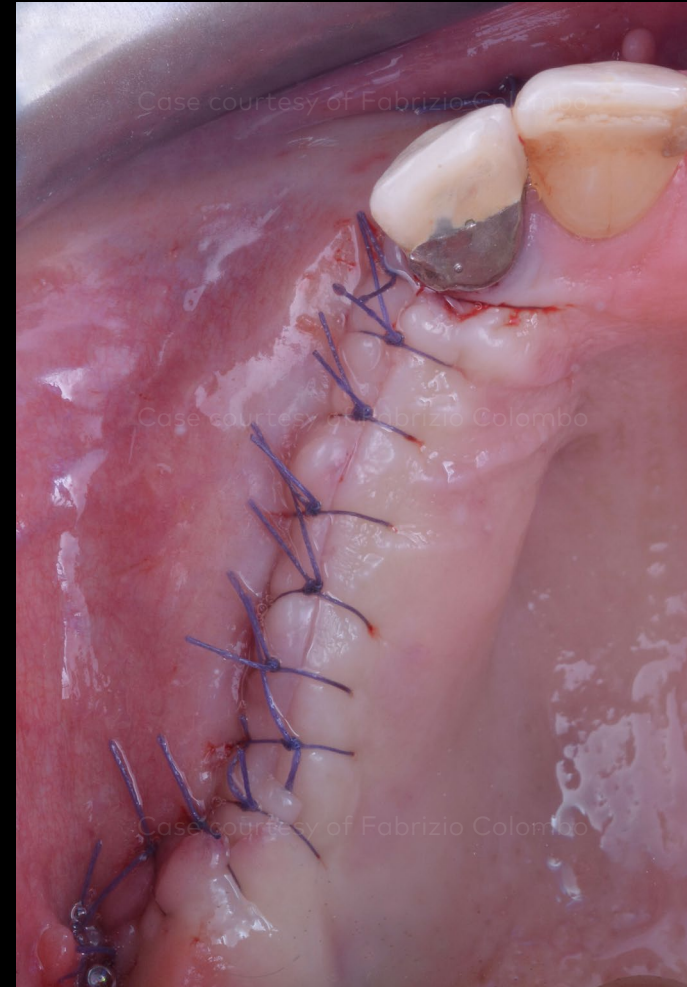
Restorative procedure

Outcome

Implant placement



Four NobelReplace® CC implants in place. The ones in position 13-14-15 are sizing 3.5x13 mm, the distal one is a 4.3x11.5 mm



Closure of the wound by primary intention

Initial clinical situation

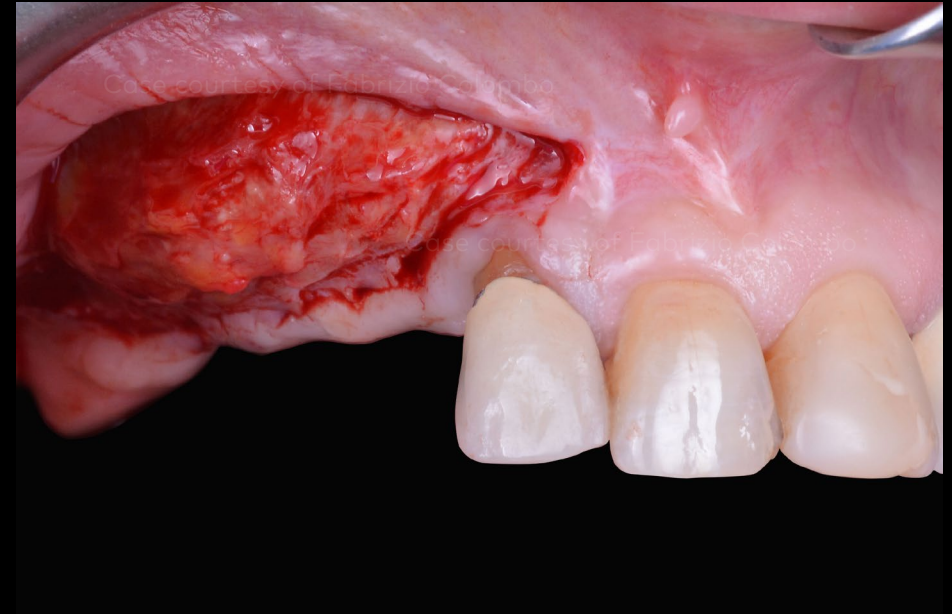
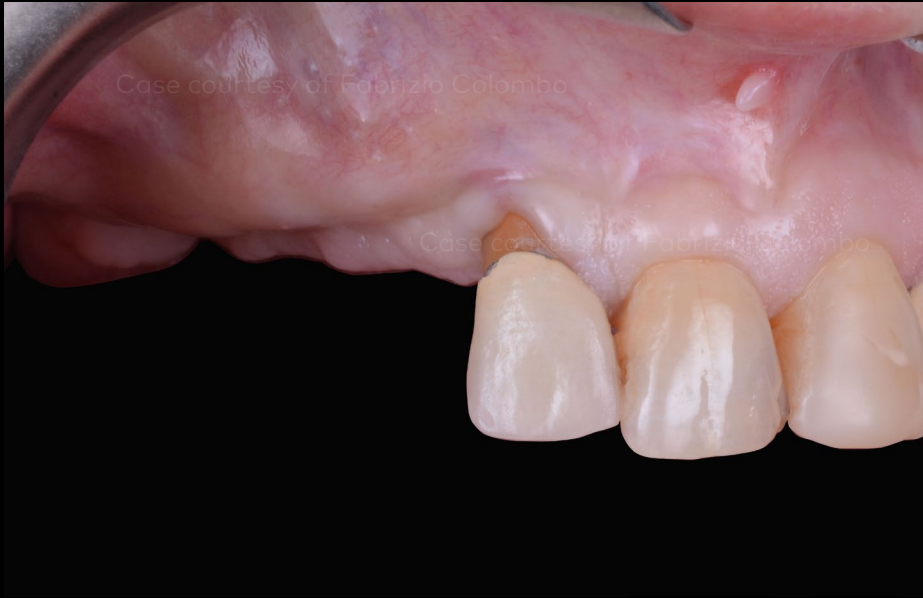Treatment planning

Surgical procedure

Restorative procedure

Outcome

Soft tissue management (FGG)



Clinical picture after further 4 months of healing
(12 months since start of GBR)

Opening a partial-thickness flap

Initial clinical situation

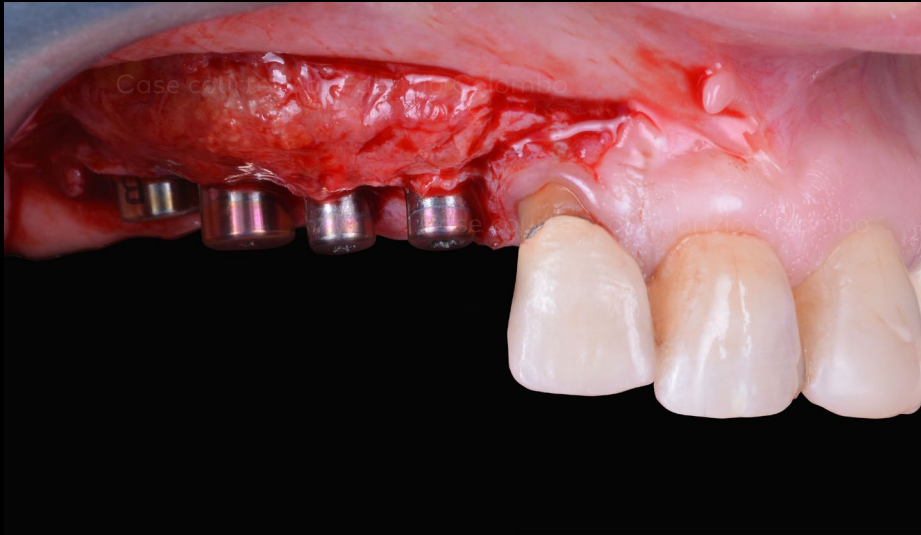
Treatment planning

Surgical procedure

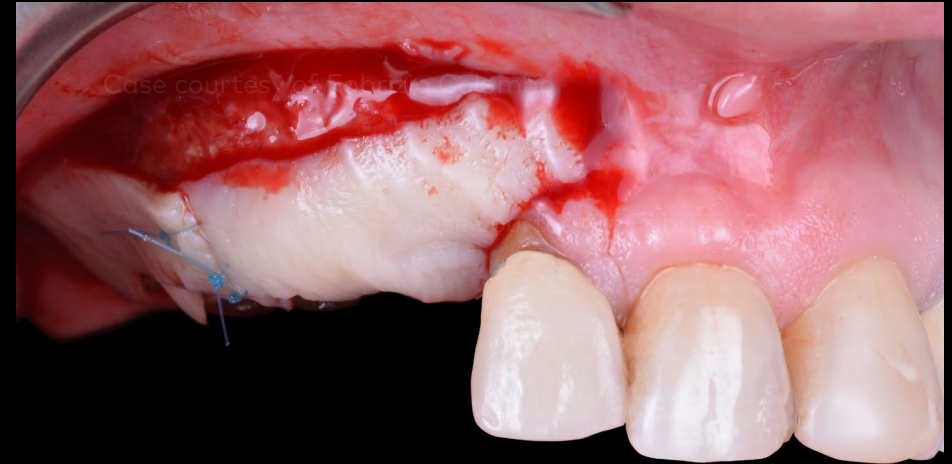Restorative procedure

Outcome

Soft tissue management



Placement of 4 healing abutments



Placement of an epithelial-connectival tissue graft

Initial clinical situation

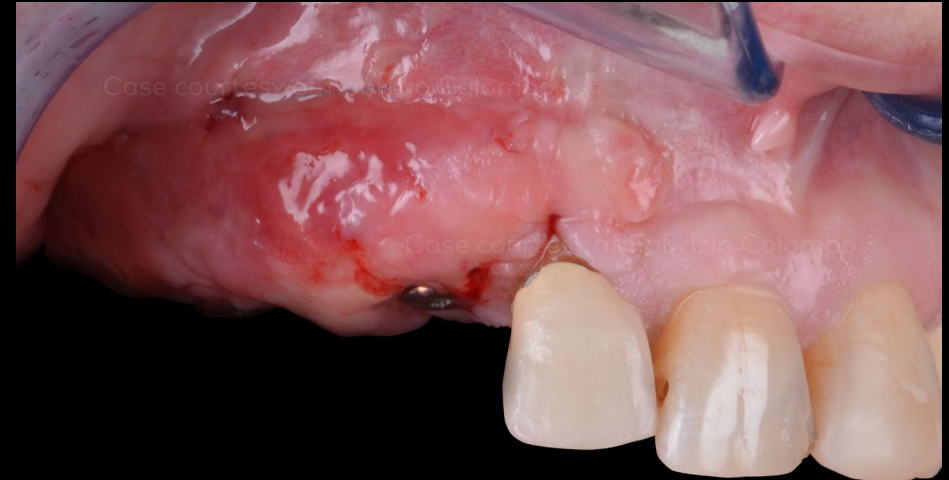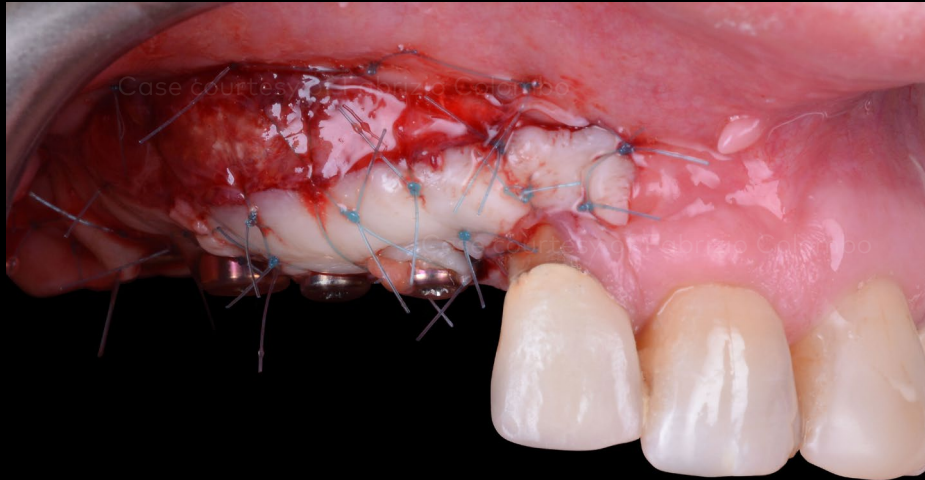
Treatment planning

Surgical procedure

Restorative procedure

Outcome

Soft tissue management



End of the soft tissue surgery

10 days of healing after soft tissue surgery

Initial clinical situation

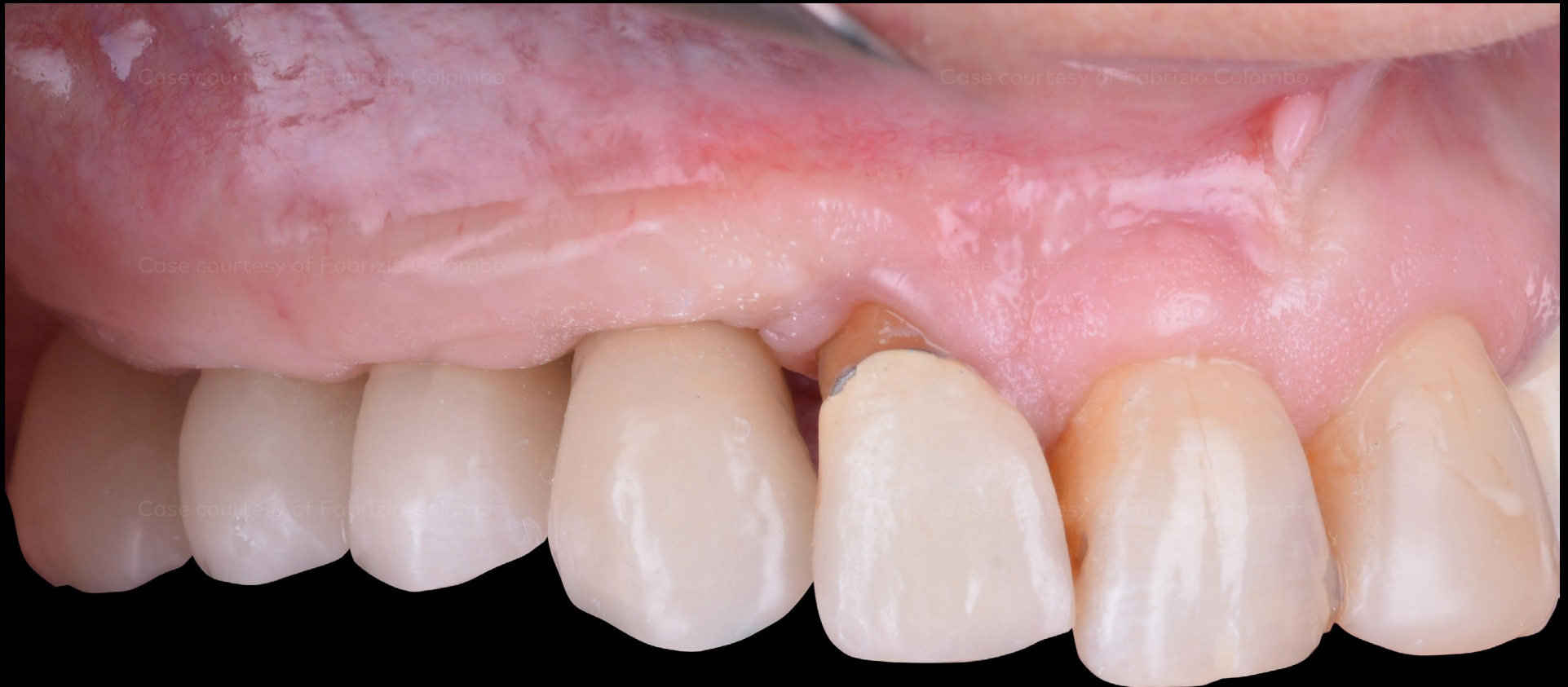Treatment planning

Surgical procedure

Restorative procedure

Outcome

First quadrant rehabilitation



Clinical picture just after provisional insertion

Initial clinical situation

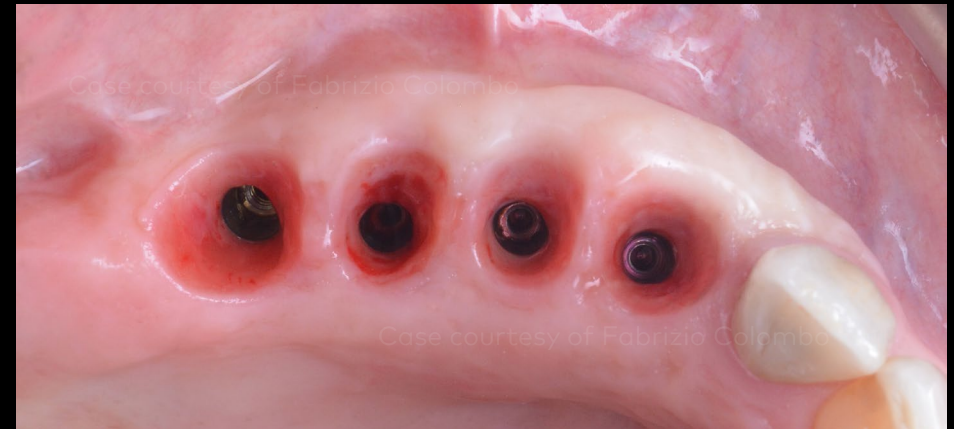
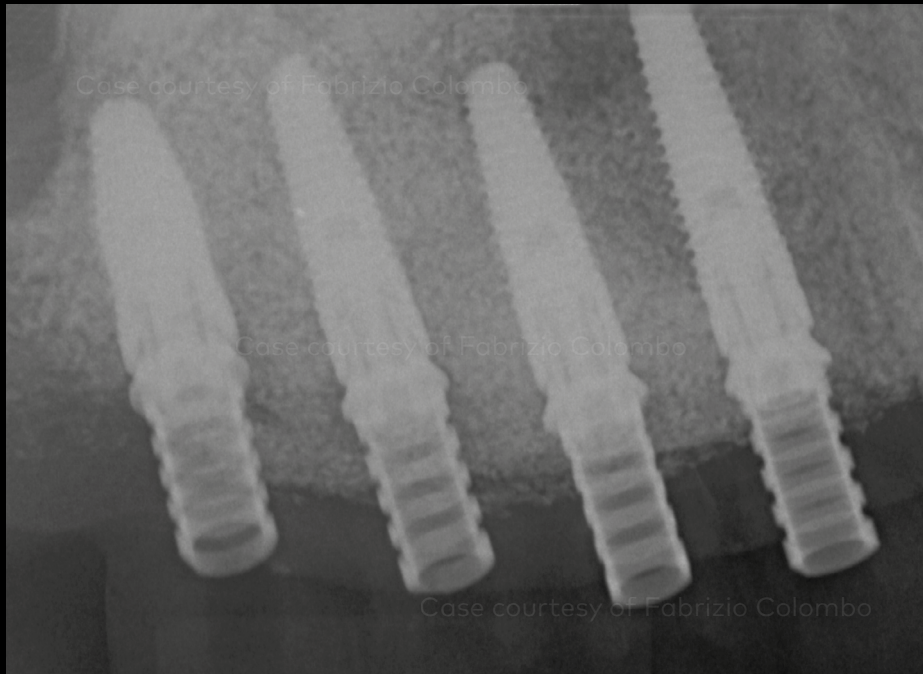
Treatment planning

Surgical procedure

Restorative procedure

Outcome

First quadrant rehabilitation



Radiograph 10 months after provisionalization

Final soft tissue picture

Initial clinical
situation

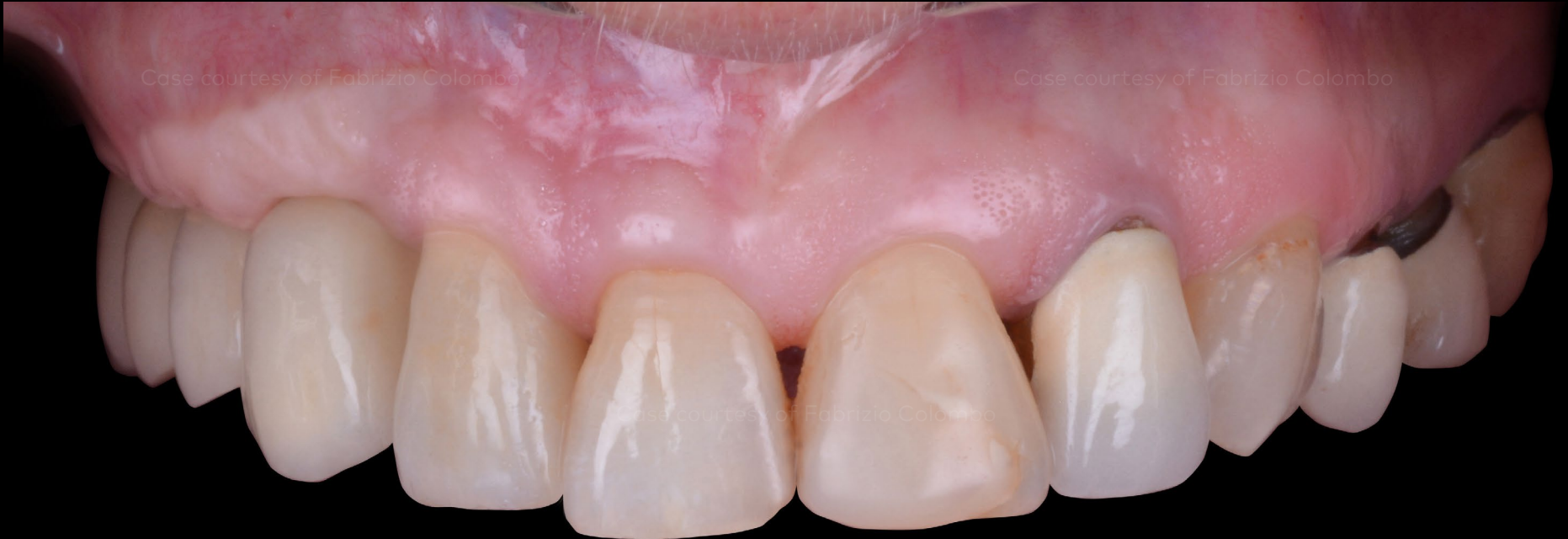Treatment
planning

Surgical
procedure

Restorative
procedure

Outcome

Atrophic first quadrant rehabilitation



Clinical picture (frontal view) 2 weeks after final prosthesis insertion

Initial clinical situation

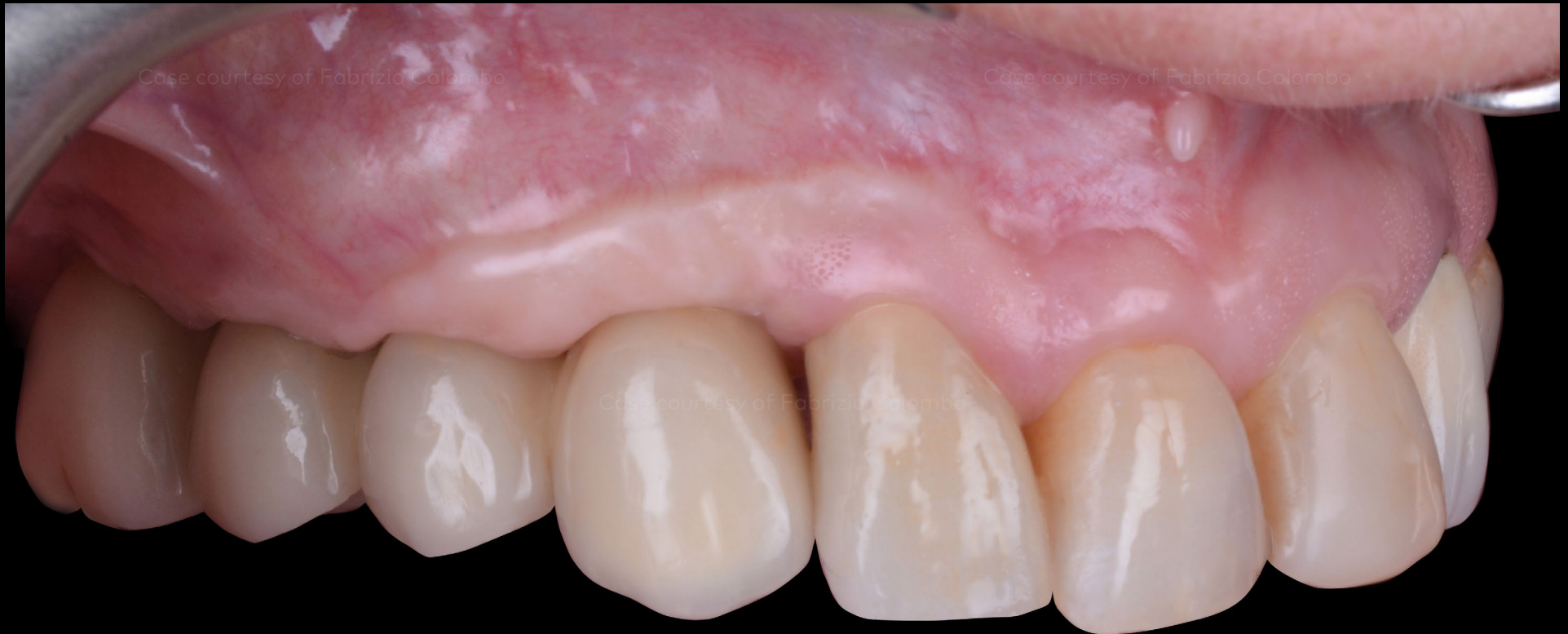Treatment planning

Surgical procedure

Restorative procedure

Outcome

Atrophic first quadrant rehabilitation



Clinical picture (lateral view) 2 weeks after final prosthesis insertion

Initial clinical situation

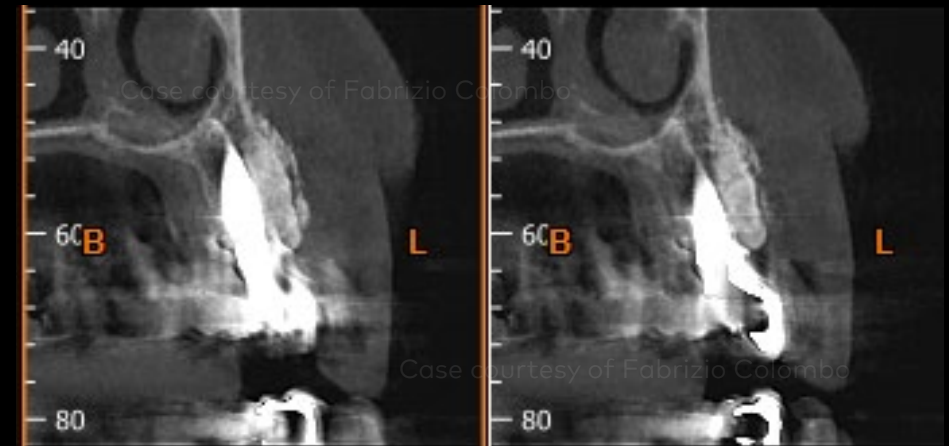
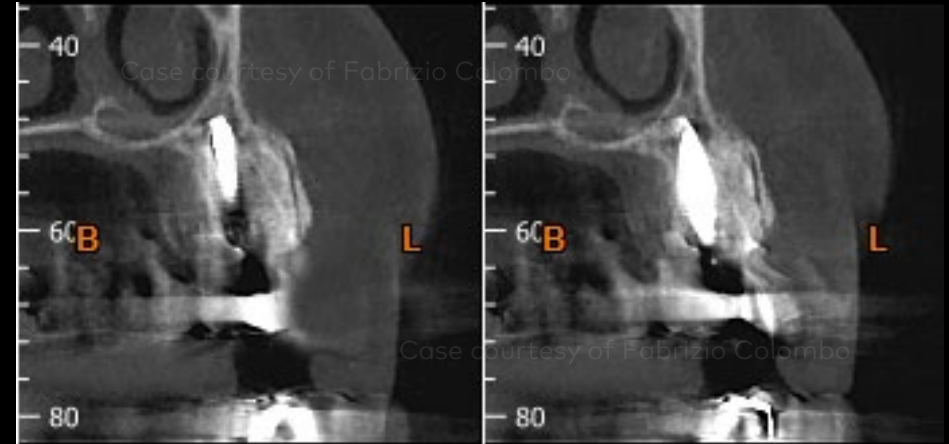
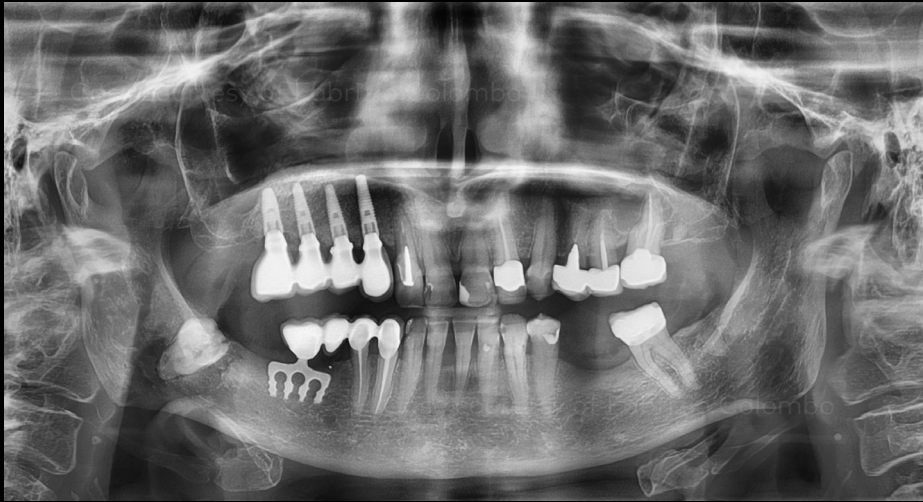
Treatment planning

Surgical procedure

Restorative procedure

Outcome

Atrophic first quadrant rehabilitation



OPG and CBCT 1 year after prosthetic loading

Case courtesy of Dr. Fabrizio Colombo, DDS

