

Vertical ridge augmentation of the anterior maxilla Utilizing reinforced PTFE mesh (RPM™)

Dr. Istvan Urban
DMD, MD, PhD





Dr. Istvan Urban

Patient

34-year-old female patient, healthy.

Clinical situation

Several failed bone graft surgeries in the history. Severe asymmetry and lack of lip support because of the underlying bone defect. Very unhappy with her facial appearance.

Surgical solution

Vertical ridge augmentation of the anterior maxilla; implant placement

Restorative solution

Implant bridge

Surgery date

2020

Total treatment time

17 months

Tooth positions

#22, #24



**Initial clinical
situation**

**Treatment
planning**

**Surgical
procedure**

**Restorative
procedure**

Outcome

Vertical ridge augmentation of the anterior maxilla utilizing reinforced PTFE mesh (RPM™)

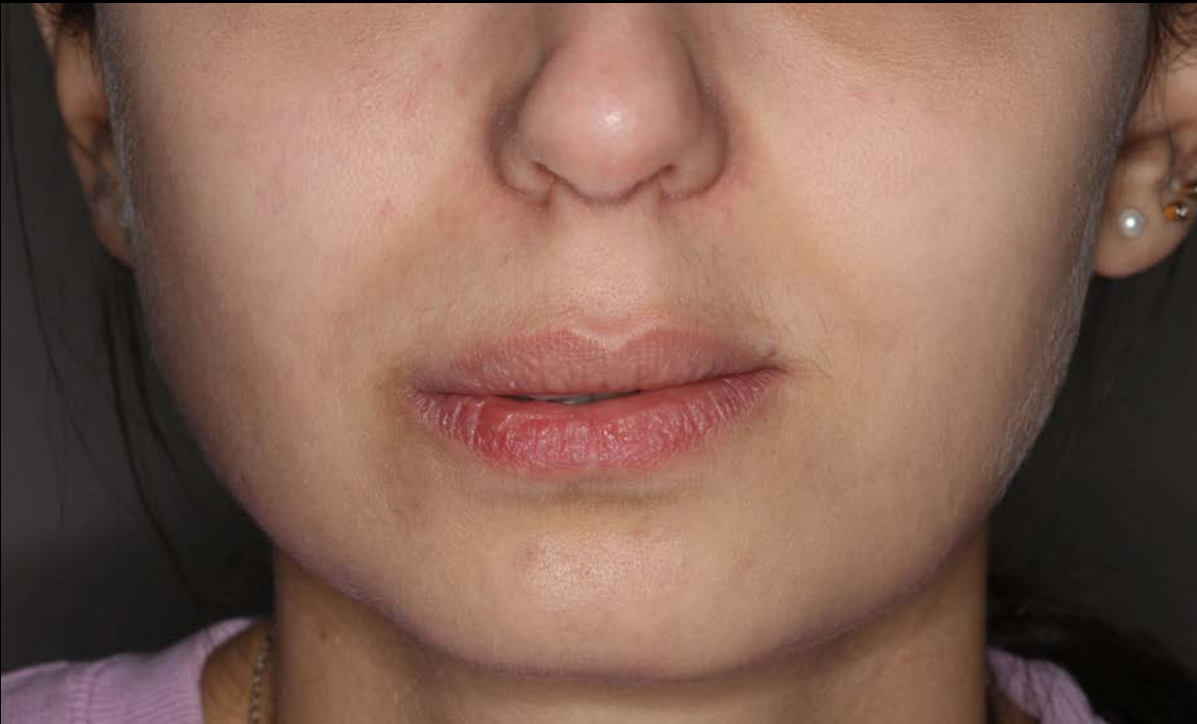

Figure 1. Labial view of the face demonstrates severe asymmetry and lack of lip support because of the underlying bone defect.

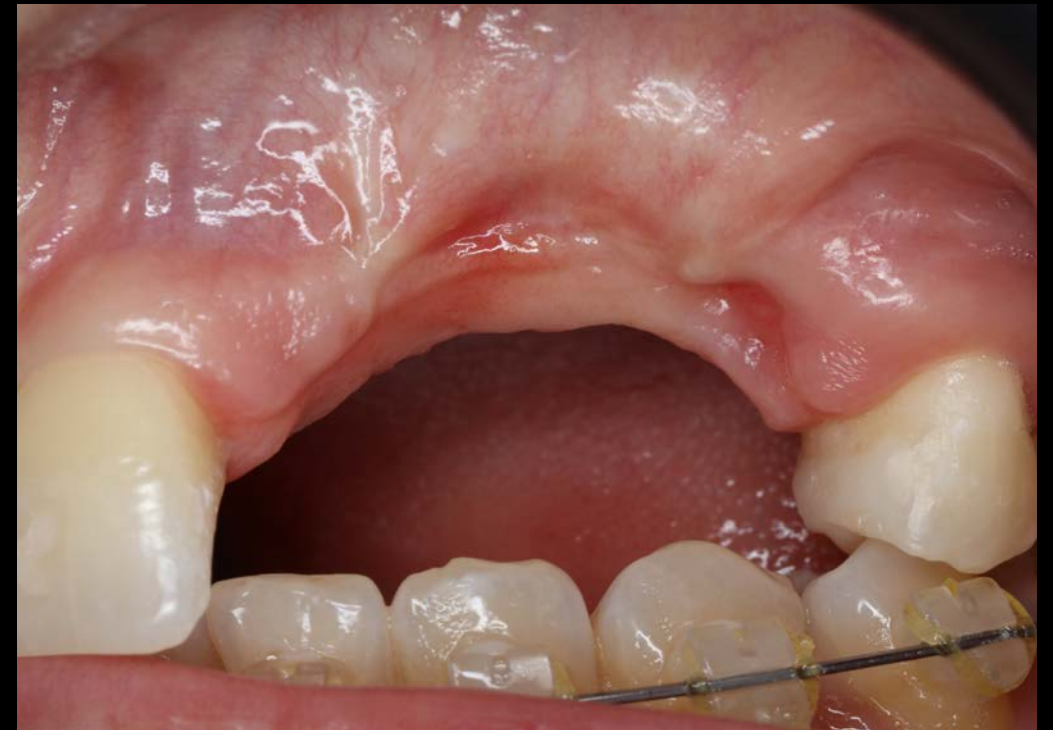

Figure 2. Labial view of severe vertical defect of the anterior maxilla involving three teeth.

**Initial clinical
situation**

**Treatment
planning**

**Surgical
procedure**

**Restorative
procedure**

Outcome

Vertical ridge augmentation of the anterior maxilla utilizing reinforced PTFE mesh (RPM™).

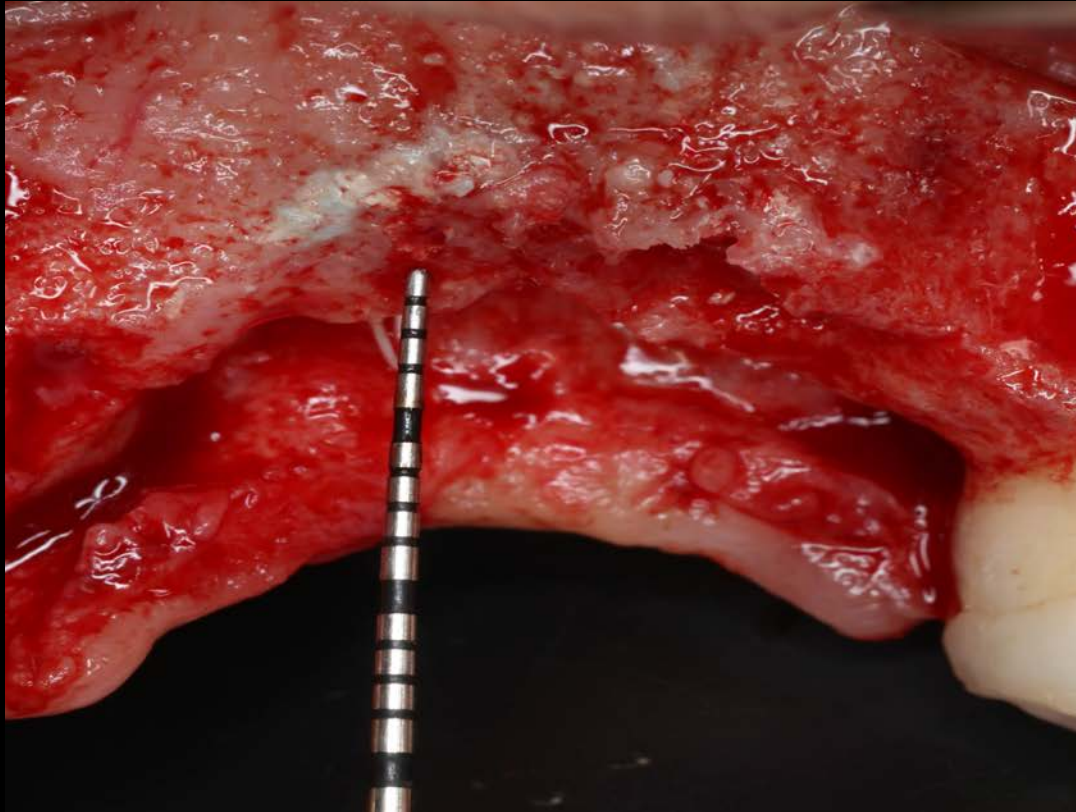


Figure 3. Labial view of the defect after flap elevation.

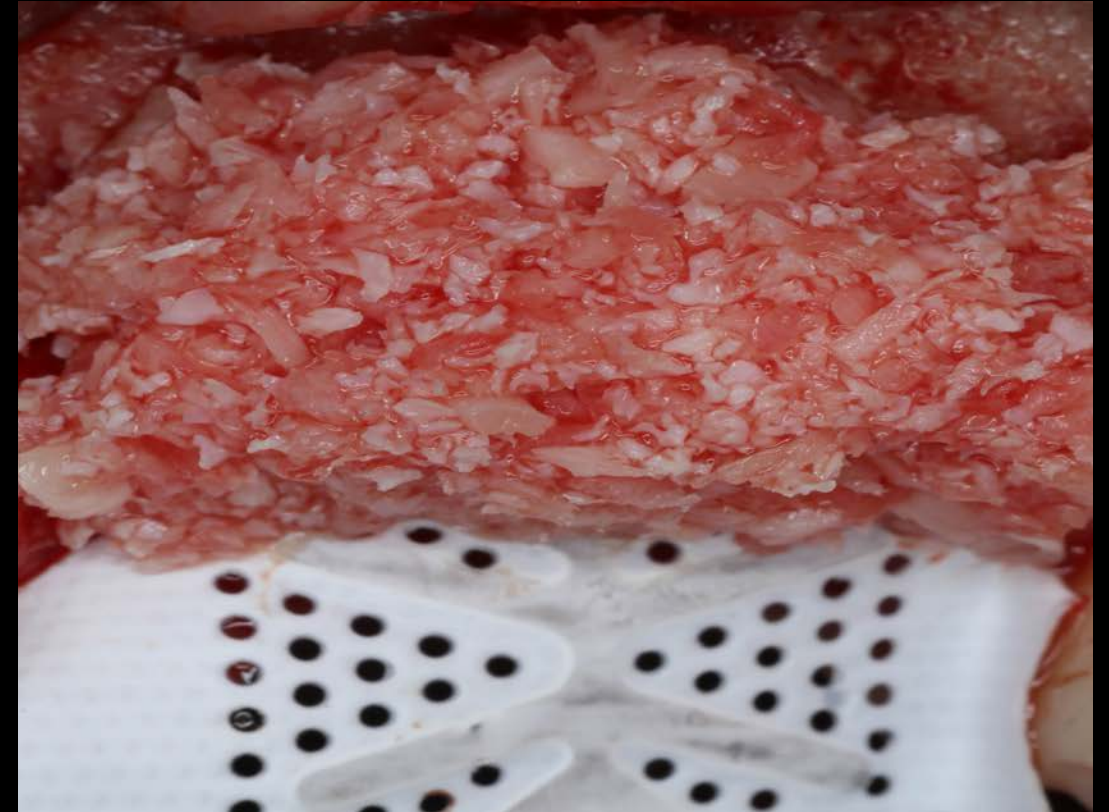

Figure 4. Labial view of a particulate bone graft composing of a 1:1 ratio of autogenous bone and a xenogenic bone graft. Perforated PTFE (RPM) membrane was fixated before the graft was applied.

**Initial clinical
situation**

**Treatment
planning**

**Surgical
procedure**

**Restorative
procedure**

Outcome

Vertical ridge augmentation of the anterior maxilla utilizing reinforced PTFE mesh (RPM™).

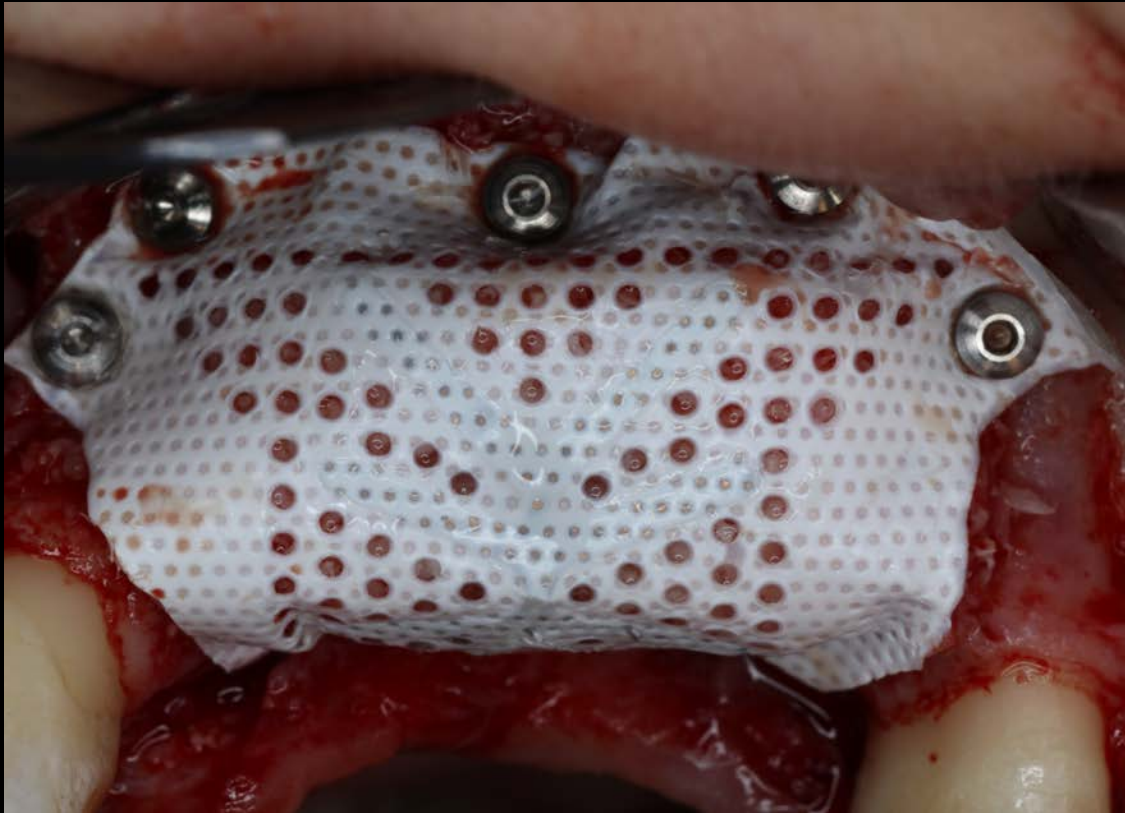

Fig 5. Labial view of the membrane after complete fixation. Several titanium pins were utilized for the fixation.

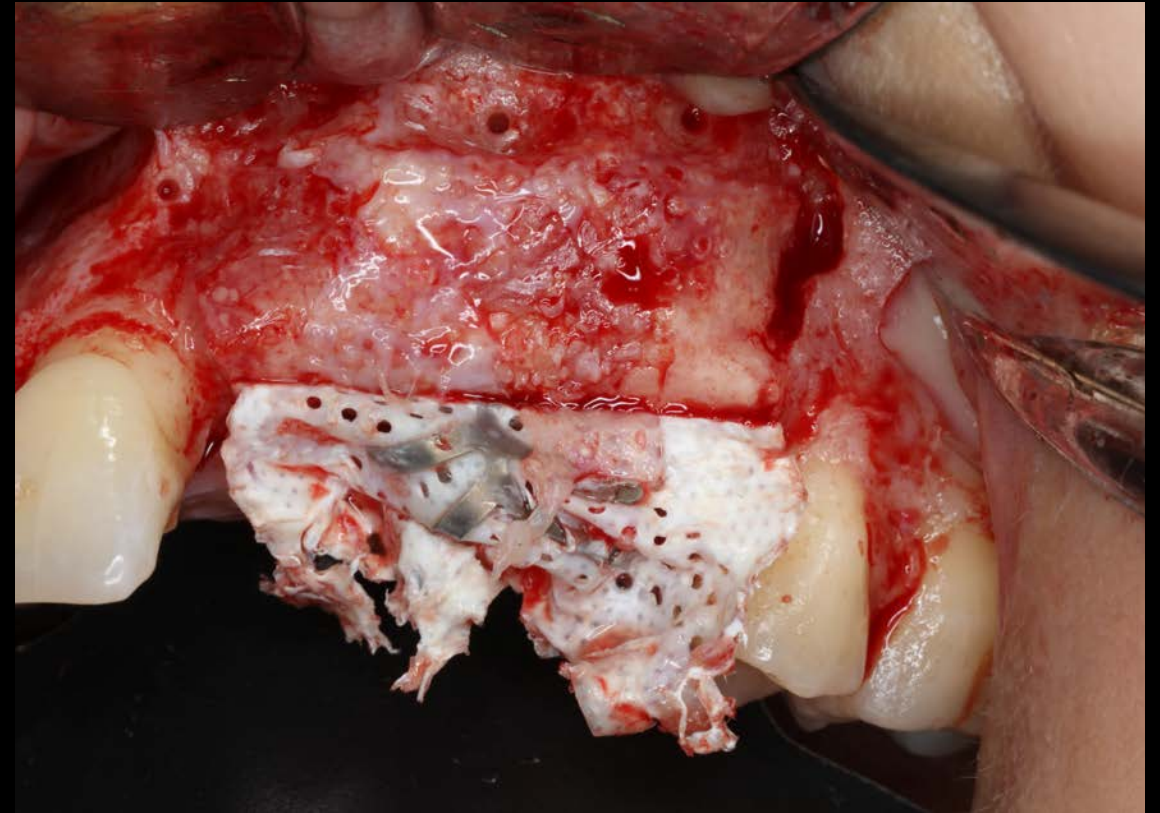


Fig 6. Labial view at membrane removal after 8 months of uneventful healing.

**Initial clinical
situation**

**Treatment
planning**

**Surgical
procedure**

**Restorative
procedure**

Outcome

Vertical ridge augmentation of the anterior maxilla utilizing reinforced PTFE mesh (RPM™).

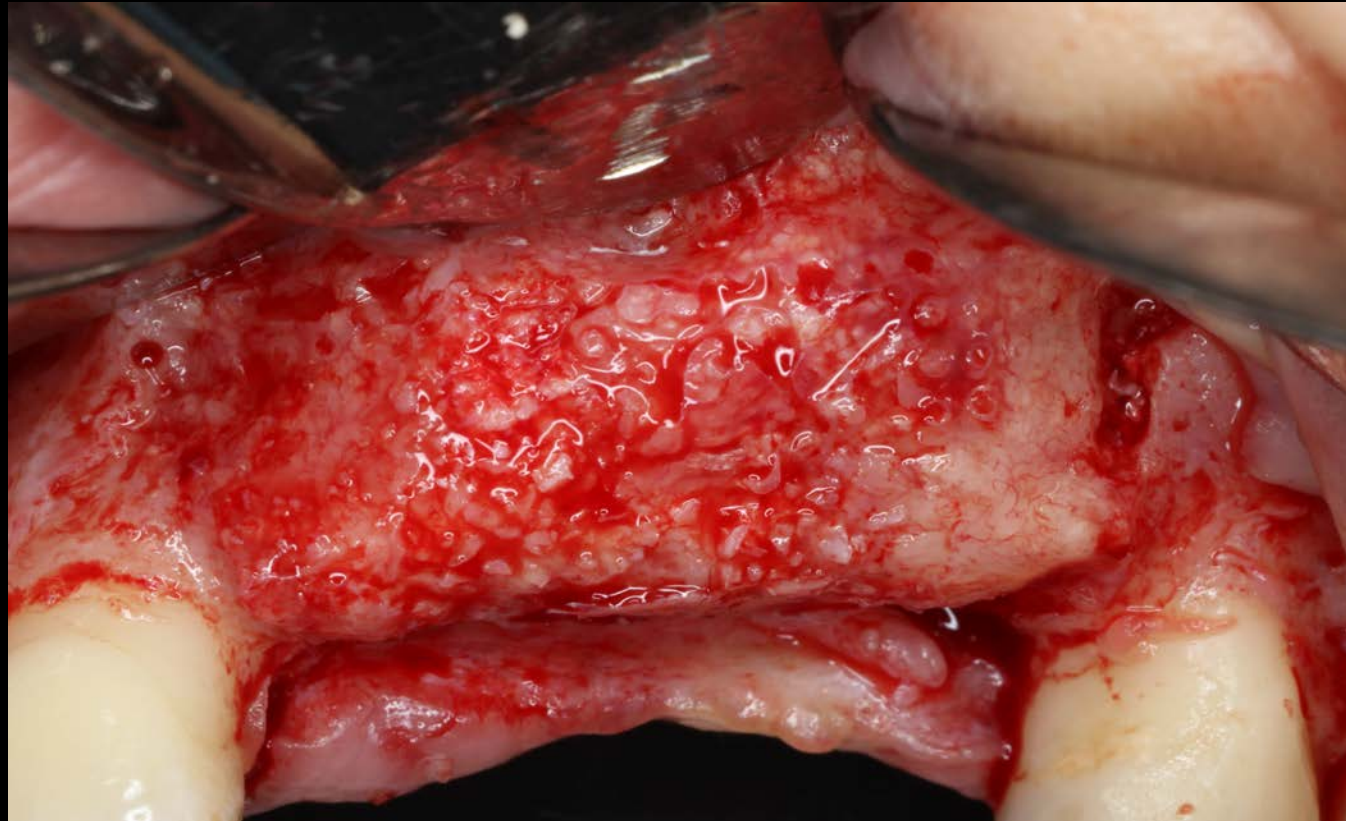


Figure 7. Labial view of the regenerated bone demonstrating a complete vertical and horizontal bone gain.

**Initial clinical
situation**

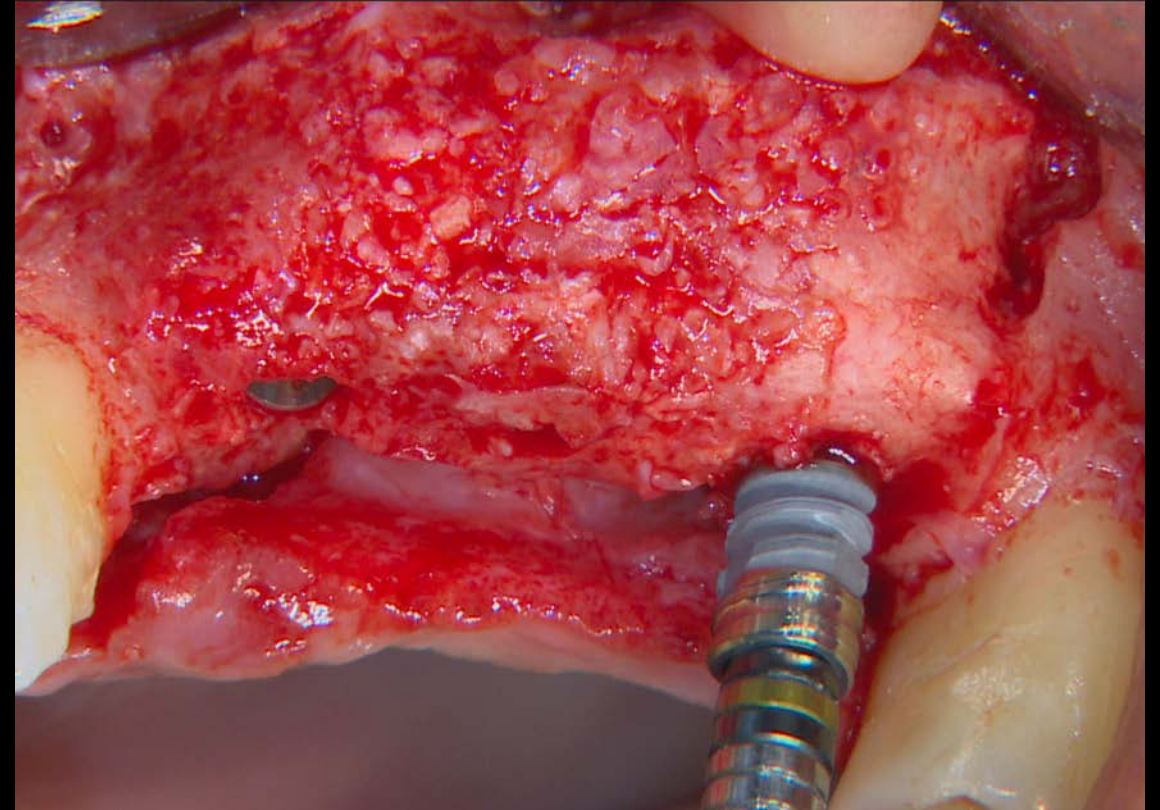
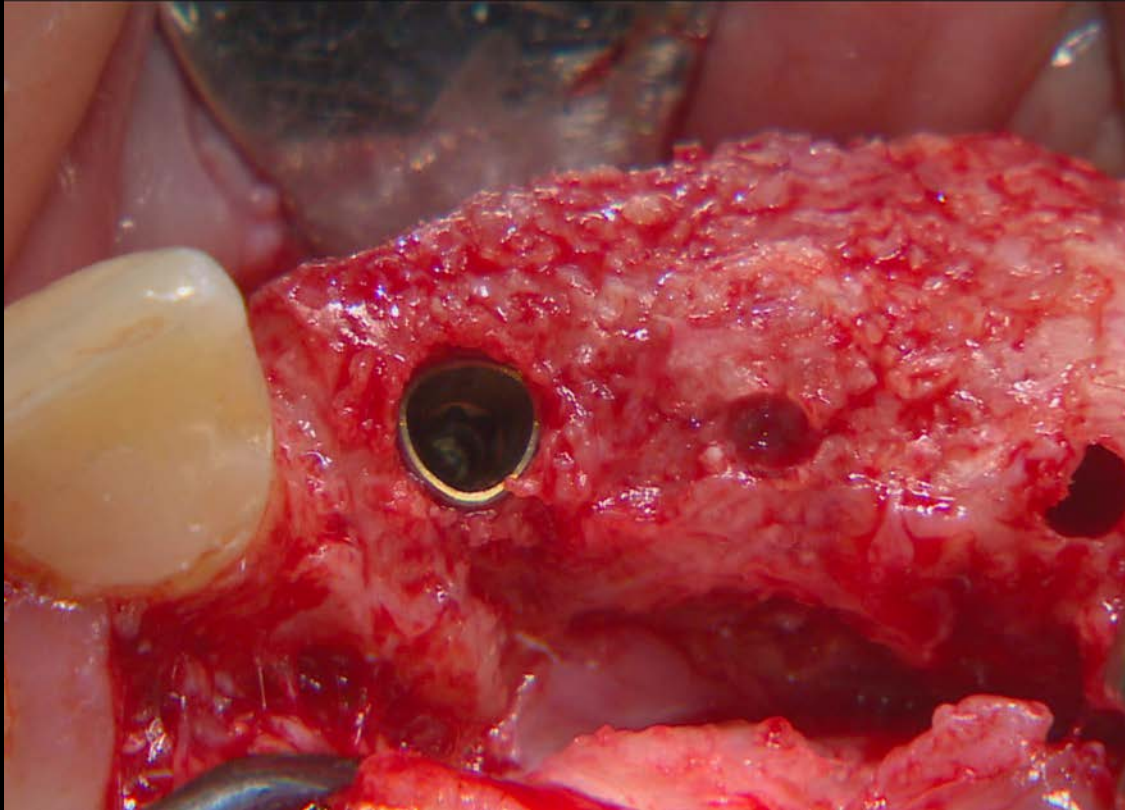
**Treatment
planning**

**Surgical
procedure**

**Restorative
procedure**

Outcome

Vertical ridge augmentation of the anterior maxilla utilizing reinforced PTFE mesh (RPM™).



Figures 8 and 9. Labial and occlusal views of defect during implant placement. Two Nobel Biocare N1™ Implants were placed.

Initial clinical
situation

Treatment
planning

Surgical
procedure

Restorative
procedure

Outcome

Vertical ridge augmentation of the anterior maxilla utilizing reinforced PTFE mesh (RPM™).

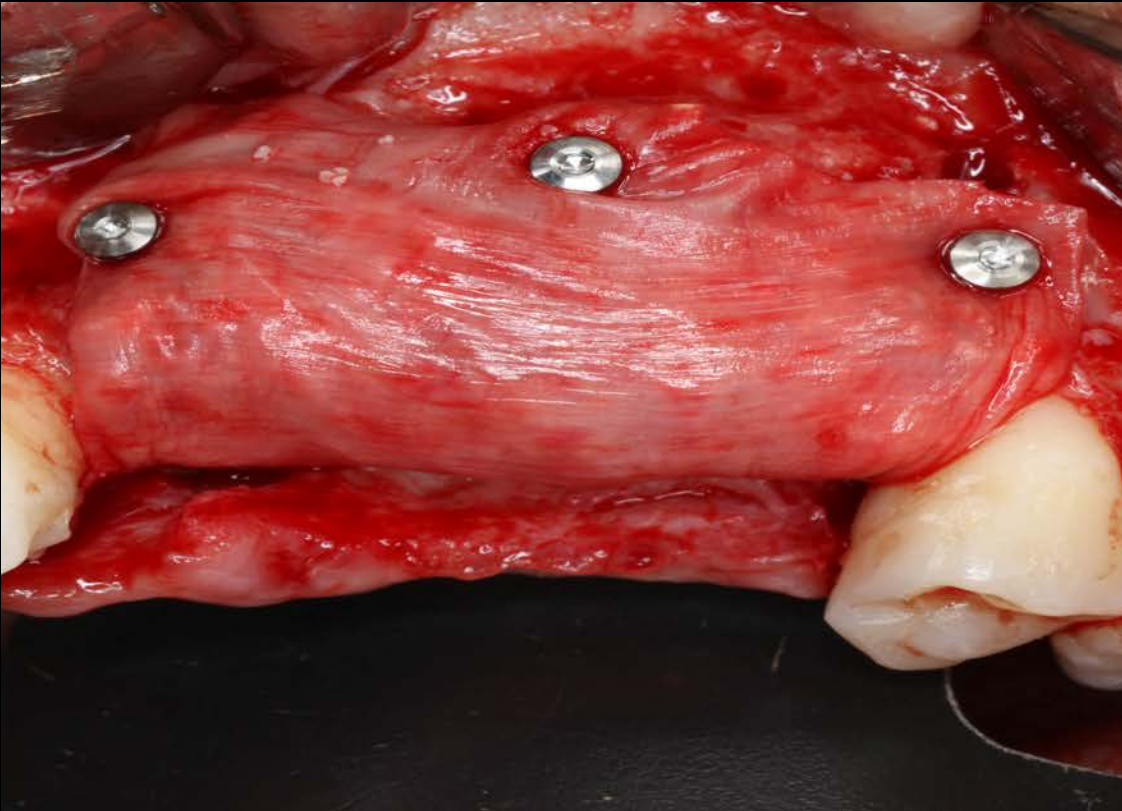


Figure 10. Labial view of a protection layer of bone graft called a “mini sausage.” 20% autograft and 80% xenograft were utilized for this graft. The collagen membrane was fixated with titanium pins. The goal of the graft was to protect the newly formed bone from any resorption.

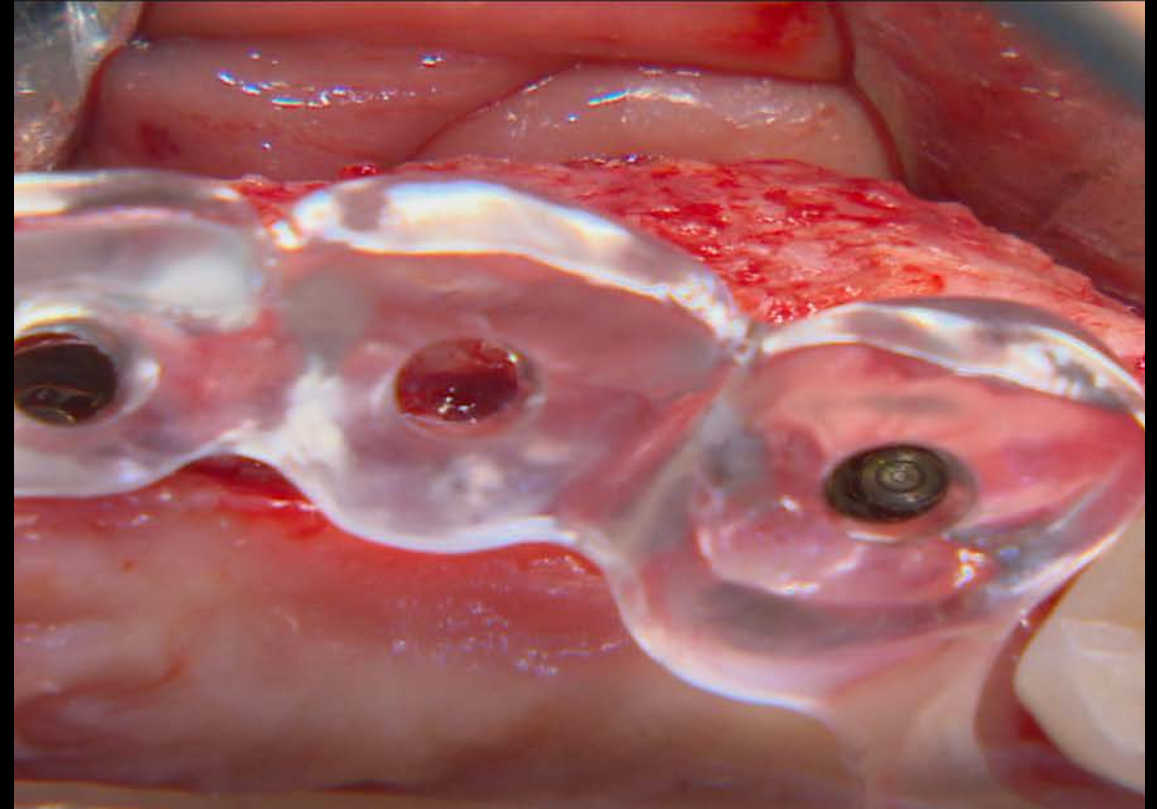


Figure 11. Occlusal view of a surgical guide in place demonstrating good prosthetic positions of the implants.

**Initial clinical
situation**

**Treatment
planning**

**Surgical
procedure**

**Restorative
procedure**

Outcome

Vertical ridge augmentation of the anterior maxilla utilizing reinforced PTFE mesh (RPM™).

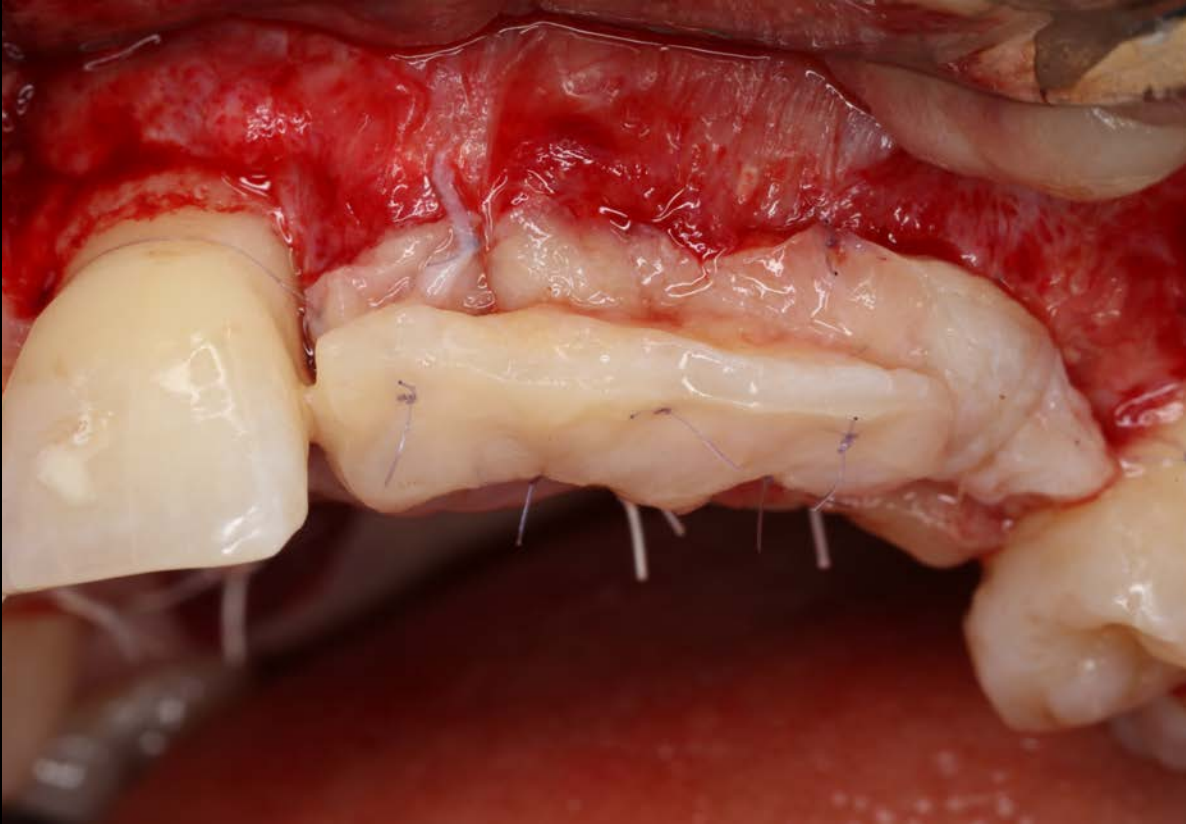


Figure 12. A double layer, Iceberg connective tissue graft was placed over the implants to increase tissue thickness.

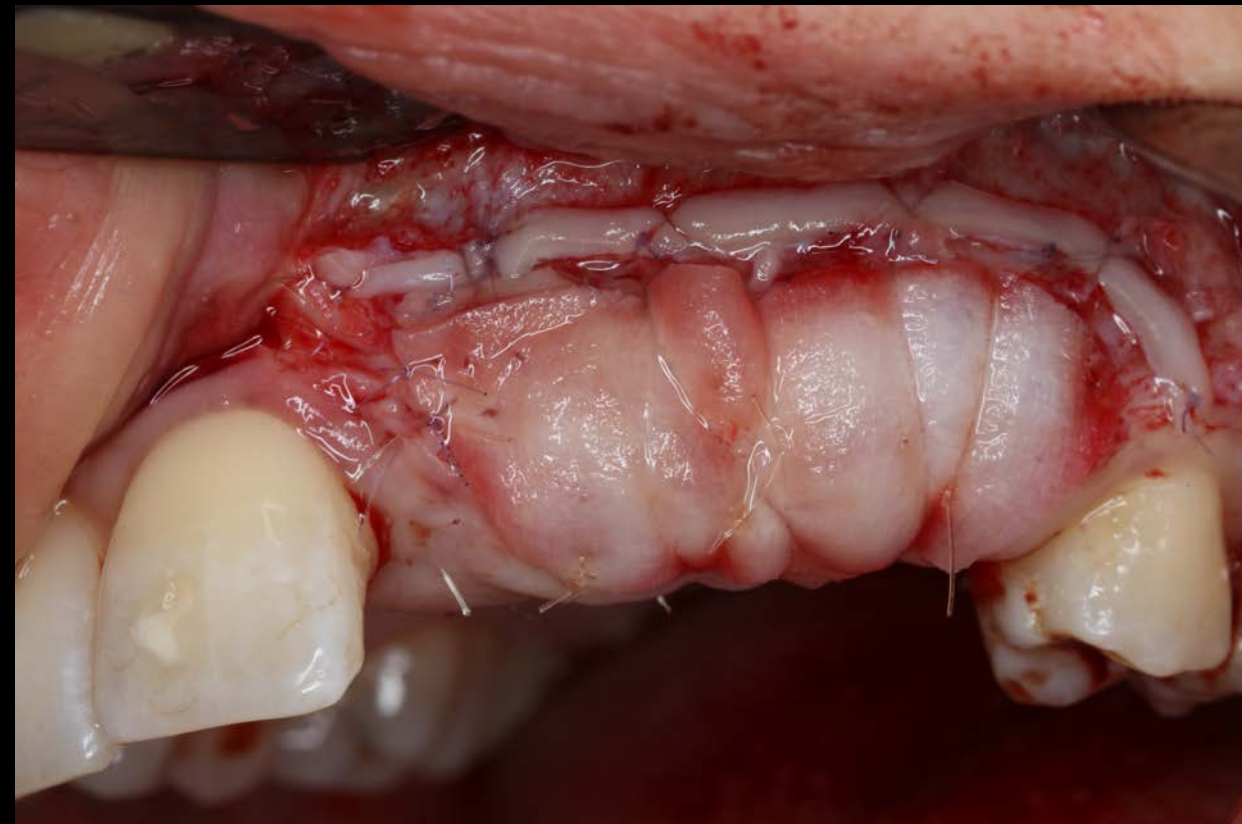

Figure 13. A strip gingival graft harvested from the labial gingiva was utilized in combination with the collagen matrix to reconstruct the vestibule and keratinized tissue.

**Initial clinical
situation**

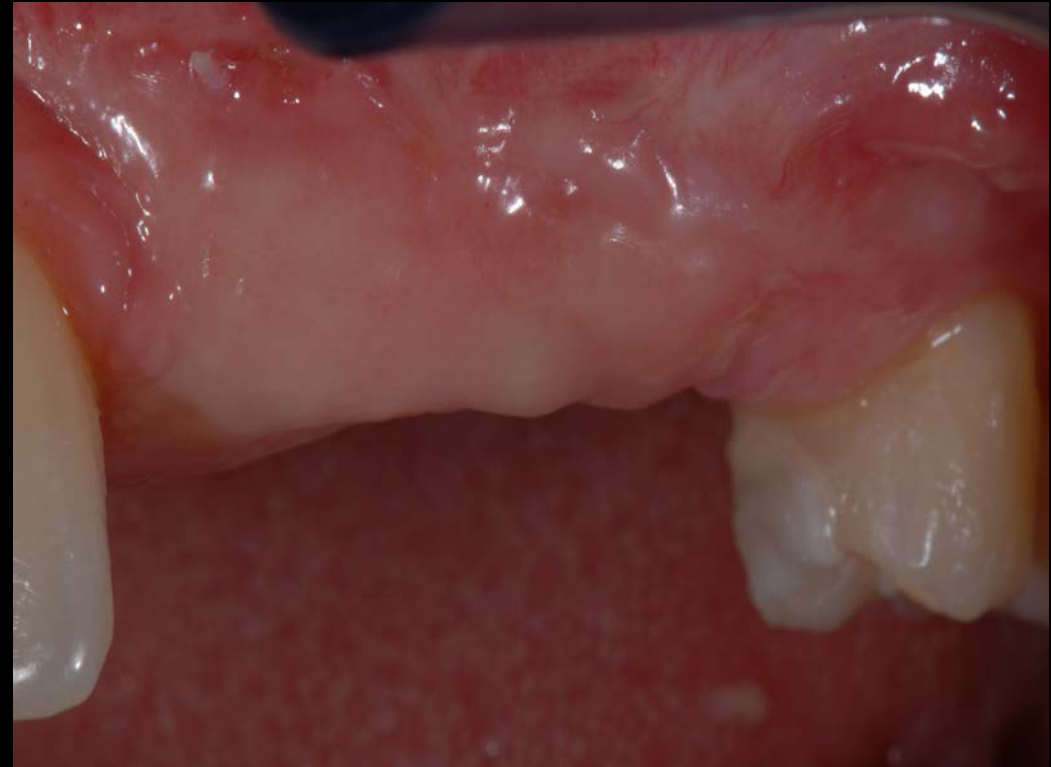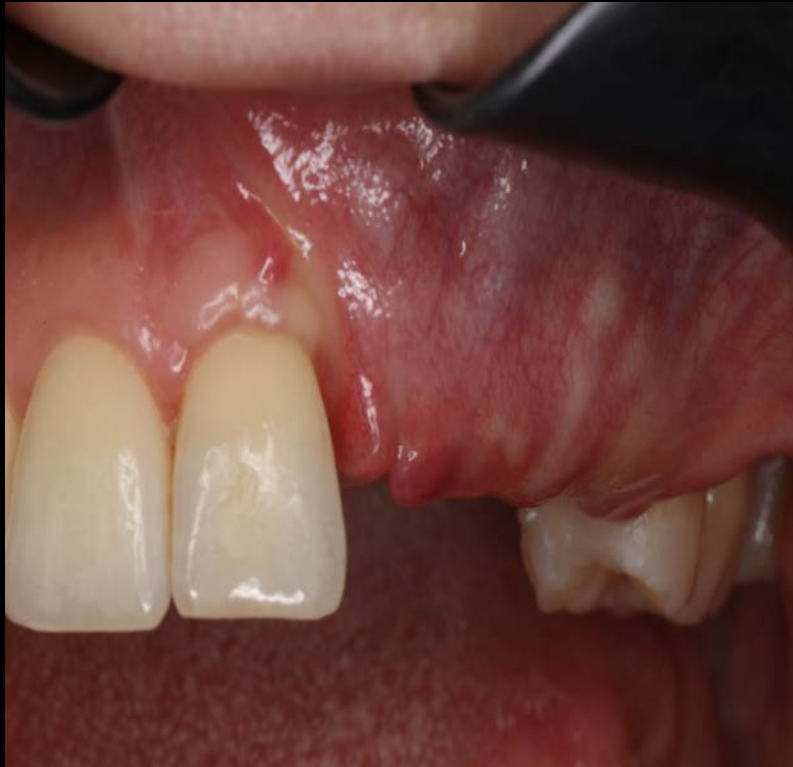**Treatment
planning**

**Surgical
procedure**

**Restorative
procedure**

Outcome

Vertical ridge augmentation of the anterior maxilla utilizing reinforced PTFE mesh (RPM™).



Figures 14 and 15. Labial view of the reconstructed soft tissue demonstrating a natural color.

**Initial clinical
situation**

**Treatment
planning**

**Surgical
procedure**

**Restorative
procedure**

Outcome

Vertical ridge augmentation of the anterior maxilla utilizing reinforced PTFE mesh (RPM™).

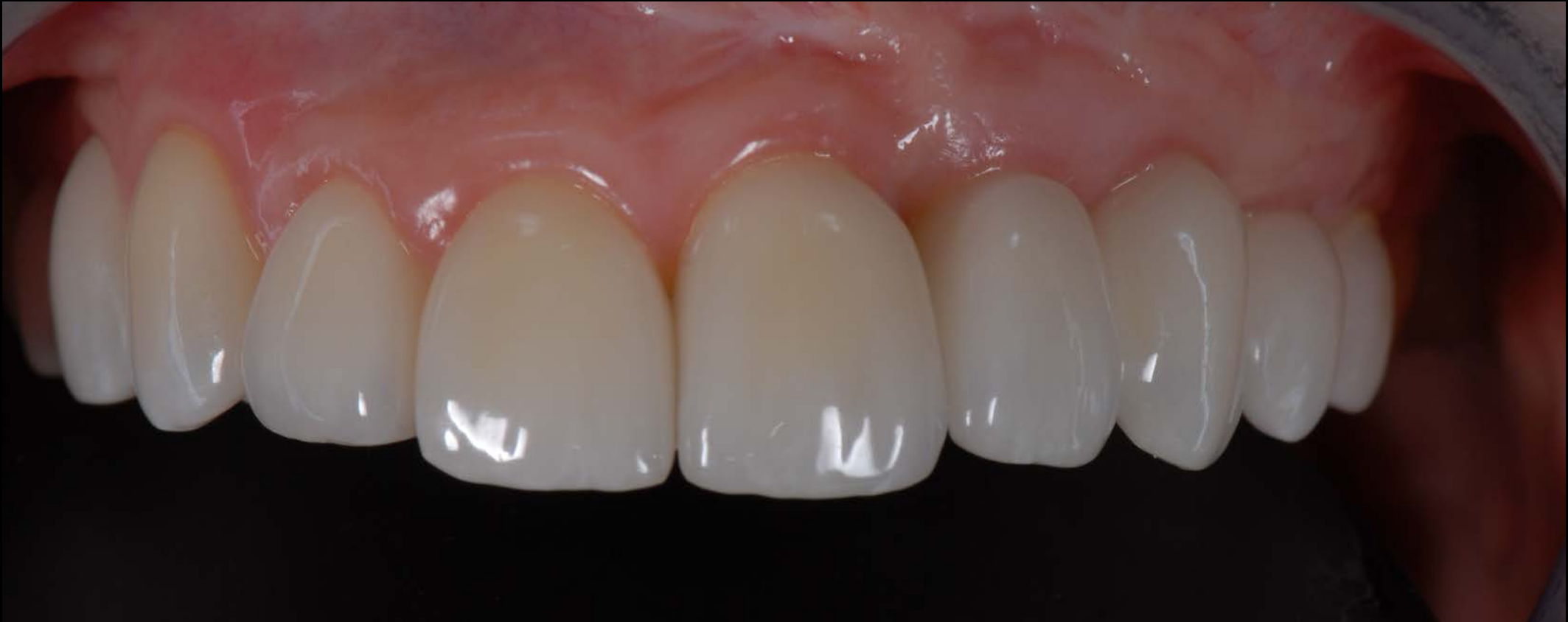

Figure 16. Labial view of the final restoration in place.

**Initial clinical
situation**

**Treatment
planning**

**Surgical
procedure**

**Restorative
procedure**

Outcome

Vertical ridge augmentation of the anterior maxilla utilizing reinforced PTFE mesh (RPM™).

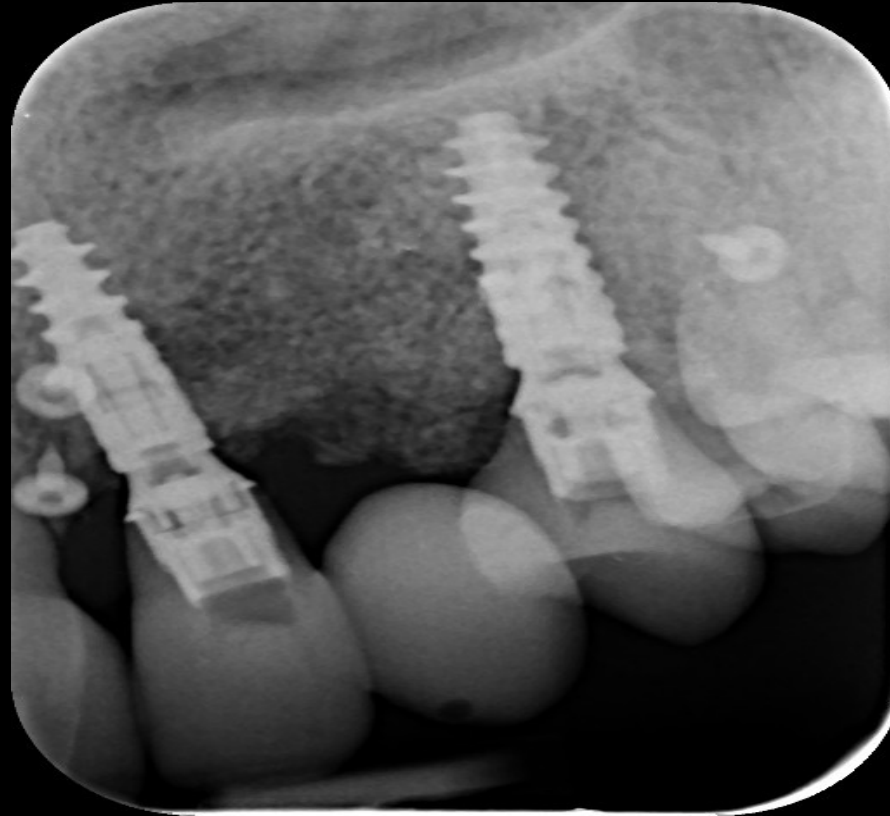


Fig 17. Periapical radiographs demonstrate good bone stability after loading.

**Initial clinical
situation**

**Treatment
planning**

**Surgical
procedure**

**Restorative
procedure**

Outcome

Vertical ridge augmentation of the anterior maxilla utilizing reinforced PTFE mesh (RPM™).

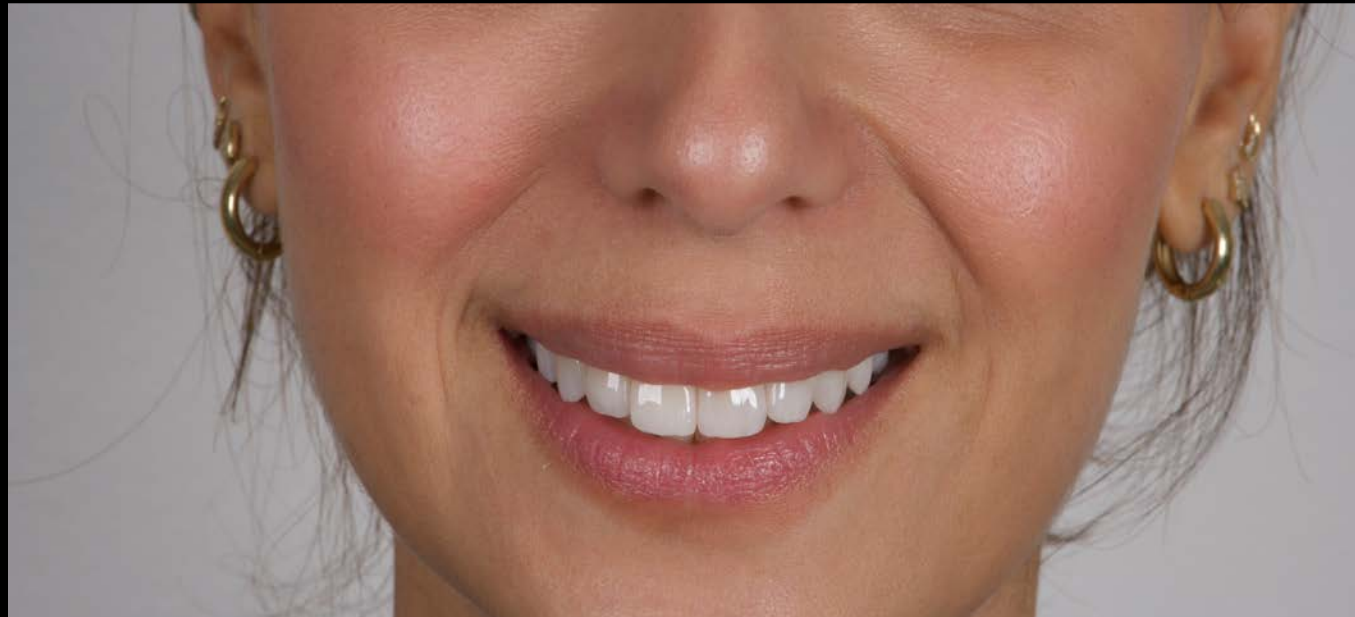

Figure 18. Facial view demonstrates beautiful lip support and symmetry after treatment.

Case courtesy of Dr. Istvan Urban



MKT-5677 Rev 00 (05/24, GMT 90566) © Nobel Biocare USA, LLC, 2024. All rights reserved. Nobel Biocare, the Nobel Biocare logotype and all other trademarks are, if nothing else is stated or is evident from the context in a certain case, trademarks of Nobel Biocare. Please refer to nobelbiocare.com/trademarks for more information. Product images are not necessarily to scale. Disclaimer: Some products may not be regulatory cleared/released for sale in all markets. Please contact the local Nobel Biocare sales office for current product assortment and availability. Caution: Federal (United States) law restricts this device to sale by or on the order of a dentist or physician. See Instructions For Use for full prescribing information, including indications, contraindications, warnings and precautions. Nobel Biocare does not take any liability for any injury or damage to any person or property arising from the use of this clinical case. This clinical case is not intended to recommend any measures, techniques, procedures or products, or give advice, and is not a substitute for medical training or your own clinical judgement as a healthcare professional. Viewers should never disregard professional medical advice or delay seeking medical treatment because of something they have seen in this clinical case. Full procedure is not shown. Certain sequences have been cut.