

Immediate esthetic and functional rehabilitation of a complete mouth using the All-on-4® treatment concept

Prof. Enrico Agliardi
Italy





**Prof. Enrico
Agliardi**

Patient

59-year-old female

Clinical situation

Failing dentition in the upper and lower jaw due to severe periodontal disease, compromised function

Surgical solution

Extraction of compromised residual teeth and placement of 4 Nobel Biocare N1 implants in the maxilla and 4 intraoral implants in the mandible following the All-on-4® surgical protocol.

Restorative solution

Full zirconia implant bridge (Nacera)

Surgery date

March 2021

Total treatment time

6 months

Tooth position

All

Despite adequate bone volume, the case presents several challenges both surgically and prosthetically. From a surgical point of view, the management of an extensive gummy smile has been planned to be corrected through an osteotomy calibrated on extra and intraoral images prior to surgery. Prosthetically speaking the delivery of an immediate rehabilitation of both arches is another challenge faced during the case, due to the lack of reference points and severely compromised esthetics which has been managed through careful planning of the prosthesis manufactured prior to surgery. The key factor for the success was extensive back work analyzing models and photographic records.

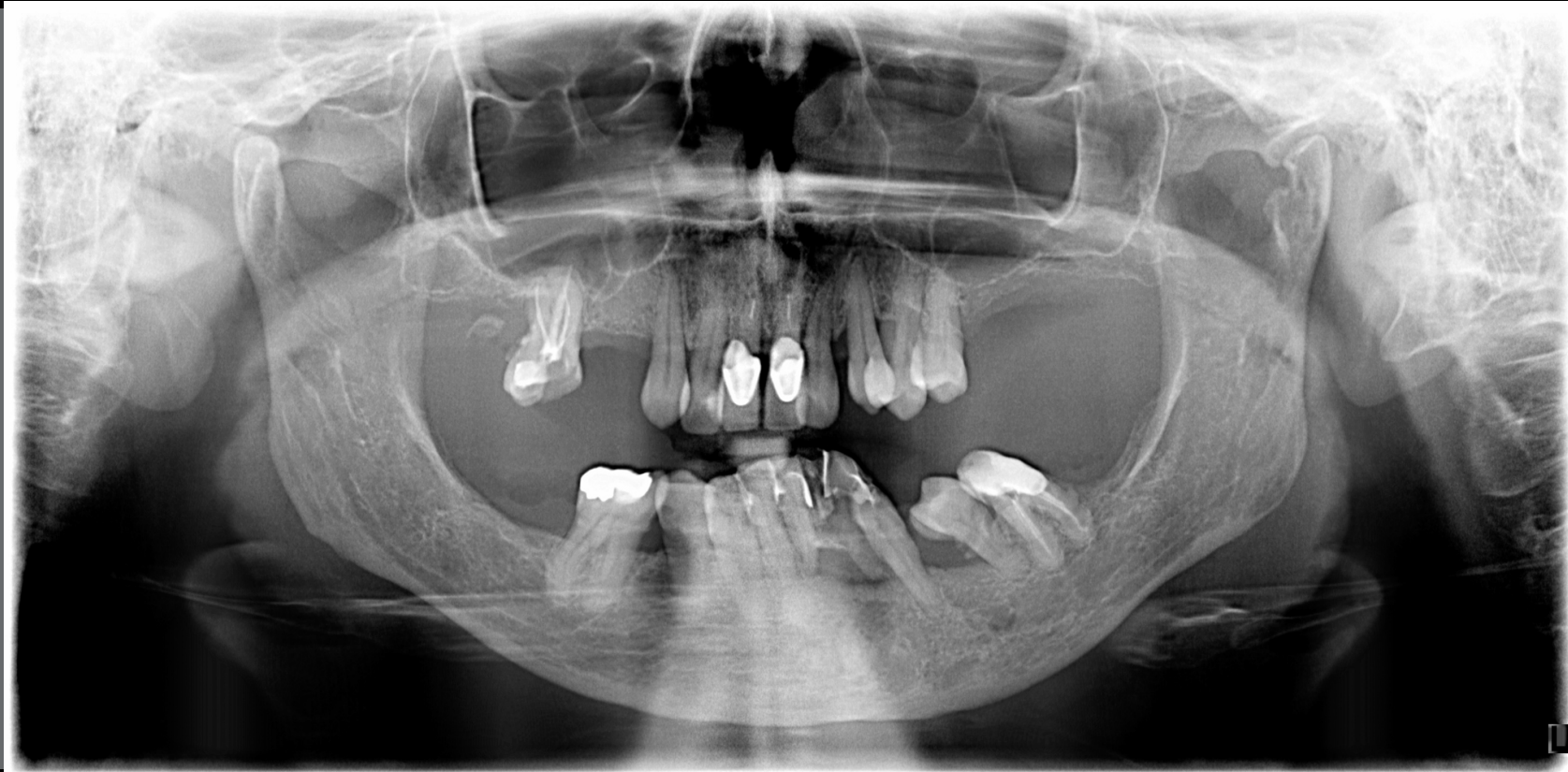Initial clinical situation

Treatment planning

Surgical procedure

Restorative procedure

Outcome



Pre-operative x-ray. Residual teeth present severe periodontal disease and compromised restorations

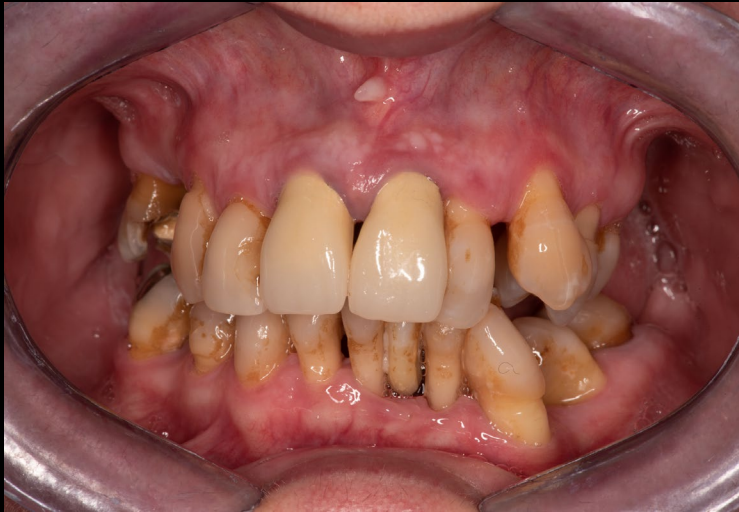Initial clinical situation

Treatment planning

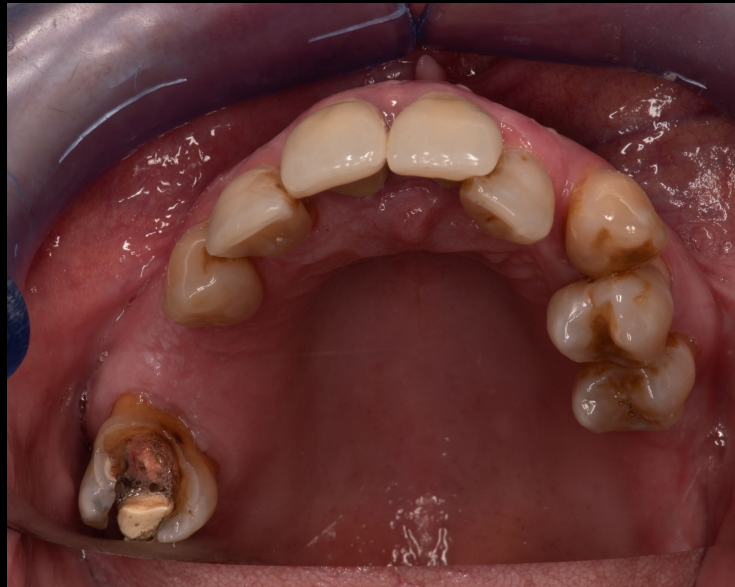Surgical procedure

Restorative procedure

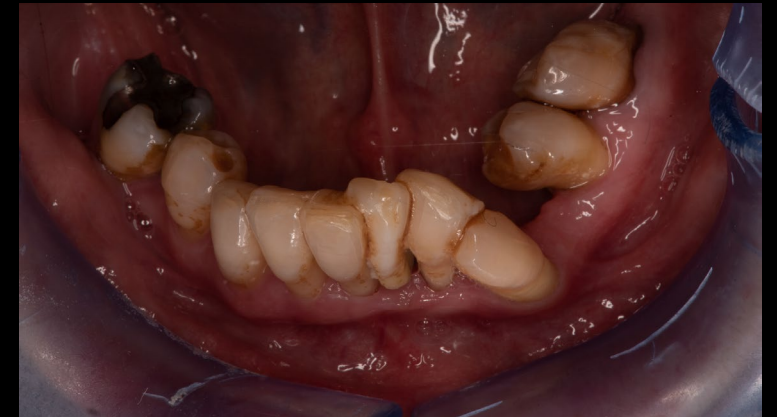Outcome



Intraoral preoperative frontal view



Intraoral preoperative upper jaw occlusal view



Intraoral preoperative lower jaw occlusal view

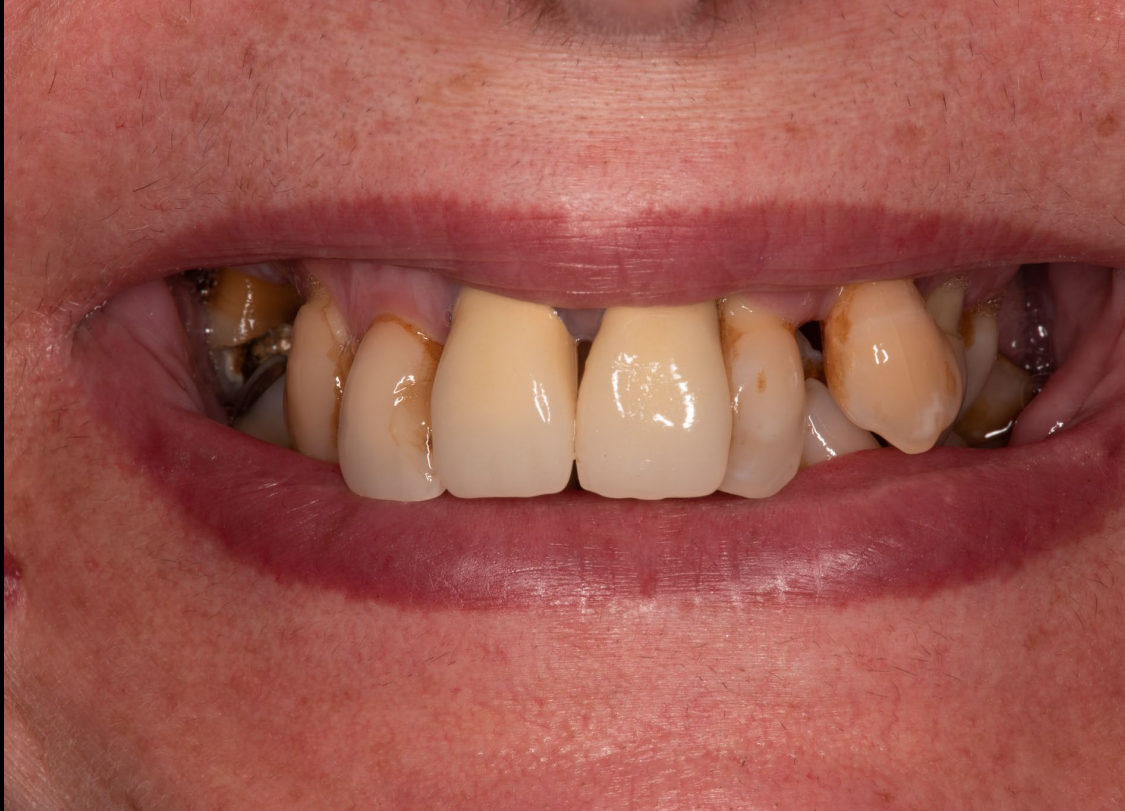Initial clinical situation

Treatment planning

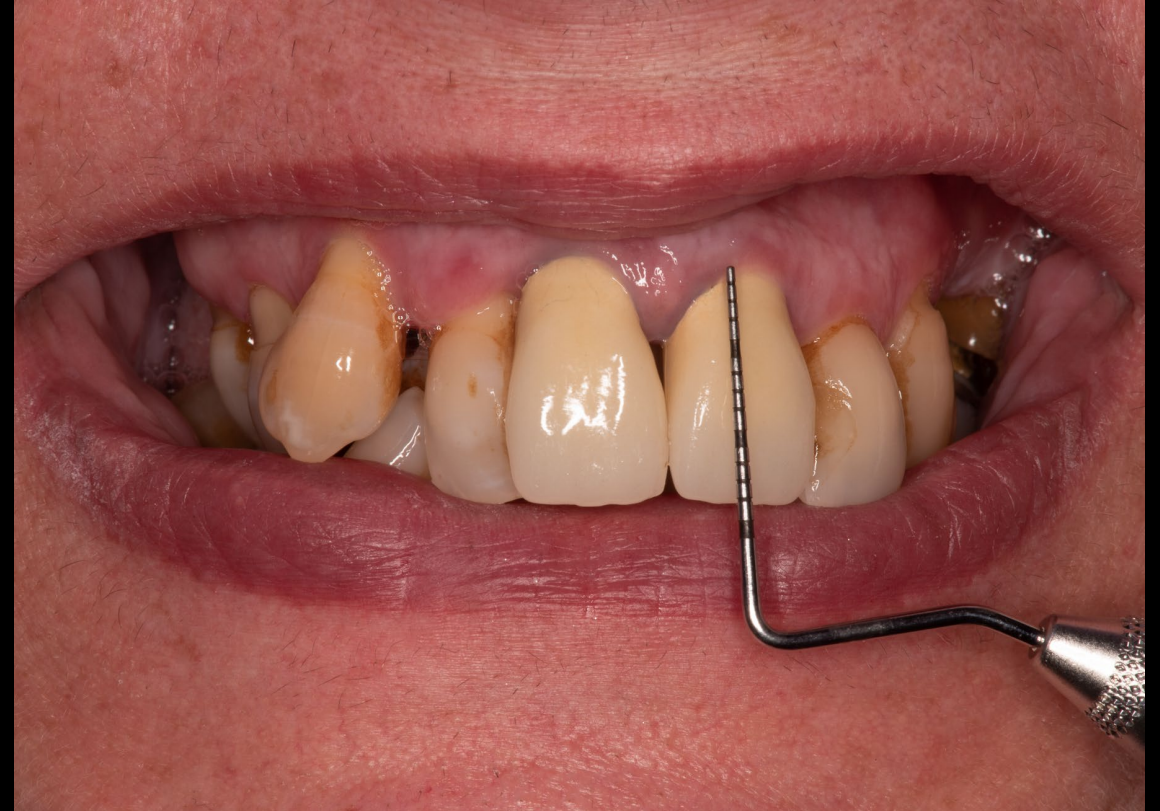Surgical procedure

Restorative procedure

Outcome



Smile of the patient before the surgery



Gummy smile analysis before the surgery

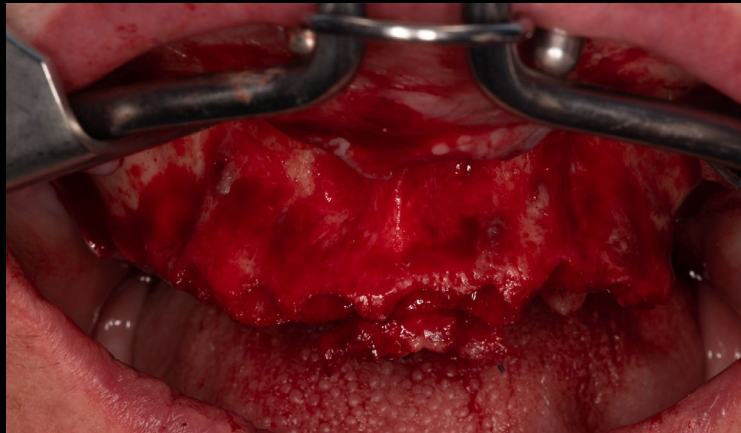
Initial clinical situation

Treatment planning

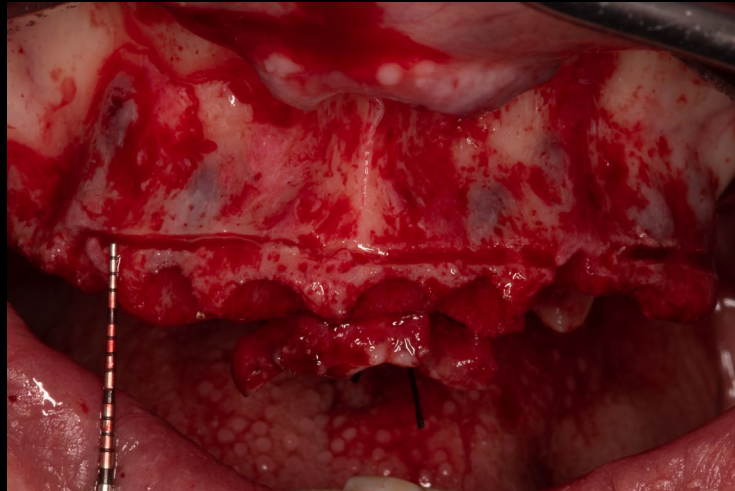
Surgical procedure

Restorative procedure

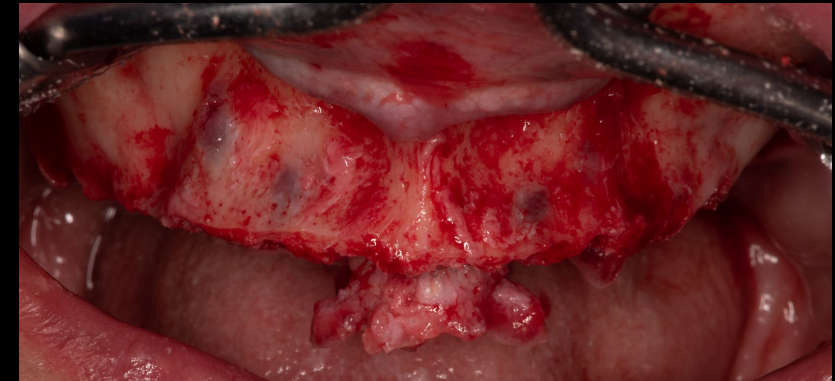Outcome



Flap raising and bone exposure



Ridge regularization taking into consideration the amount of bone reduction needed to correct gummy smile appearance



Final level of ridge regularization

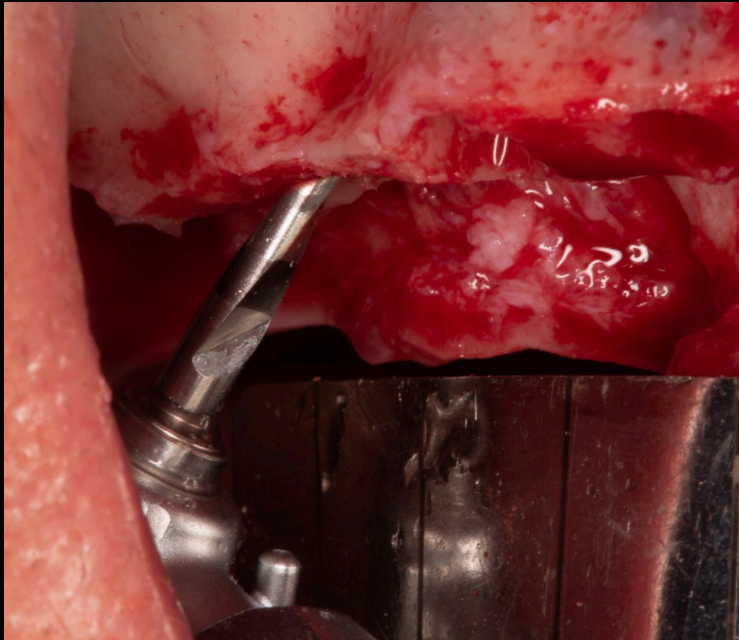
**Initial clinical
situation**

**Treatment
planning**

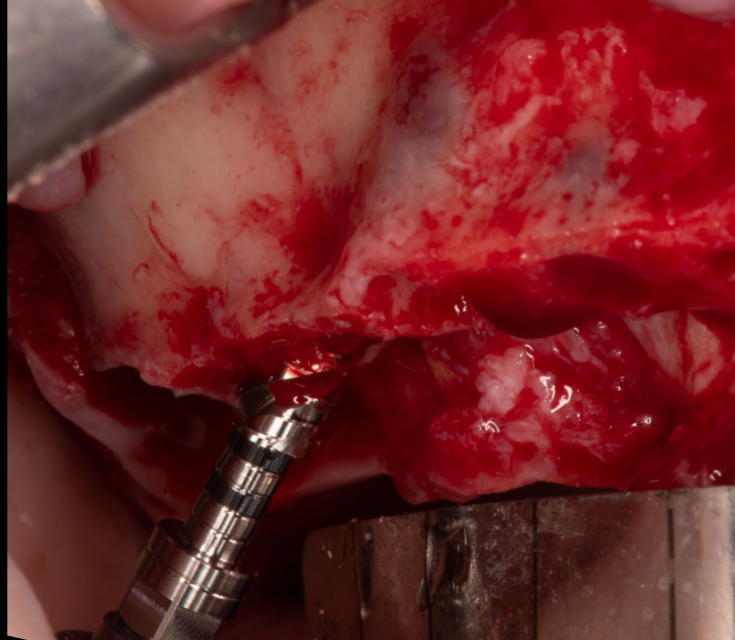
**Surgical
procedure**

**Restorative
procedure**

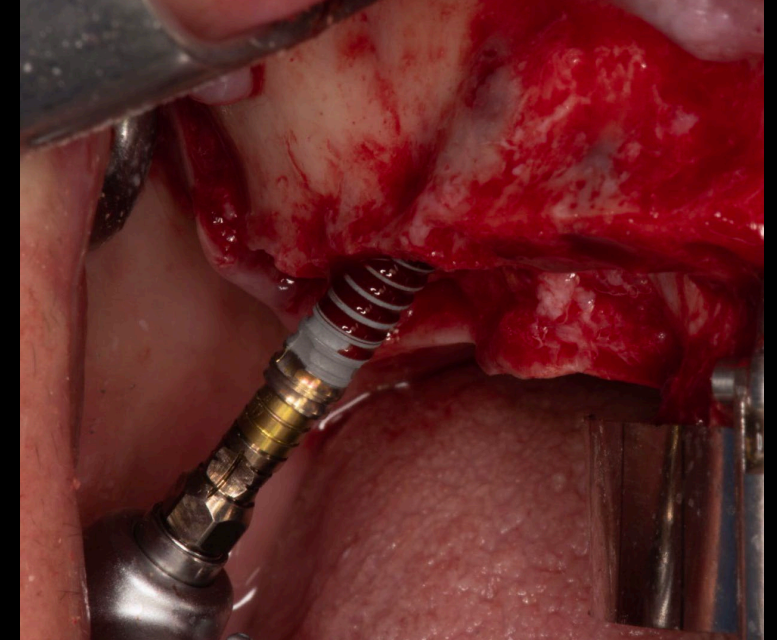
Outcome



Pilot osteotomy with OsseoDirector drill



Final osteotomy with OsseoShaper 1



Placement of Nobel Biocare N1 Implant

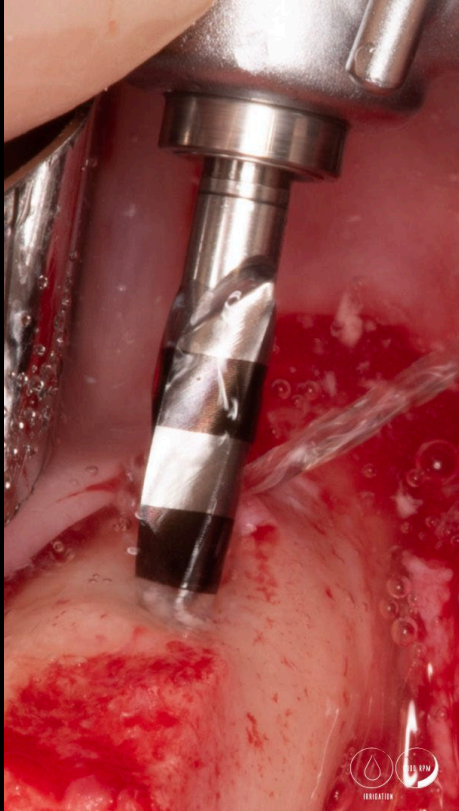Initial clinical situation

Treatment planning

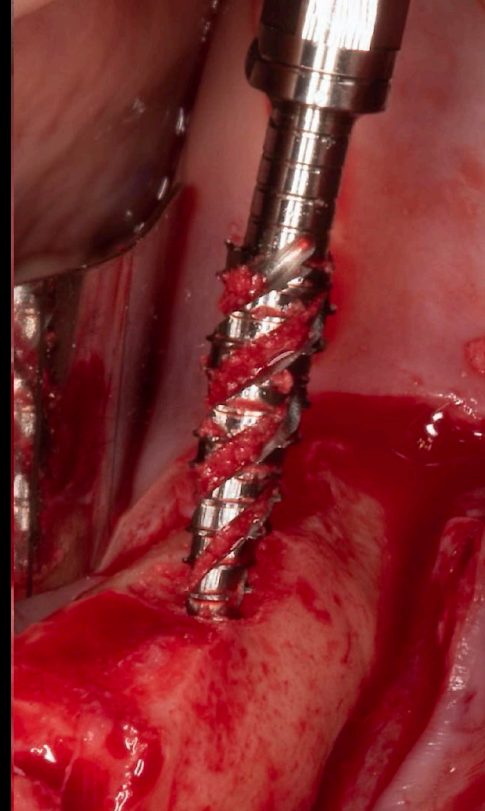
Surgical procedure

Restorative procedure

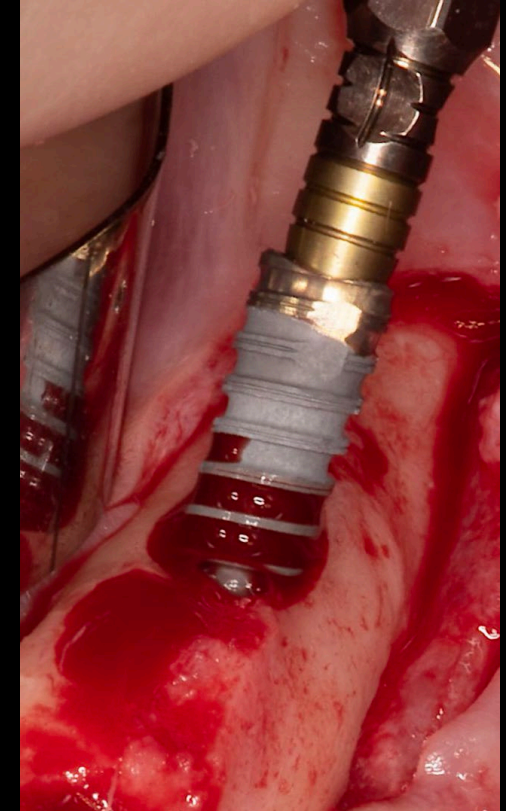
Outcome



Lower jaw surgical phases, OsseoDirector drill



Final osteotomy with OsseoShaper 1 instrument



Nobel Biocare N1 Implant placement

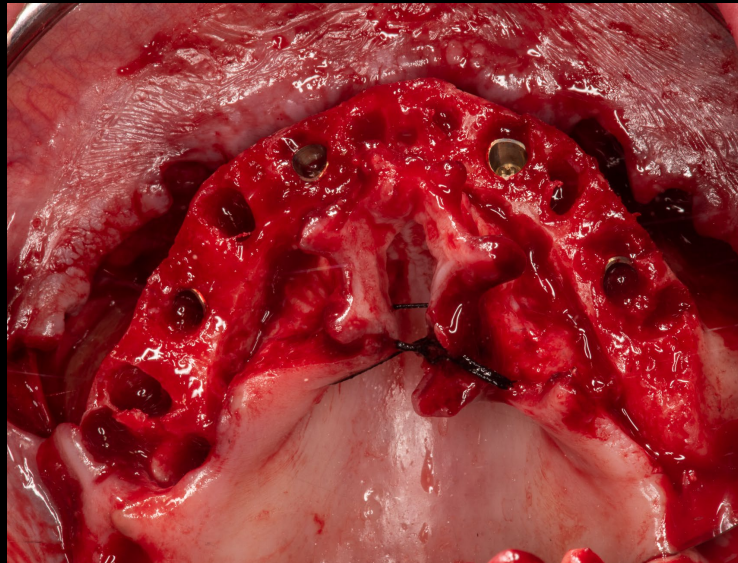
**Initial clinical
situation**

**Treatment
planning**

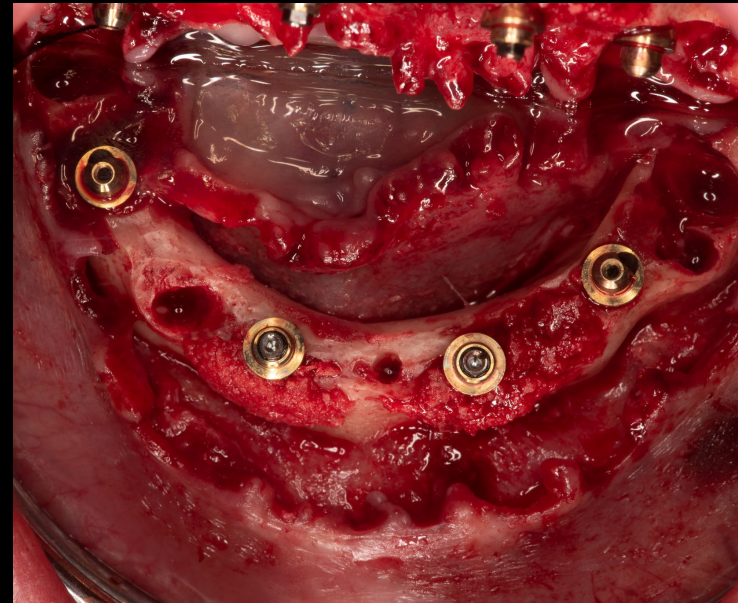
**Surgical
procedure**

**Restorative
procedure**

Outcome



Upper jaw: occlusal view after implant placement



**Lower jaw: occlusal view after implant and Multi-unit
Abutment Xeal placement**

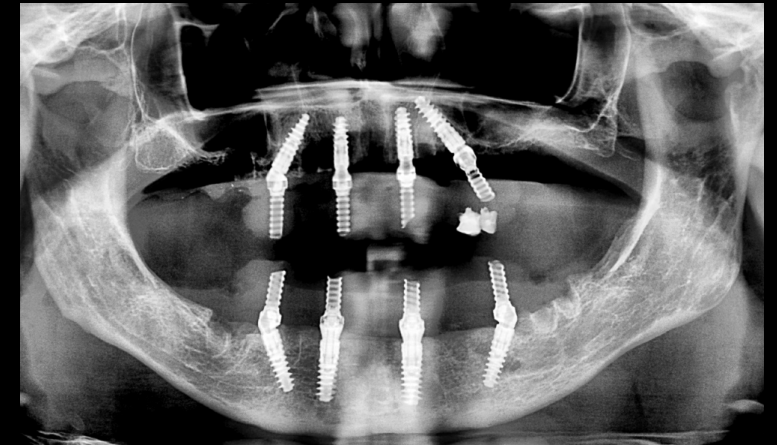
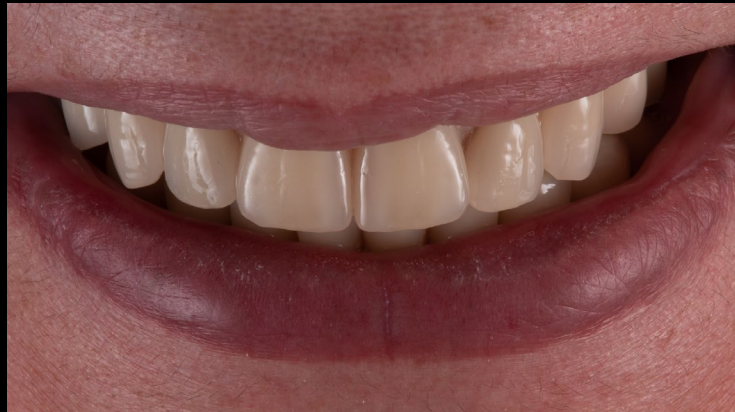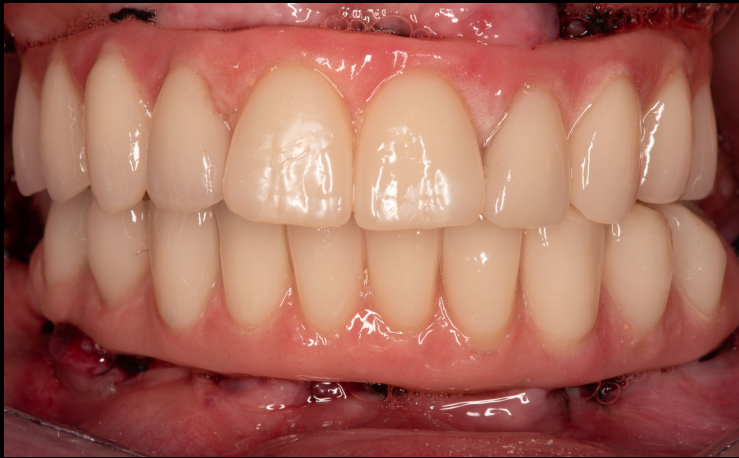Initial clinical situation

Treatment planning

Surgical procedure

Restorative procedure

Outcome



Provisional prosthesis delivered immediately after the surgery

Smile with provisional prosthesis

X-ray immediately after the surgery

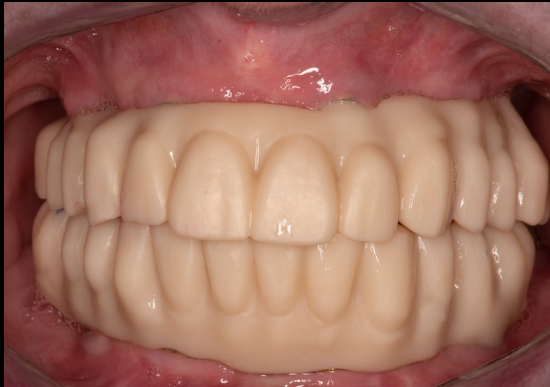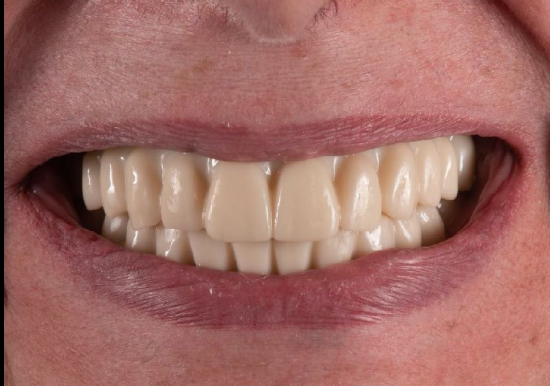Initial clinical situation

Treatment planning

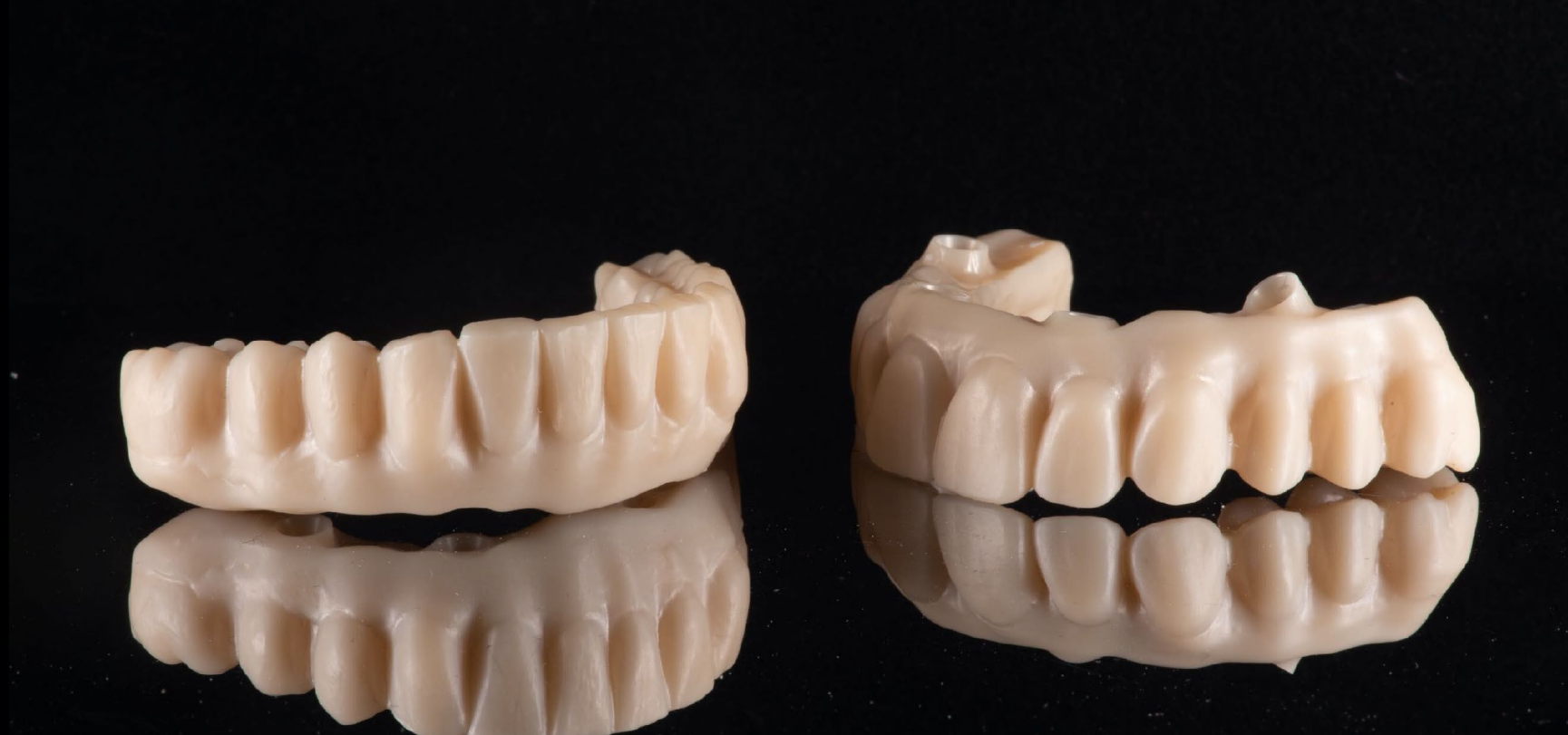Surgical procedure

Restorative procedure

Outcome



Try-in of monolithic zirconia structure



Nacera Pearl Shaded zirconia

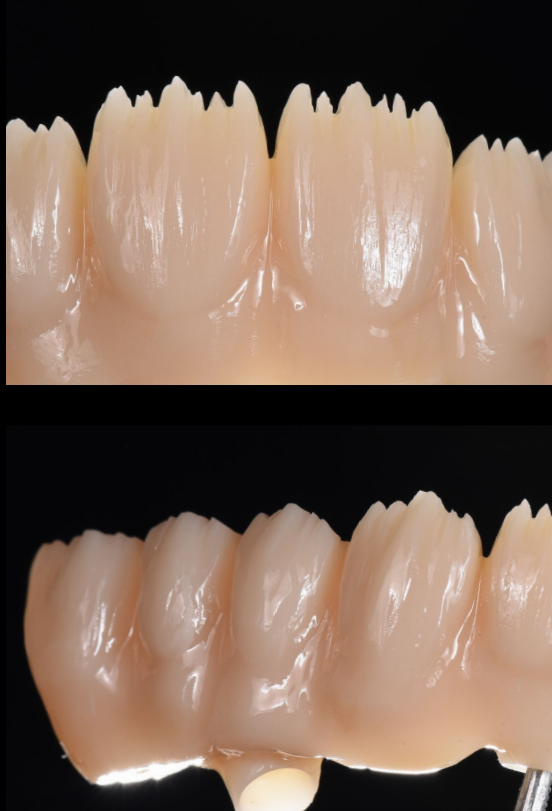Initial clinical situation

Treatment planning

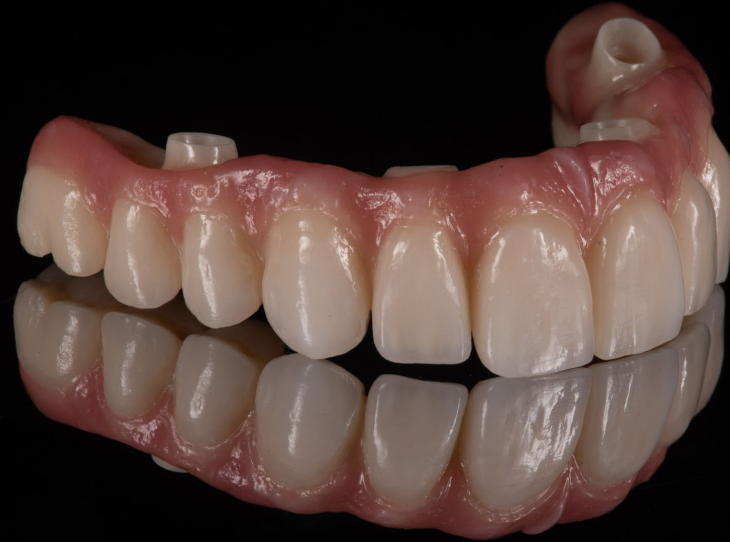Surgical procedure

Restorative procedure

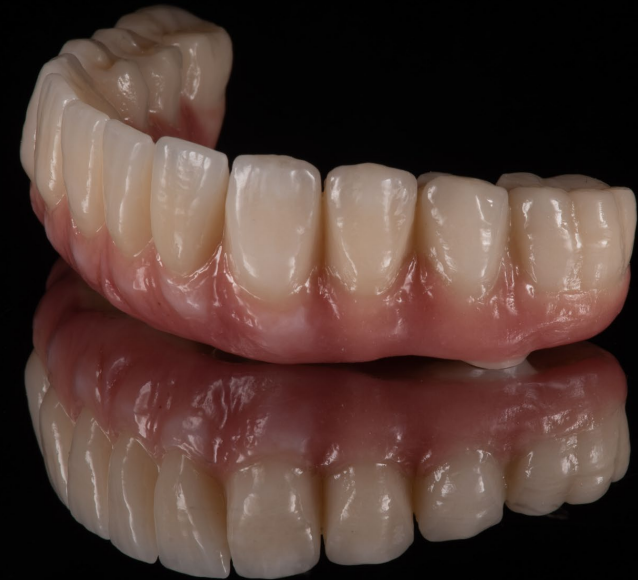Outcome



Cut back of the structure in order to perform a ceramic stratification to improve the esthetic result



Final rehabilitations ready to be delivered to the patient



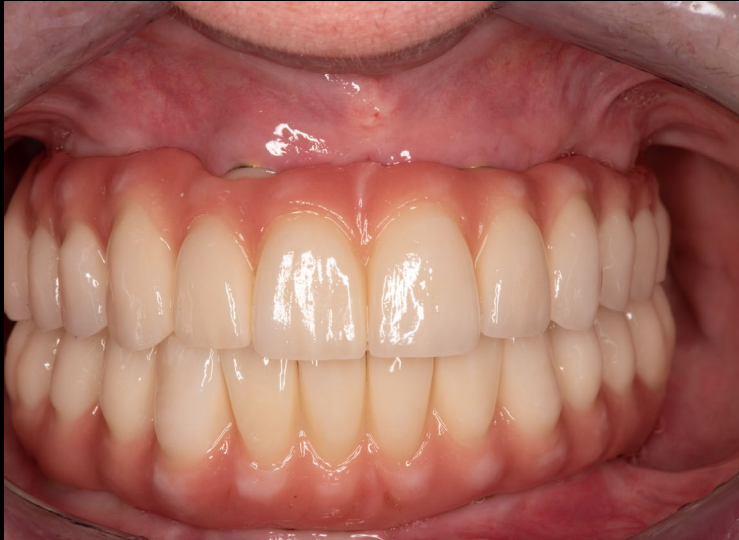Initial clinical situation

Treatment planning

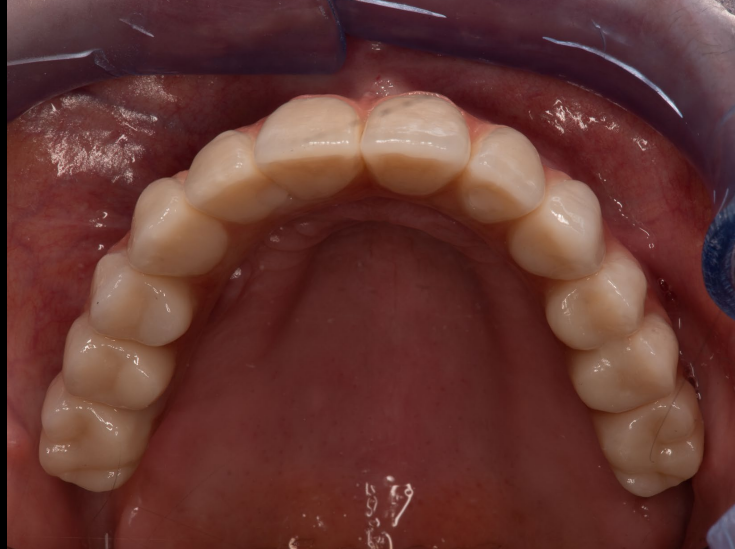
Surgical procedure

Restorative procedure

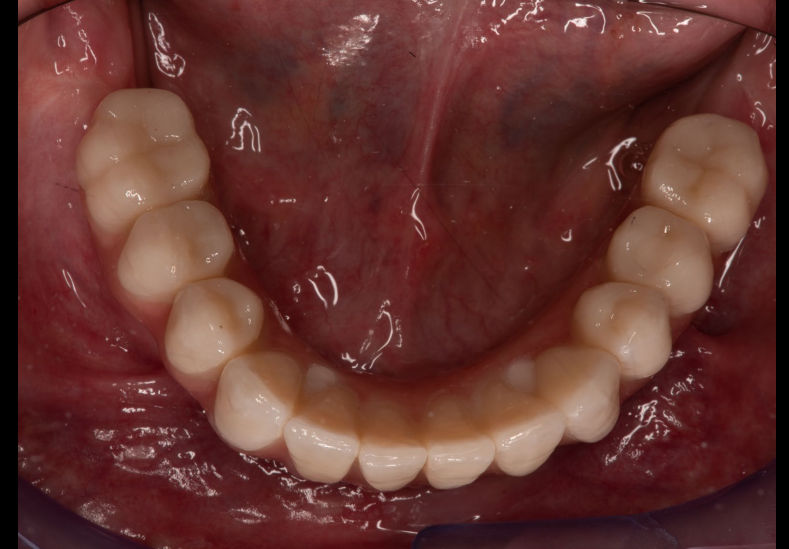Outcome



Final rehabilitation delivered to the patient 6 months after the surgery



Upper jaw occlusal view



Lower jaw occlusal view

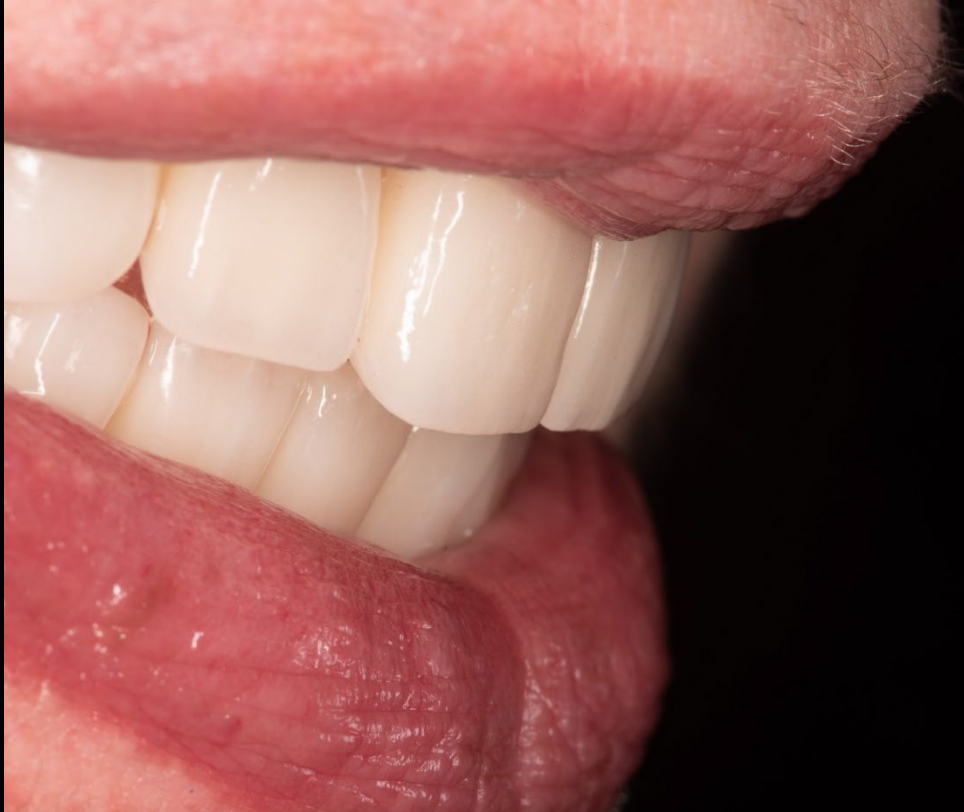Initial clinical situation

Treatment planning

Surgical procedure

Restorative procedure

Outcome



Final esthetic result



Smile of the patient with final rehabilitation

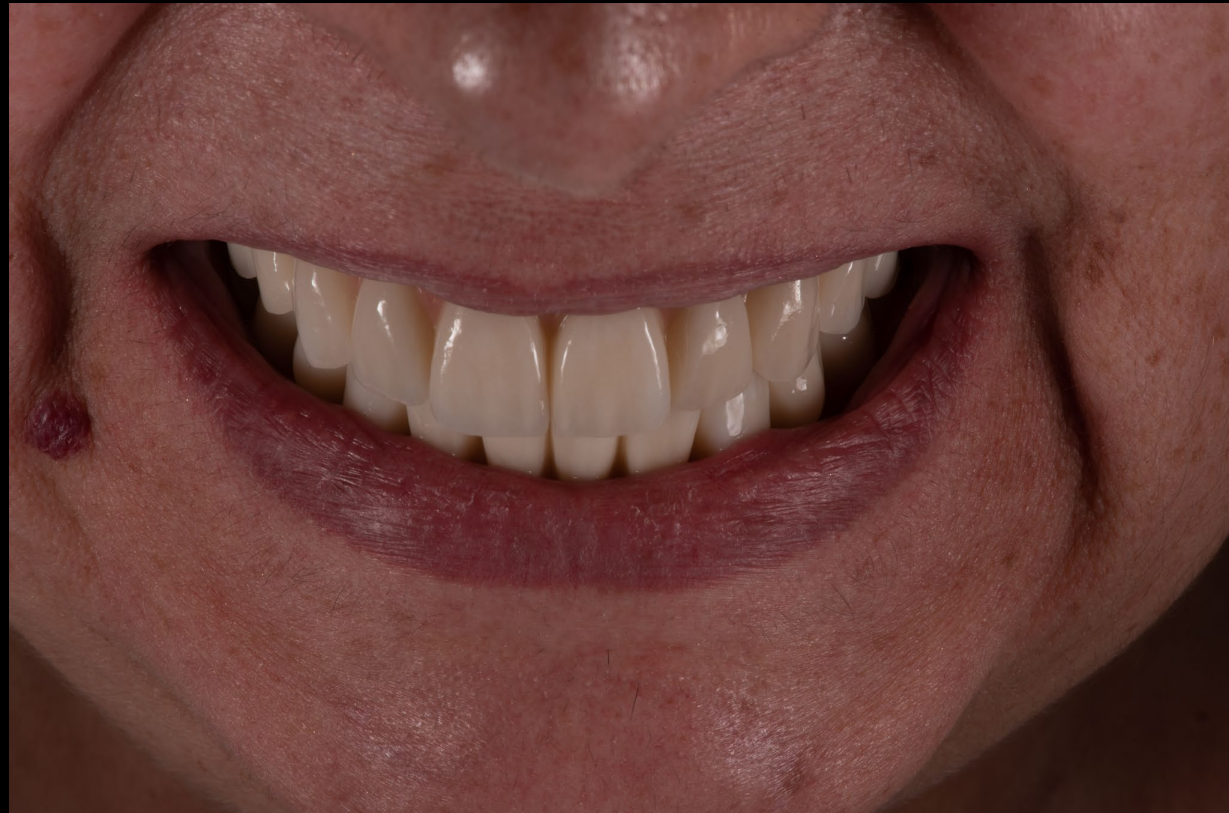
**Initial clinical
situation**

**Treatment
planning**

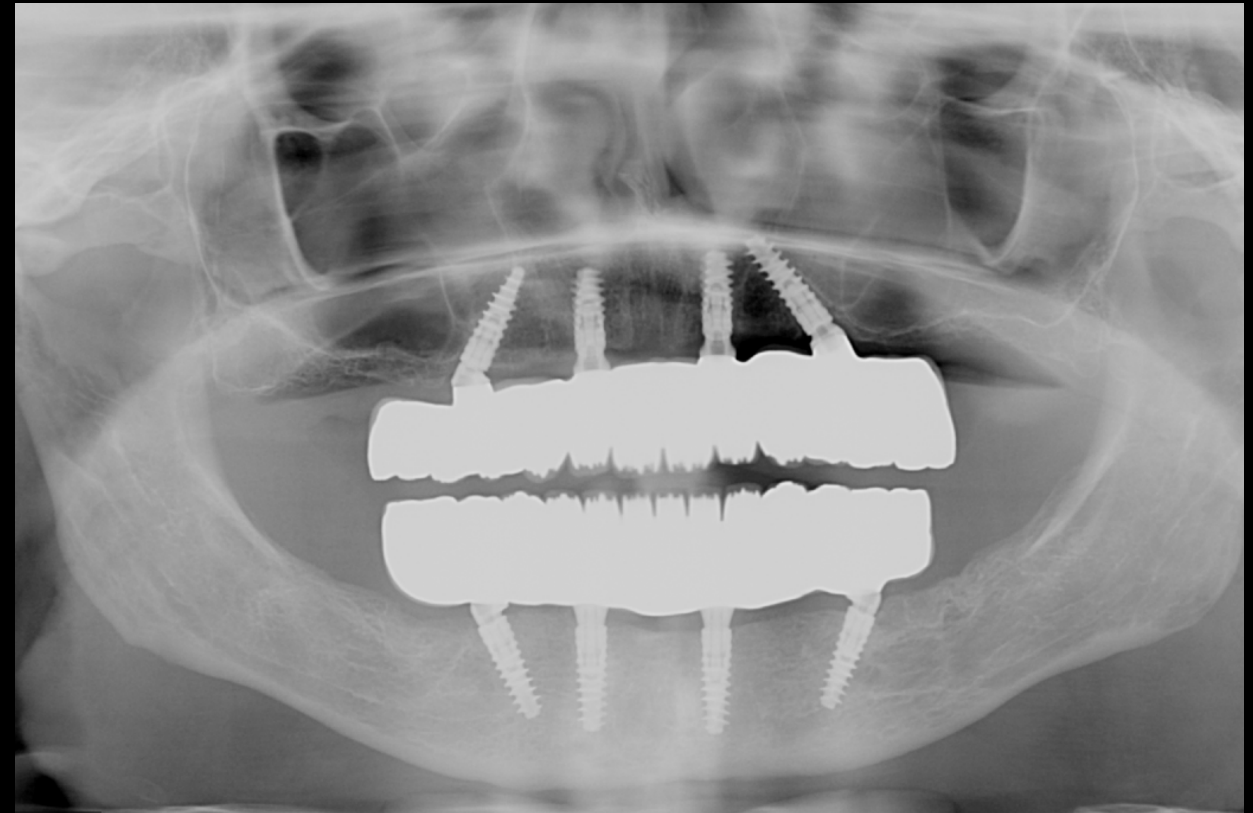
**Surgical
procedure**

**Restorative
procedure**

Outcome



Final smile result



X-ray with final rehabilitations 8 months after the surgery

Case courtesy of Prof. Enrico Agliardi



GMT81563 © Nobel Biocare Services AG, 2022. All rights reserved.

Disclaimer: Nobel Biocare, the Nobel Biocare logotype and all other trademarks are, if nothing else is stated or is evident from the context in a certain case, trademarks of Nobel Biocare. Please refer to nobelbiocare.com/trademarks for more information. Product images are not necessarily to scale. All product images are for illustration purposes only and may not be an exact representation of the product.

Some products may not be regulatory cleared/released for sale in all markets. Please contact the local Nobel Biocare sales office for current product assortment and availability. Caution: Federal (United States) law or the law in your jurisdiction may restrict this device to sale by or on the order of a dentist or a physician. See Instructions For Use for full prescribing information, including indications, contraindications, warnings and precautions.

Not all medical devices used during surgery are Nobel Biocare devices. Nobel Biocare recommends that manufacturer's IFUs are followed. Full procedure is not shown. Certain sequences have been cut. Please refer to applicable IFUs for full instructions.