

A complete posterior solution

Bringing
innovation
back

Lined up for efficiency

Large extraction sockets, limited accessibility, difficult removal of excess cement and high occlusal forces. Sound familiar?

Though a common indication, single-unit molar restorations pose many challenges. Overcome these difficulties with the complete posterior solution. It lets you shorten your patients' time-to-teeth while reducing complexity and risks. Explore multiple new innovations that not only stand out on their own, but stand even stronger together.

**Discover the complete posterior solution:
nobelbiocare.com/posteriorsolution**

Full contour in eight shades

The entire material is the same color throughout the crown. This means the crown will always maintain its shade – even when adjusted.



A completely cement-free implant crown

Eliminate the risk of excess cement^{7,8} with the NobelProcera screw-retained implant crown. Even the adapter is mechanically retained. Since the implant crown is CAD/CAM manufactured from monolithic zirconia, the risk of chipping is almost entirely eliminated.⁹ It combines remarkable strength and workflow efficiency.



Wide platform to build an optimized emergence profile


The wide platform option of 5.5 mm provides the solid base you need to create an optimized molar emergence profile for the temporary and final restoration.

Implants engineered for Immediate Function

Achieve immediate implant placement and Immediate Function with NobelActive or the new NobelParallel Conical Connection wide platform implants. The unique combination of implant design, proven TiUnite surface and surgical protocol help to ensure high primary stability and maintain it during the healing phase, even in soft bone situations.¹⁻⁶

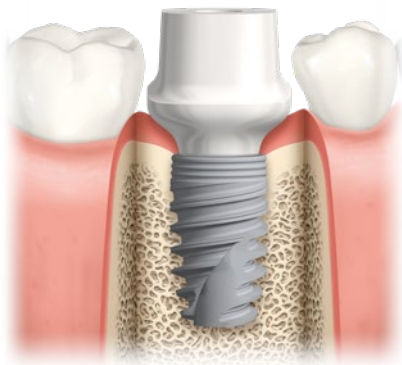
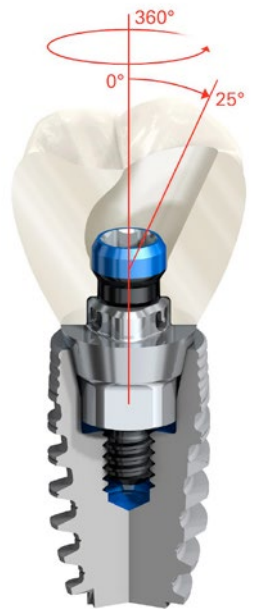Tooling with an incredible grip

Work efficiently and with more control using the Omnigrip Screwdriver. Its unique connection ensures incredible grip on the screw and a pick-up function that has to be tried to be believed.



Easy restorative access with the angulated screw channel (ASC)

Gain easy access to the restoration when vertical space is limited while enabling an optimized occlusal function. With the ASC you have the option to angulate the screw channel up to 25° in any direction. It provides more restorative flexibility independent of the implant position.



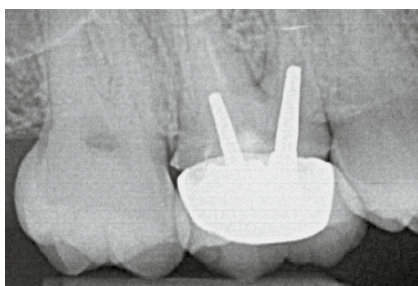
Temporary solution shaped by reality

Simplify treatment and reduce costly chair time with abutments designed specifically for the posterior. The PEEK healing and temporary abutments are anatomically shaped to match the contours of the molars. Fewer shape adjustments are needed, so you can achieve an optimized emergence profile in less time.

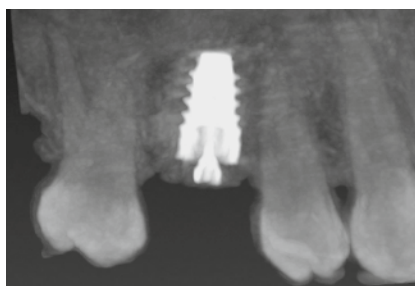Single tooth replacement in the posterior

"With Nobel Biocare's new wide-platform implants, the platform shifting effect is enhanced. Obtaining an optimized emergence profile that supports healthy soft tissue has never been more straightforward. Combining wide platform implants and the NobelProcera FCZ Implant Crown give us the level of precision we need in our daily practice."

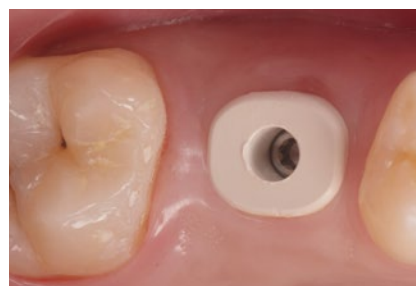
Dr. Léon Pariente, Paris, France



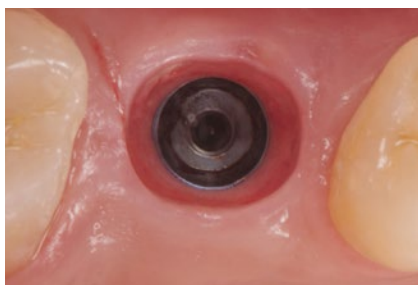
X-ray of cracked tooth syndrome on upper-right first molar. Tooth is extracted and site healed prior to implant placement.



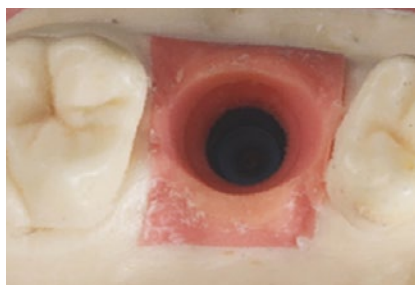
CT scan reconstruction in NobelClinician after implant placement (NobelActive 5.5 x 8.5 mm). Taken on day of surgery.



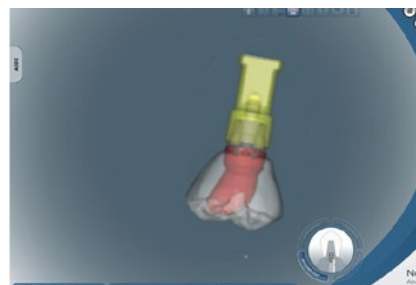Three months after implant placement. The soft tissue healing is outstanding with the use of PEEK Healing Abutment.



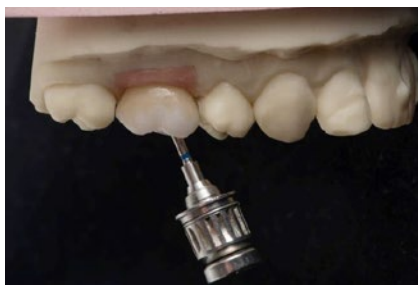After removal of the PEEK Healing Abutment the mucosal contour is healthy.



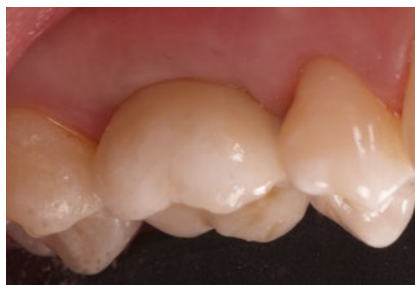The master cast is created and the soft tissue on cast is trimmed to create the ideal emergence profile.



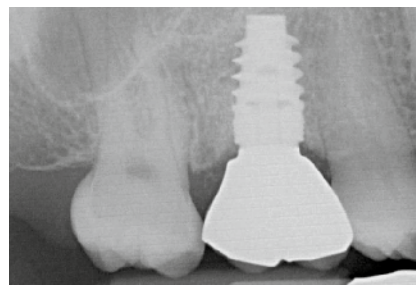
After scanning the wax-up (using the NobelProcera 2G Scanner), a molar crown is designed using the NobelProcera software.



Final NobelProcera FCZ (full-contour zirconia) Implant Crown is received. The angulated screw channel allows for easy access with the Omnigrip Screwdriver



Lateral view after crown placement shows proper support of the soft tissue.



Final X-ray on day of crown placement. X-ray confirms optimal fit of NobelProcera FCZ Implant Crown.

Studies with NobelActive implants:

- 1 Kolinski ML, Cherry JE, McAllister BS, Parrish KD, Pumphrey DW, Schroering RL. Evaluation of a variable-thread tapered implant in extraction sites with immediate temporization: A 3-year multi-center clinical study. *Journal of Periodontology*. 2013. [Epub ahead of print]
- 2 Arnhart C, Kielbassa AM, Martinez-de Fuentes R, Goldstein M, Jackowski J, Lorenzoni M, Maiorana C, Mericske-Stern R, Pozzi A, Rompen E, Sanz M, Strub JR. Comparison of variable-thread tapered implant designs to a standard tapered implant design after immediate loading. A 3-year multicenter randomised controlled trial. *Eur J Oral Implantol*. 2012 5:123-36
- 3 Babbush CA, Brokloff J. A Single-Center Retrospective Analysis of 1001 Consecutively Placed NobelActive Implants. *Implant Dent*. 2012 Feb;21:28-35

Studies with NobelSpeedy implants:

(NobelParallel CC implant body and apex design characteristics):

- 4 Villa R. Immediate loading of single NobelSpeedy™ Groovy implants placed in first molar post-extraction sockets: a 1-year clinical and radiological prospective study [# P148]. 25th Anniversary Annual Meeting of the Academy of Osseointegration. Orlando, USA; 2010.
- 5 Tallarico M, Vaccarella A, Marzi GC, Alviani A, Campana V. A prospective case-control clinical trial comparing 1- and 2-stage nobel biocare tiunite implants: resonance frequency analysis assessed by osstell mentor during integration. *Quintessence Int*. 2011;42(8):635-44
- 6 Agliardi EL, Pozzi A, Stappert CF, Benzi R, Romeo D, Gherlone E. Immediate Fixed Rehabilitation of the Edentulous Maxilla: A Prospective Clinical and Radiological Study after 3 Years of Loading. *Clin Implant Dent Relat Res*. epub ahead 2012.

Studies on excess cement and full contour crowns:

- 7 Wilson TG Jr. The positive relationship between excess cement and peri-implant disease: a prospective clinical endoscopic study. *J Periodontol*. 2009 Sep;80(9):1388-92. doi: 10.1902/jop.2009.090115.
- 8 Slagter KW, den Hartog L, Bakker NA, Vissink A, Meijer HJ, Raghoobar GM. Immediate placement of dental implants in the esthetic zone: a systematic review and pooled analysis. *J Periodontol*. 2014 Jul;85(7):e241-50. doi: 10.1902/jop.2014.130632.
- 9 Zhang Y1, Lee JJ, Srikanth R, Lawn BR. Edge chipping and flexural resistance of monolithic ceramics. *Dent Mater*. 2013 Dec;29(12):1201-8. doi: 10.1016/j.dental.2013.09.004.

nobelbiocare.com

