

**11-year after  
simultaneous sinus lift  
and implant placement:  
implant success and  
stable regenerated bone  
with creos™ xenoform**

Dr. Lee, Myung Ho, D.D.S., Republic of Korea





**Dr. Lee, Myung Ho,  
D.D.S.**

- Myungin Dental Line director
- Ti-oss Bone World Clinical Research Center
- Jeonju Myung Dental Clinic Representative Director
- Ph.D. in Dental Science
- Ph.D. in Business Administration
- Ph.D. in Philosophy

### Patient

63 years old, male with no systemic disease

### Clinical situation/Diagnosis

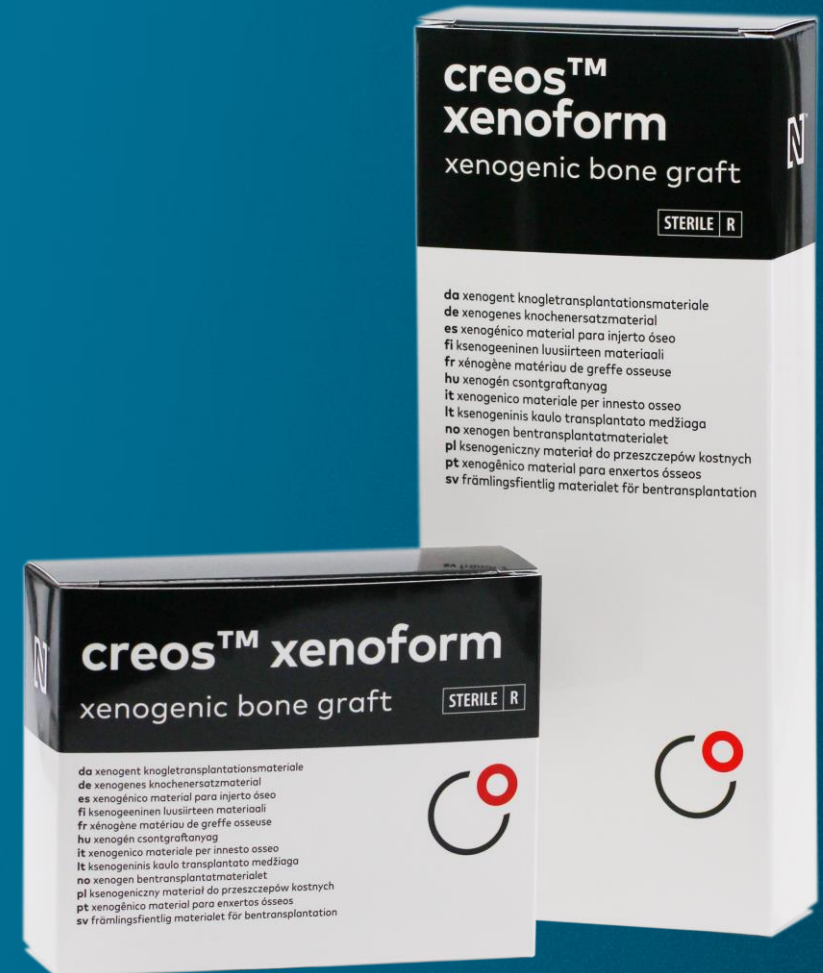Tooth (FDI 27) was previously removed, sinus augmentation and implant procedure chosen

### Surgery

Sinus augmentation with crestal approach and simultaneous implant placement  
Final metal ceramic fixed implant restoration after provisional loading

### Surgery date

July 2011





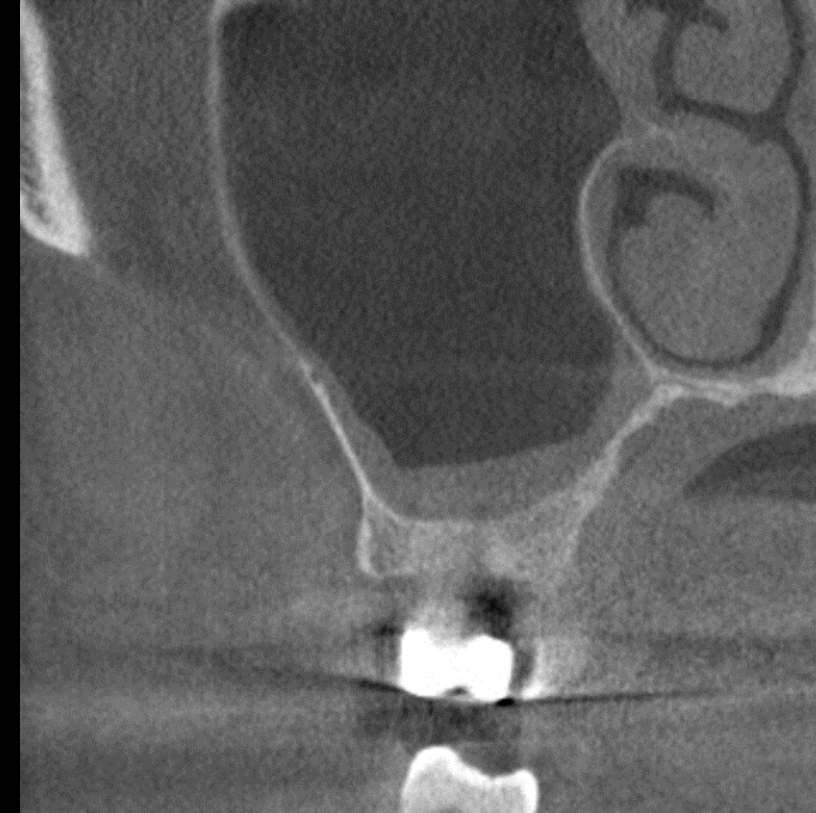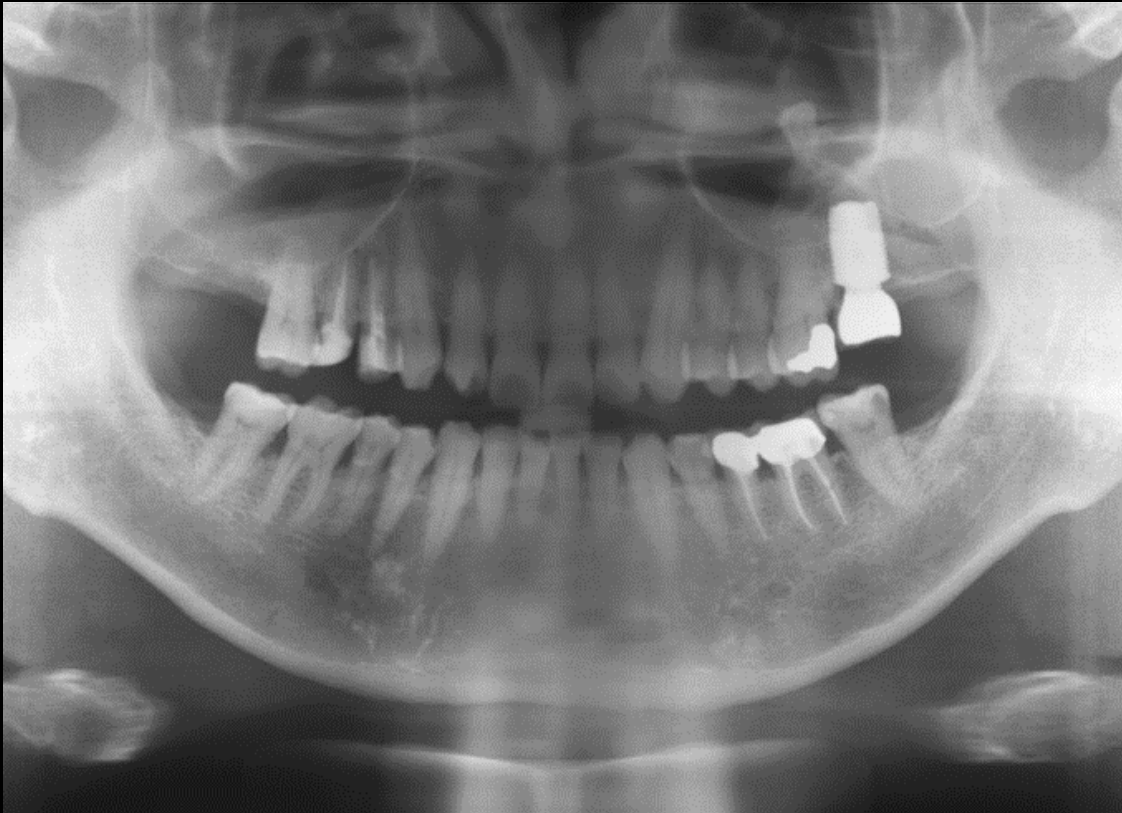**Initial clinical  
situation**

**Surgical  
procedure**

**Restorative  
procedure**

**Outcome**

**Pre-surgical evaluation**



5 - 8mm sinus augmentation necessary to provide enough bone height on the right second molar

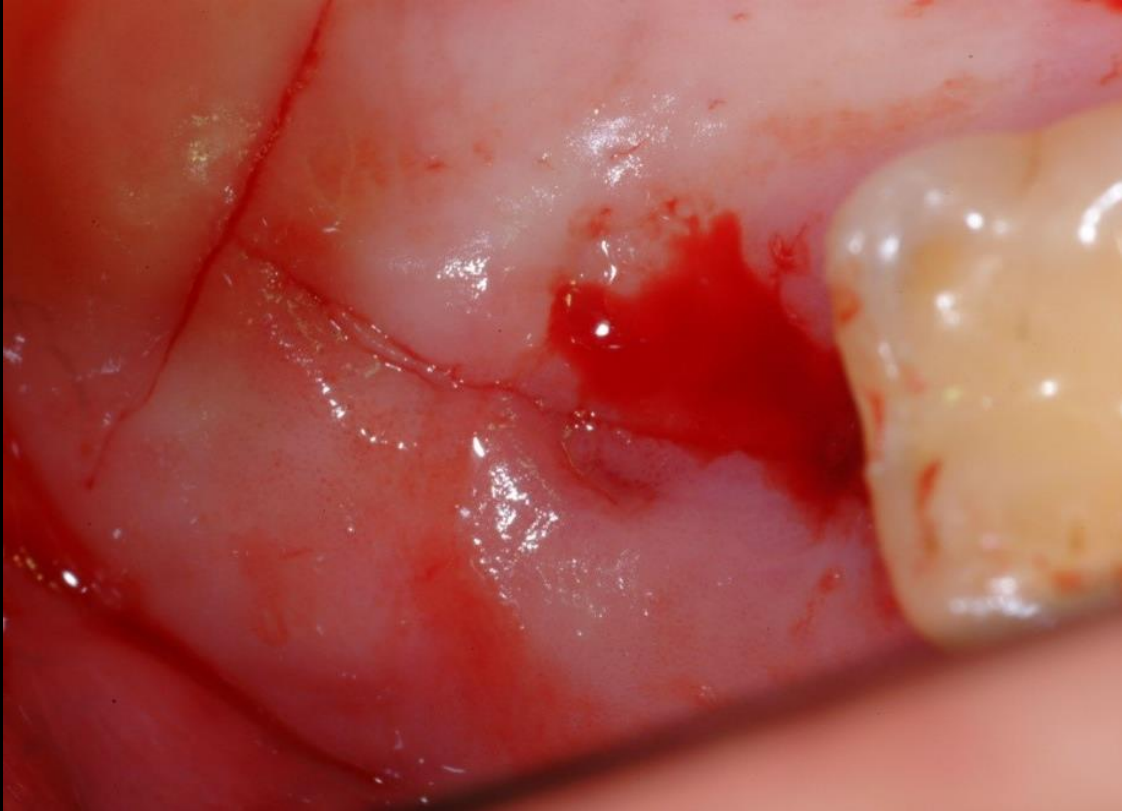**Initial clinical  
situation**

**Surgical  
procedure**

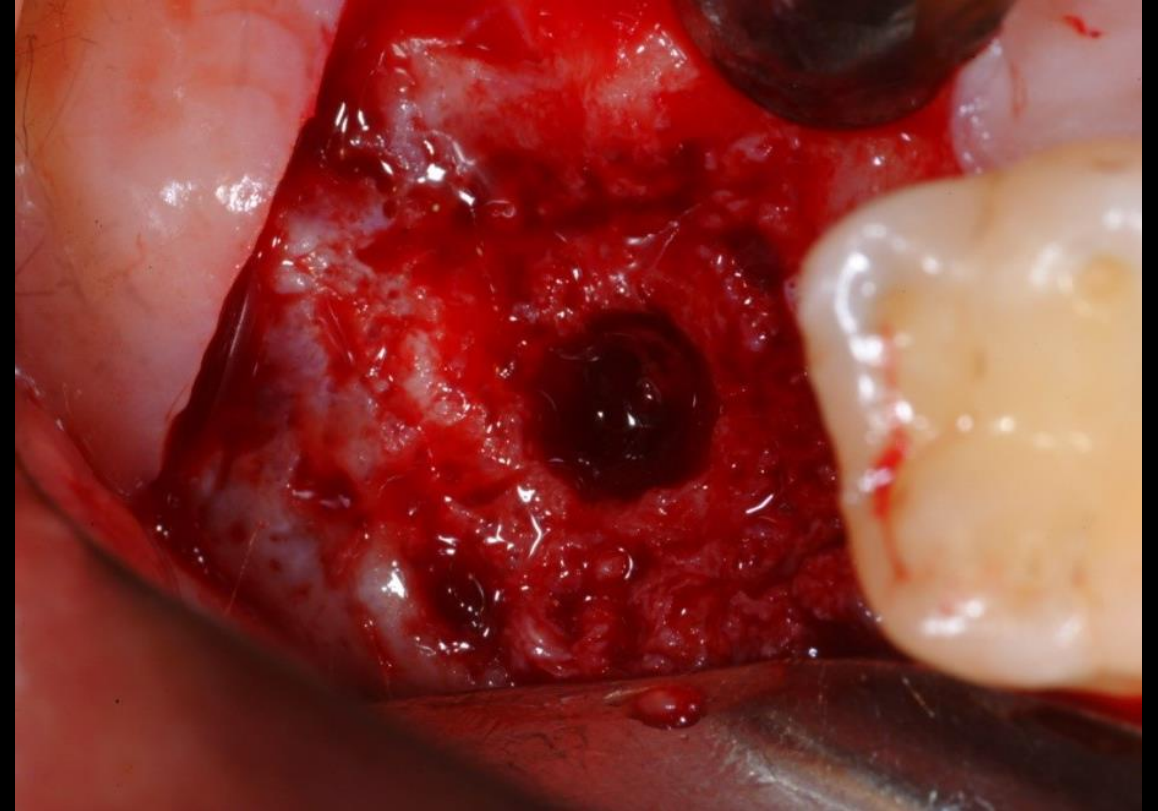
**Restorative  
procedure**

**Outcome**

**Initial approach**



**Clinical evaluation**



**Flap opened and crestal access to the sinus gained**



**Initial clinical  
situation**

**Surgical  
procedure**

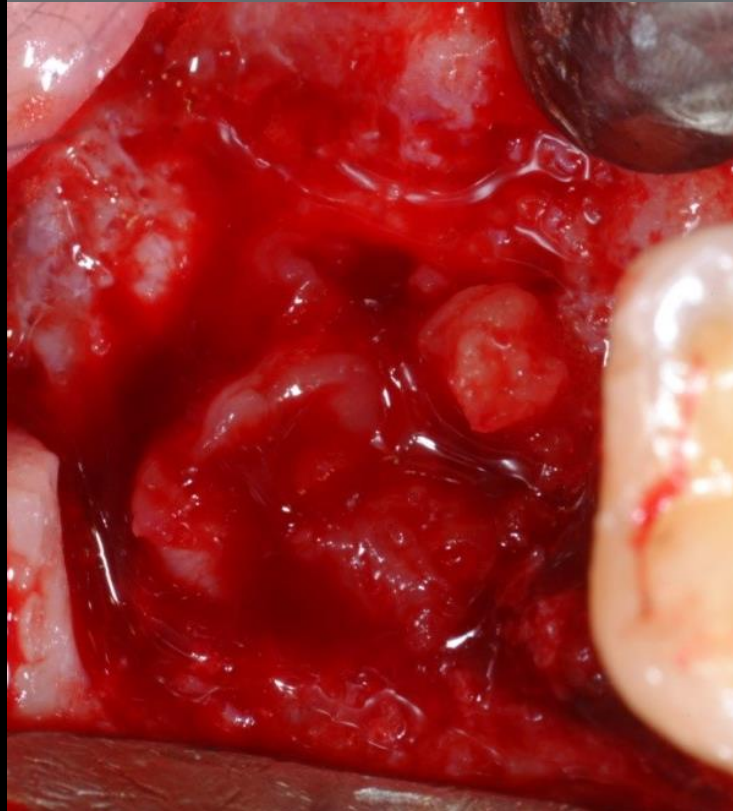**Restorative  
procedure**

**Outcome**

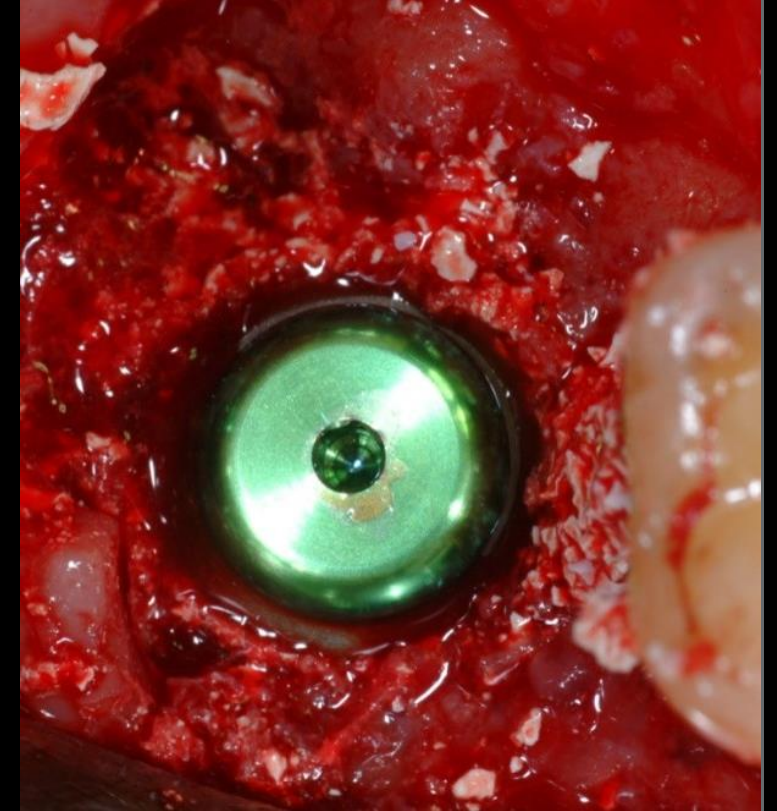
## Grafting and implant positioning



creos™ xenoform mixed with PRP



Preparation of the site for grafting



Implant placement

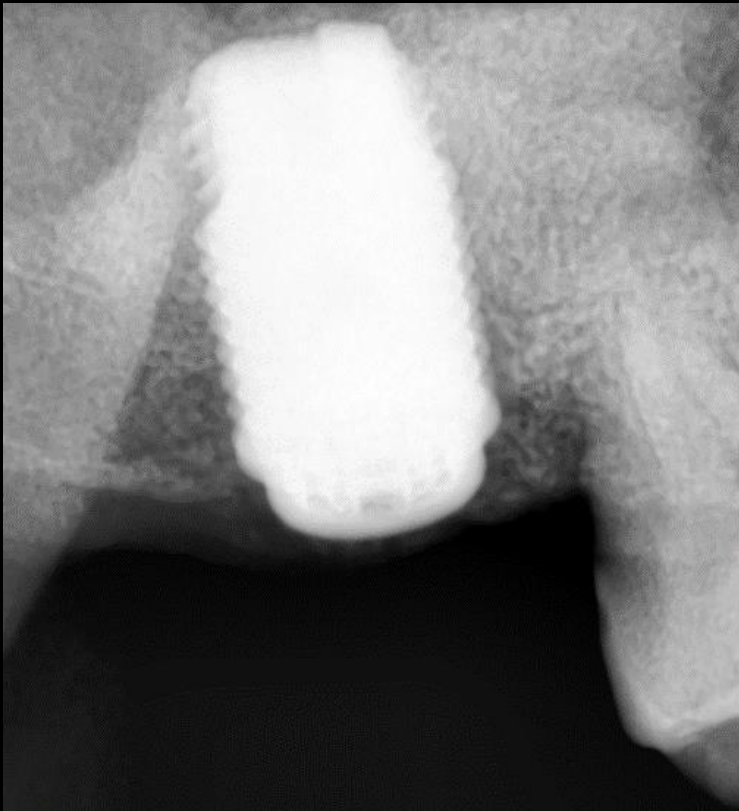
**Initial clinical  
situation**

**Surgical  
procedure**

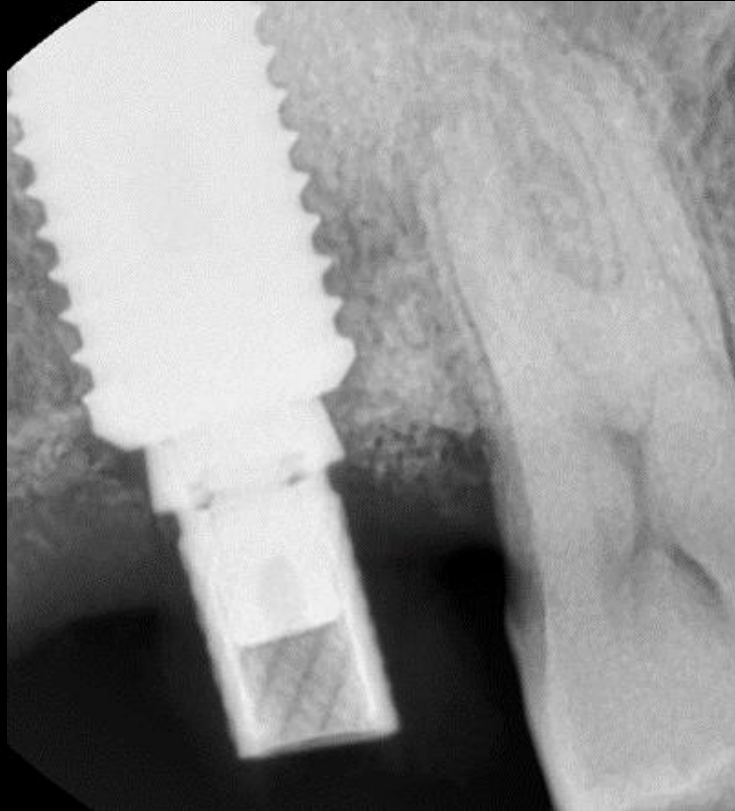
**Restorative  
procedure**

**Outcome**

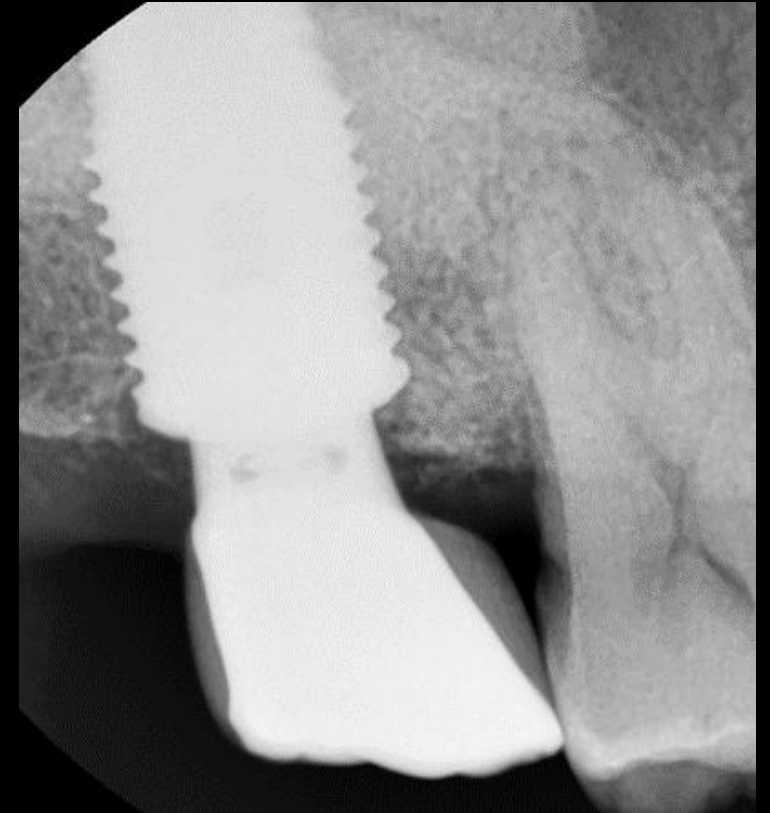
**Temporary and final prosthesis**



**1 month follow-up**



**7 months follow-up**



**Final restoration**



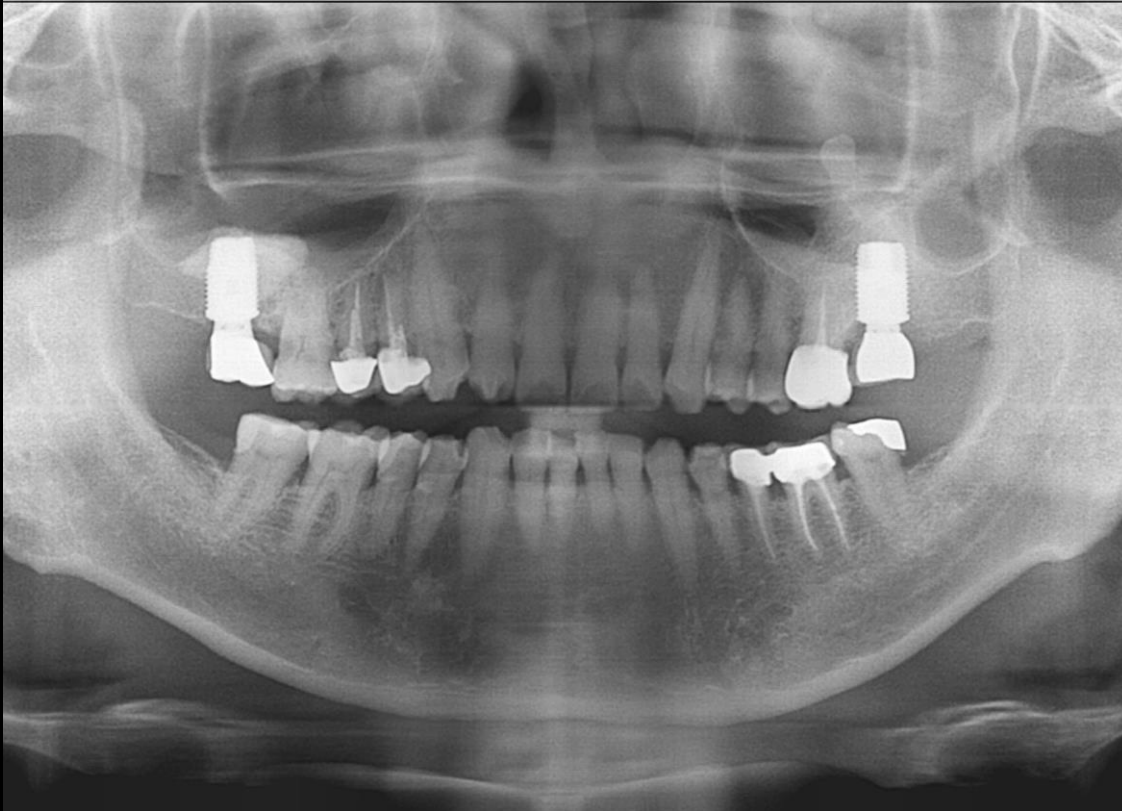**Initial clinical  
situation**

**Surgical  
procedure**

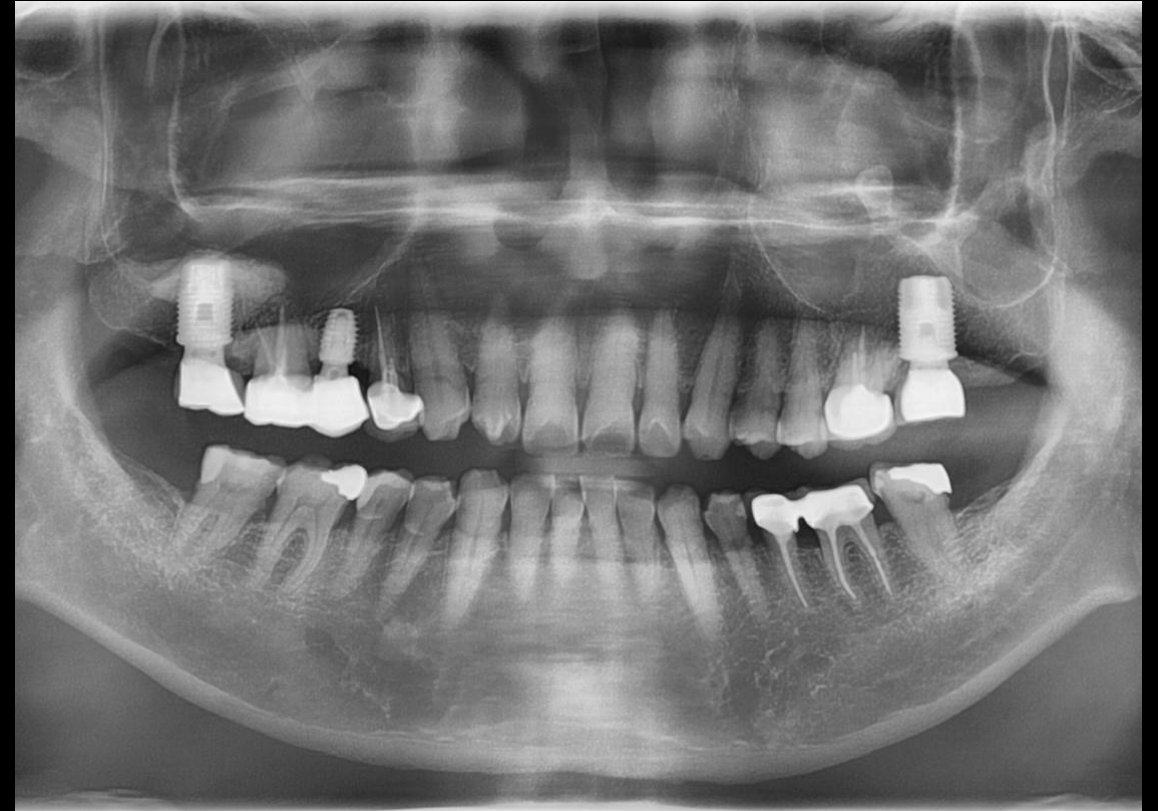**Restorative  
procedure**

**Outcome**

**Long-term results**



4.5 years follow-up panoramic x-ray



11 years follow-up panoramic x-ray

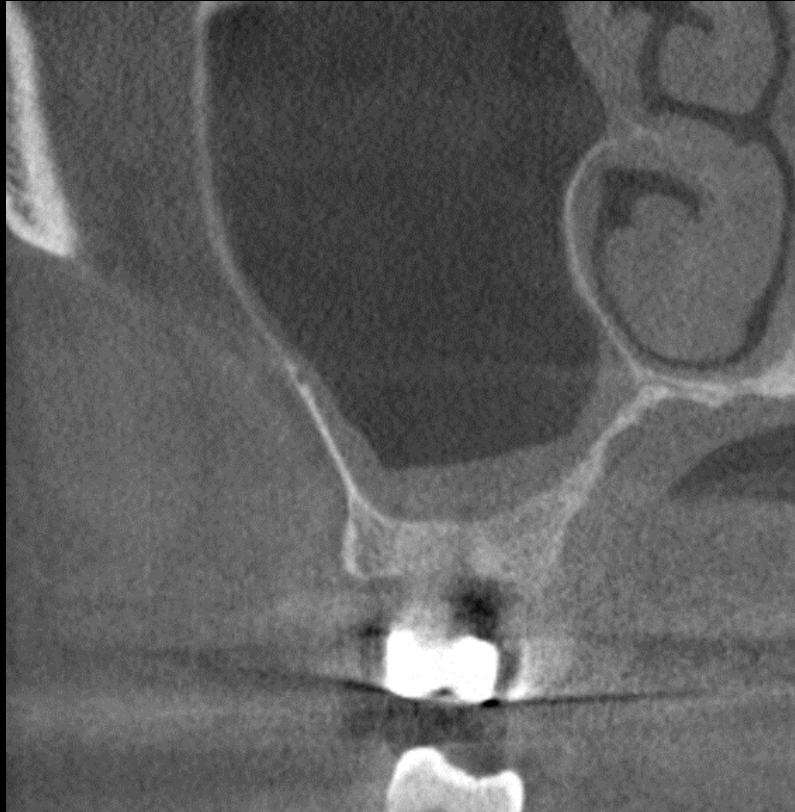**Initial clinical  
situation**

**Surgical  
procedure**

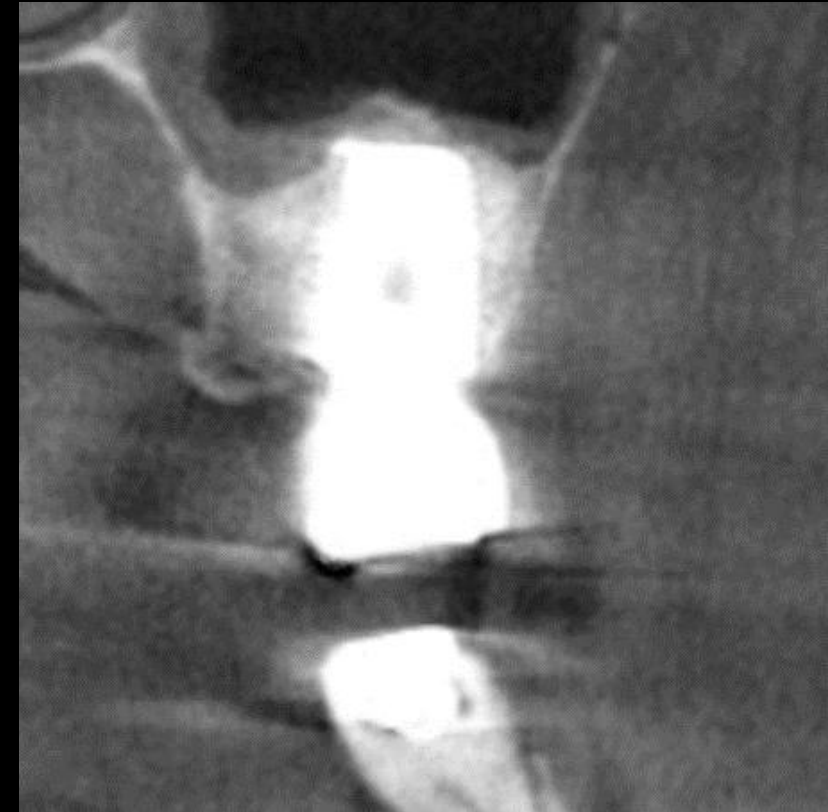
**Restorative  
procedure**

**Outcome**

**Before and after**



**Pre-surgical CT-slice**



**CT-slice with final prosthesis**



**Initial clinical  
situation**

**Surgical  
procedure**

**Restorative  
procedure**

**Outcome**

## Before and After



Pre-surgical panoramic x-ray



11 years follow-up panoramic x-ray

**Case courtesy of Lee, Myung Ho, D.D.S.**



GMT 83546 GB 2302 © Nobel Biocare Services AG, 2023. . All rights reserved. Distributed by: Nobel Biocare. Nobel Biocare, the Nobel Biocare logotype and all other trademarks are, if nothing else is stated or is evident from the context in a certain case, trademarks of Nobel Biocare. Please refer to [nobelbiocare.com/trademarks](https://nobelbiocare.com/trademarks) for more information. Product images are not necessarily to scale. All product images are for illustration purposes only and may not be an exact representation of the product. Please contact the local Nobel Biocare sales office for current product assortment and availability. Disclaimer: For prescription use only. Caution: Federal (United States) law or the law in your jurisdiction may restrict this device to sale by or on the order of a licensed clinician, medical professional or physician. See Instructions For Use for full prescribing information, including indications, contraindications, warnings and precautions. Ti-oss® (Chiyewon Co., Ltd.) is distributed as creos™ xenoform since January 2023. Legal Manufacturer: Chiyewon Co., Ltd. 6F, 192 Gyeongchunro, Guri si, Gyeonggido, Korea 11927.

Nobel Biocare does not take any liability for any injury or damage to any person or property arising from the use of this clinical case. This clinical case is not intended to recommend any measures, techniques, procedures or products, or give advice, and is not a substitute for medical training or your own clinical judgement as a healthcare professional. Viewers should never disregard professional medical advice or delay seeking medical treatment because of something they have seen in this clinical case. Full procedure is not shown. Certain sequences have been cut.