

Extraction Defect Left Maxillary, First Molar, Immediate Placement, One Stage

Dr. Lee, Myung Ho, D.D.S., Republic of Korea





**Dr. Lee, Myung Ho,
D.D.S.**

- Myungin Dental Line director
- Ti-oss Bone World Clinical Research Center
- Jeonju Myung Dental Clinic Representative Director
- Ph.D. in Dental Science
- Ph.D. in Business Administration
- Ph.D. in Philosophy

Patient

58 years old, female with no systemic disease

Clinical situation/Diagnosis

Tooth removal (FDI 26) and simultaneous implant placement

Surgery

Implant placement and graft placement with creos™ xenoform simultaneously in one stage approach

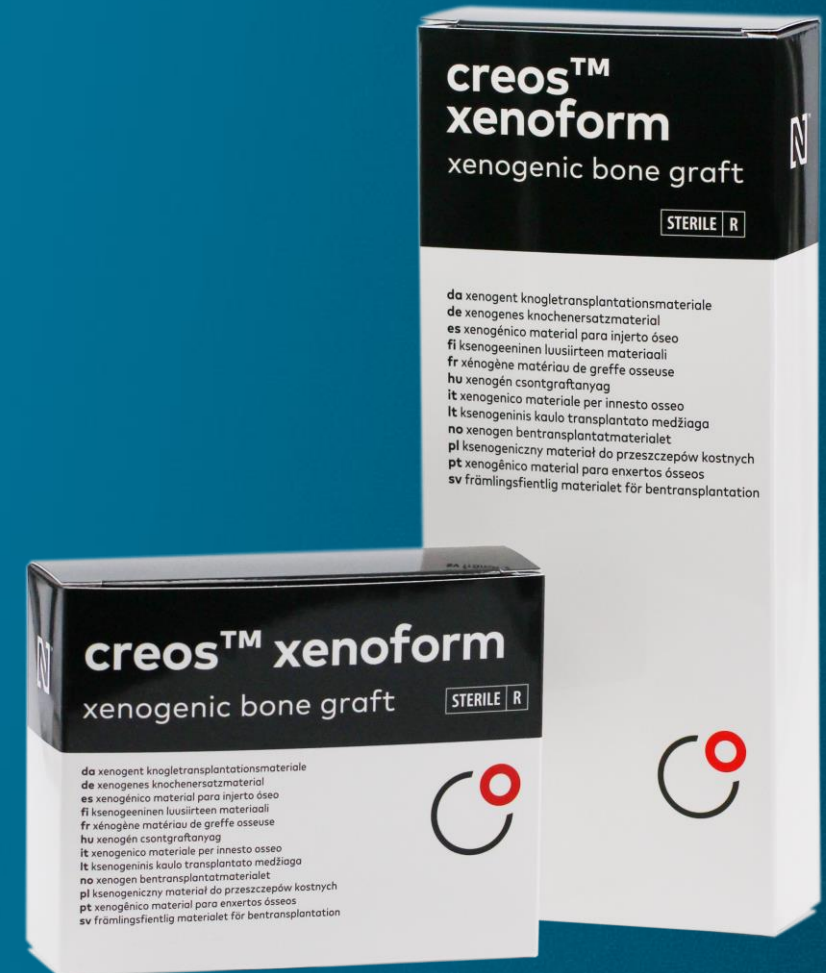Final metal ceramic fixed implant restoration after provisional loading

Surgery date

June 2011

Total treatment time

3 months



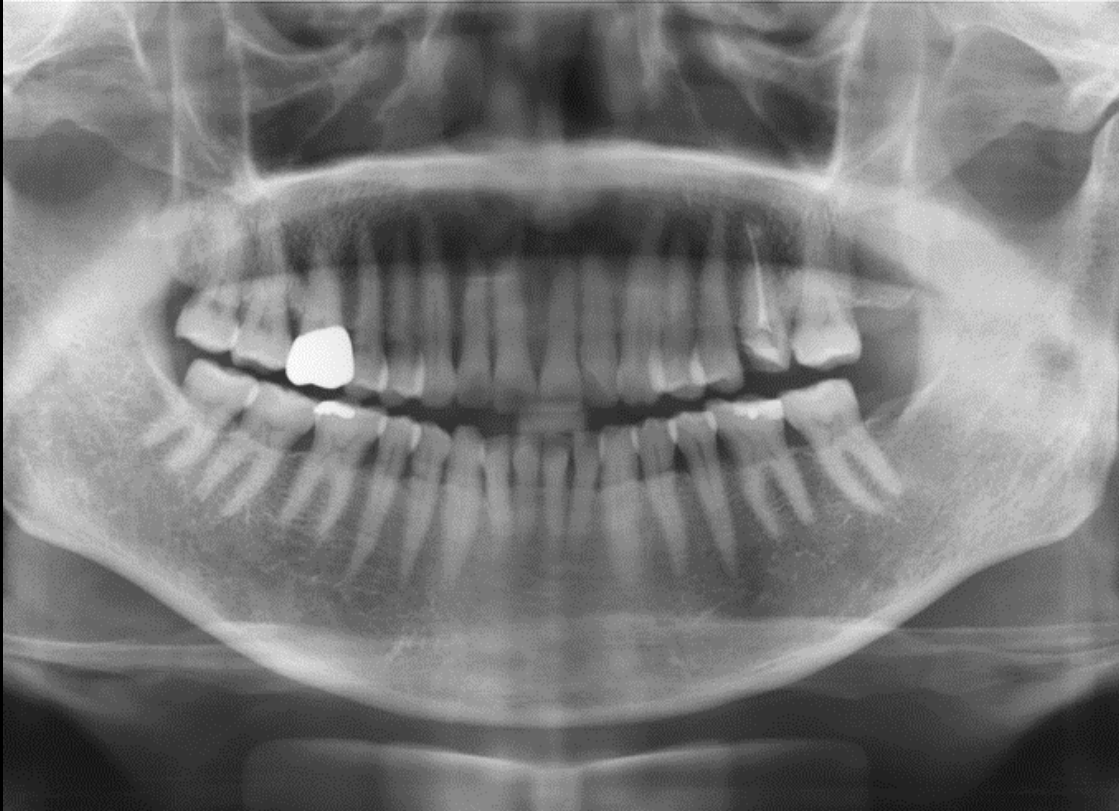**Initial clinical
situation**

**Surgical
procedure**

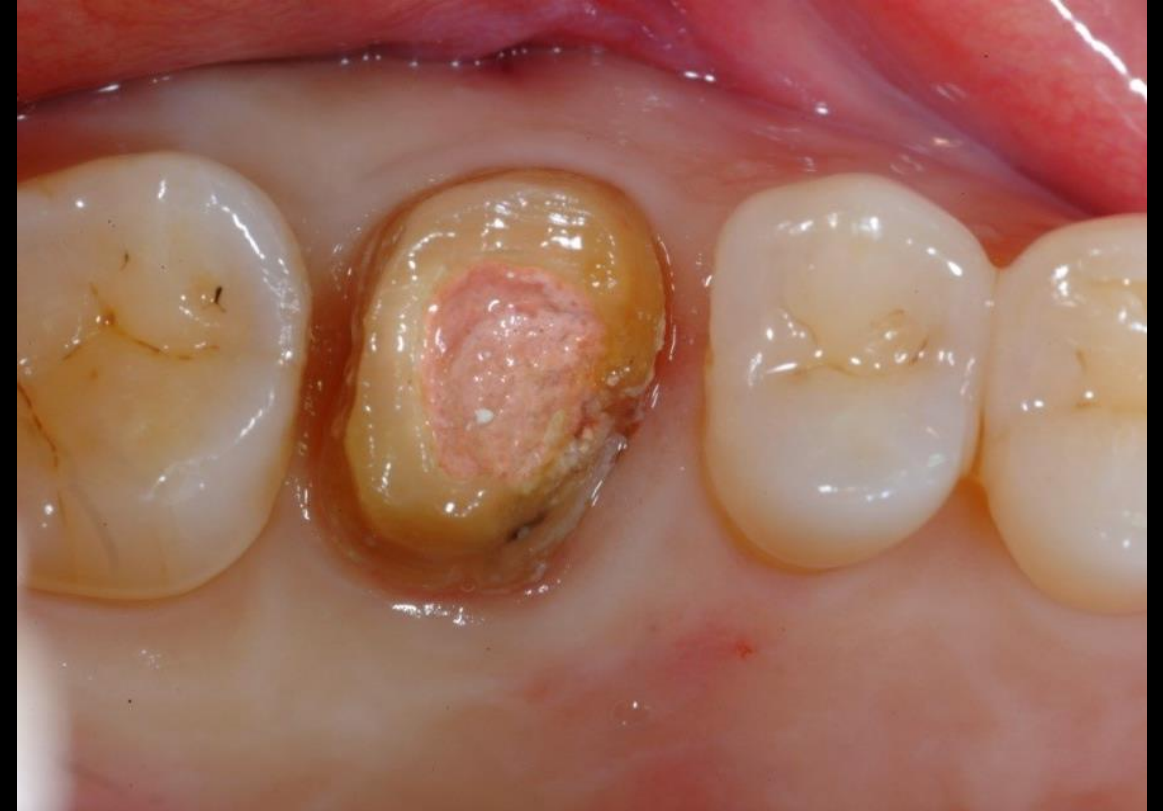**Restorative
procedure**

Outcome

Pre-surgical evaluation



Maxillary left first molar shows endodontically treated tooth



Septal area well preserved

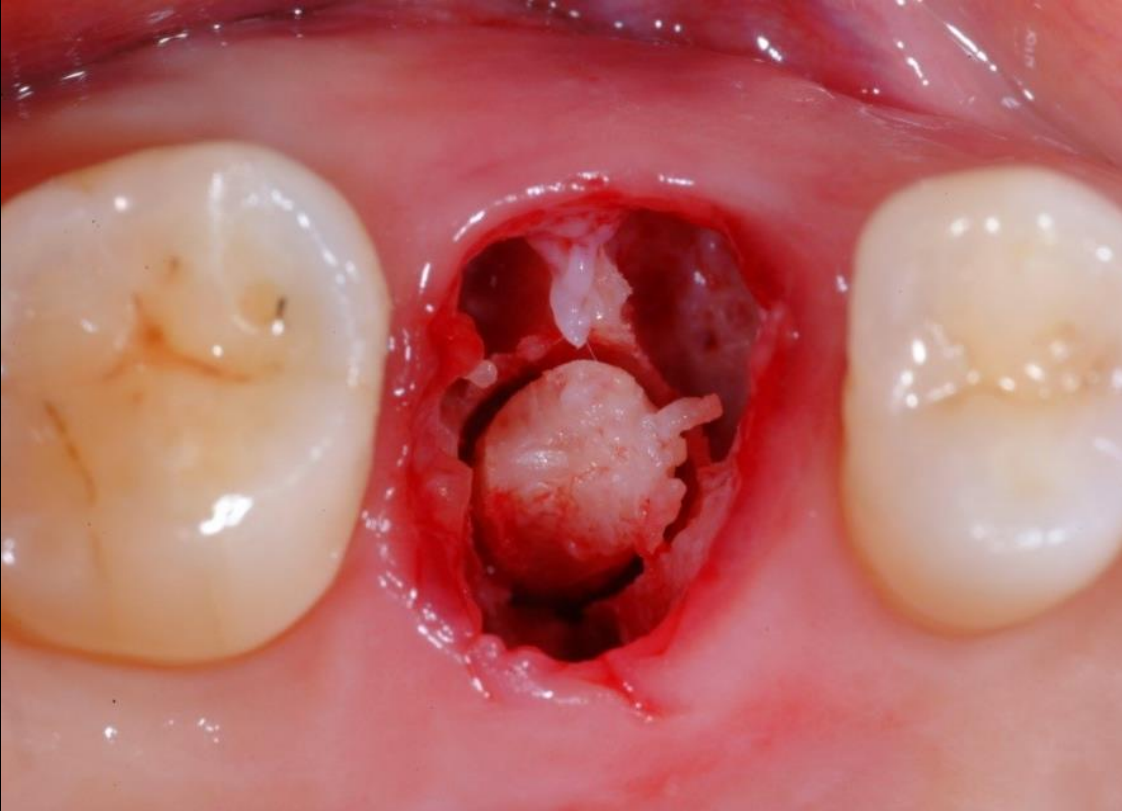
**Initial clinical
situation**

**Surgical
procedure**

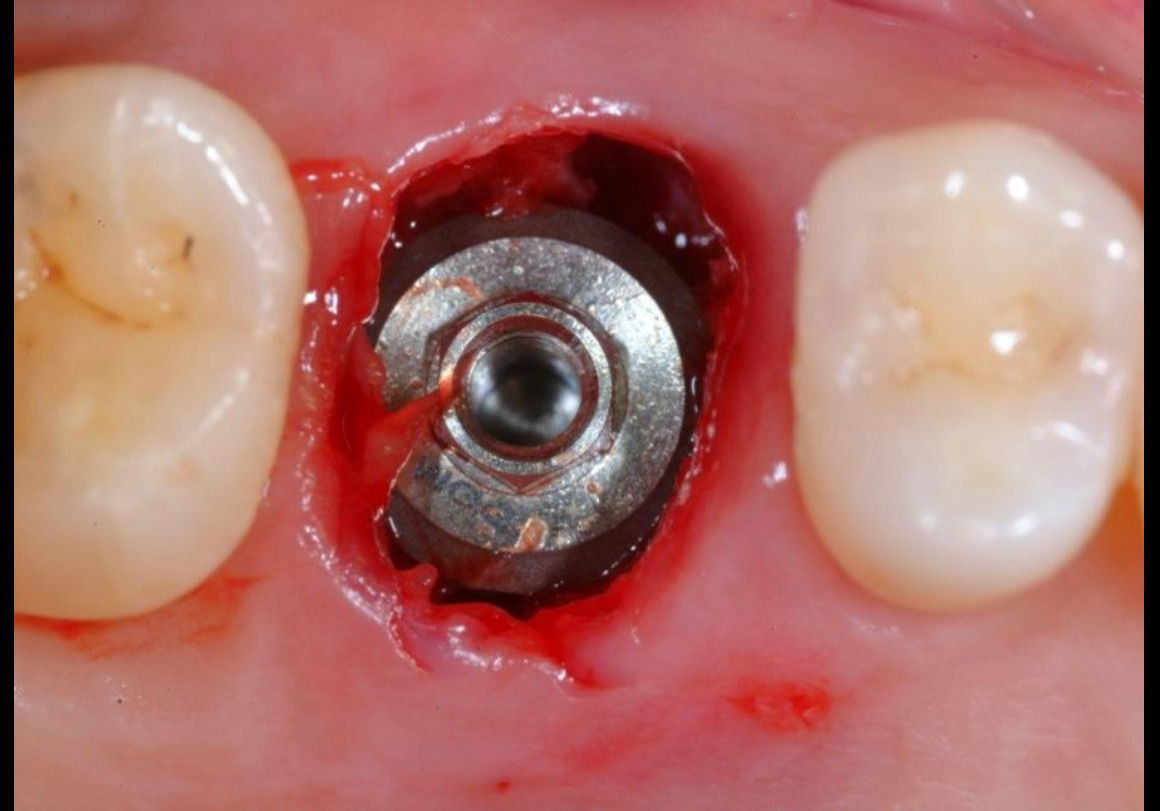
**Restorative
procedure**

Outcome

Extraction and implant positioning



During removal the core was taken to use as osseous coagulum



Immediate implant placement

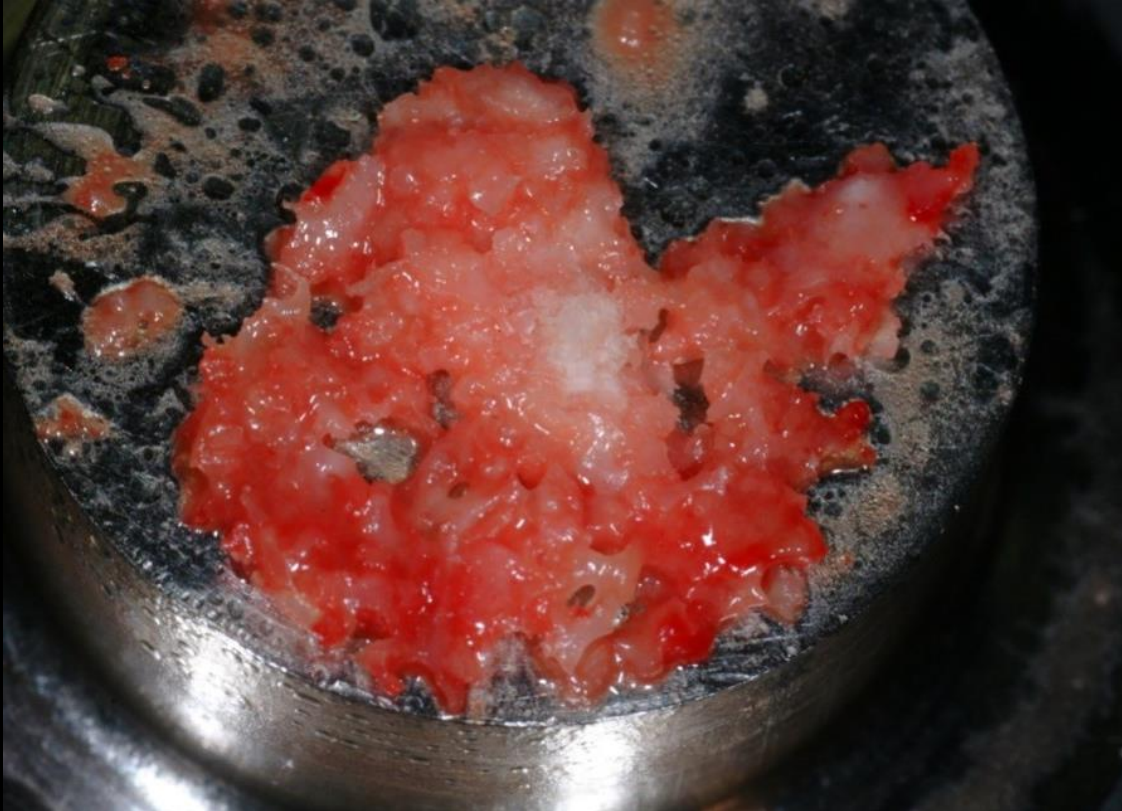**Initial clinical
situation**

**Surgical
procedure**

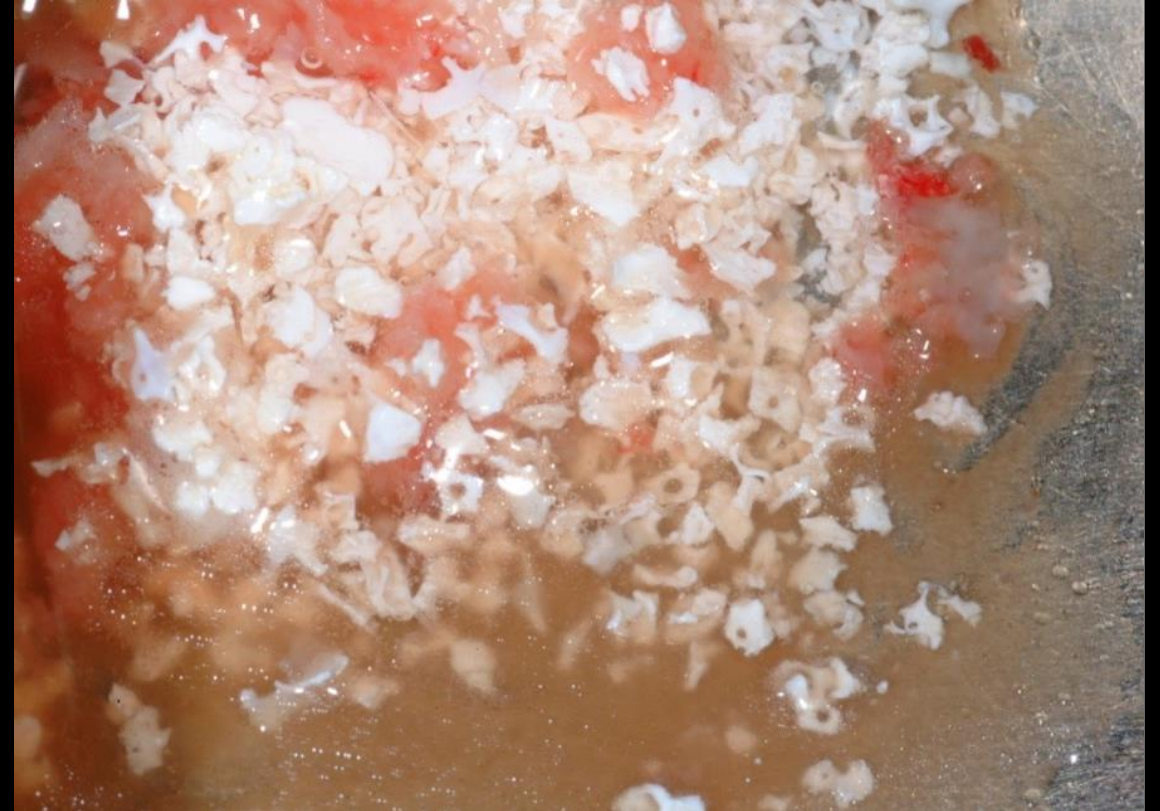**Restorative
procedure**

Outcome

Graft material preparation



The osseous coagulum was crushed



The autologous bone was mixed with PRP and creos™ xenoform

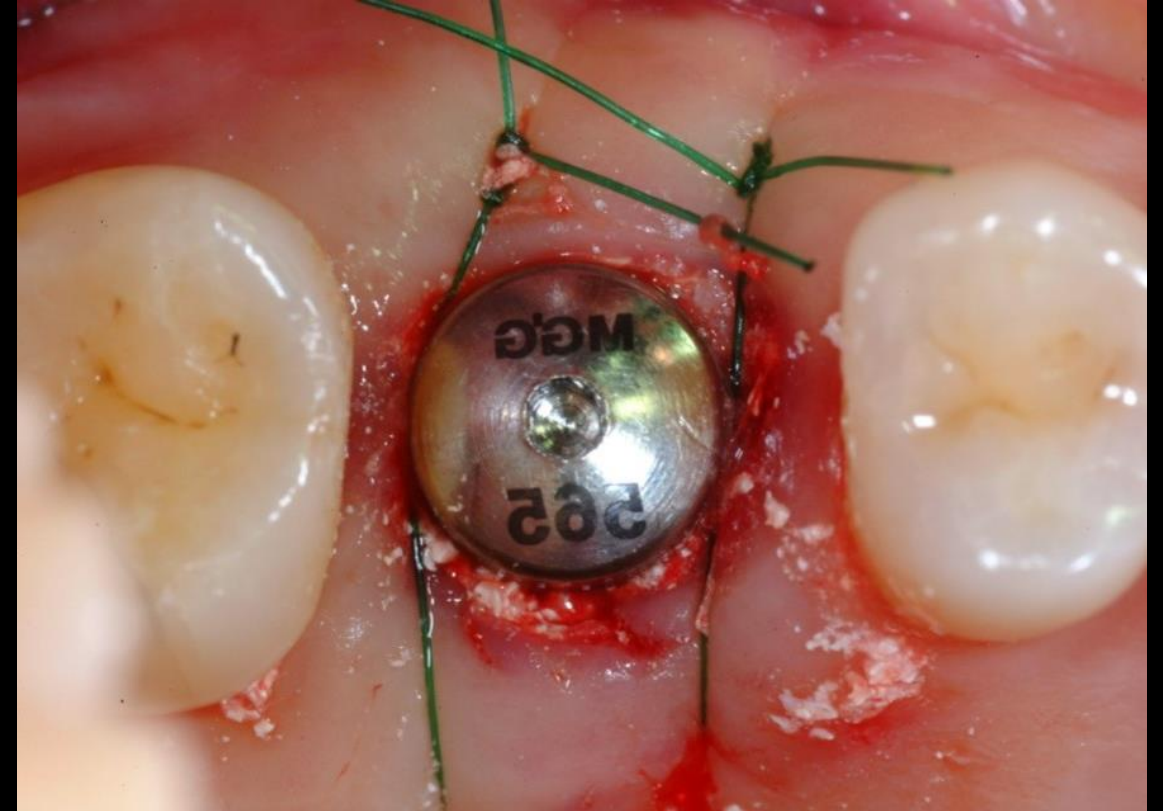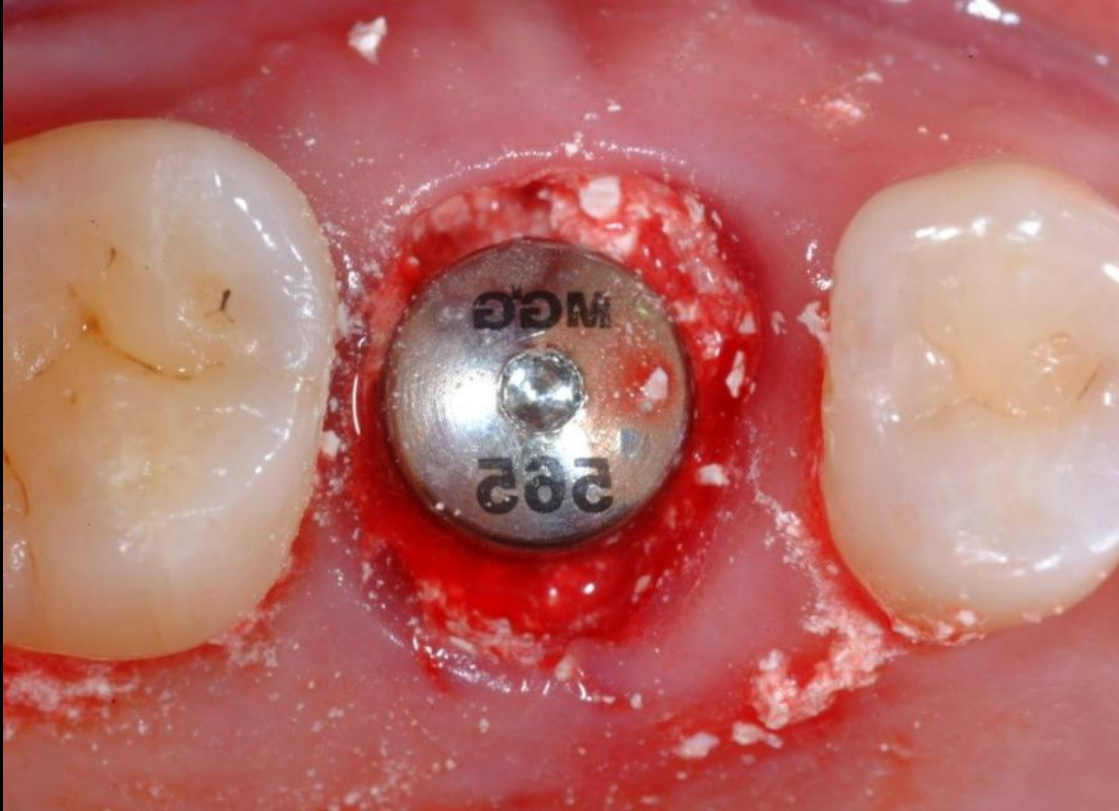Initial clinical
situation

Surgical
procedure

Restorative
procedure

Outcome

Grafting and suturing



Healing abutment connected for one stage surgery. creos™ xenoform graft pushed into the socket without applying excessive pressure, so to preserve the biological characteristics of the material to promote revascularization.

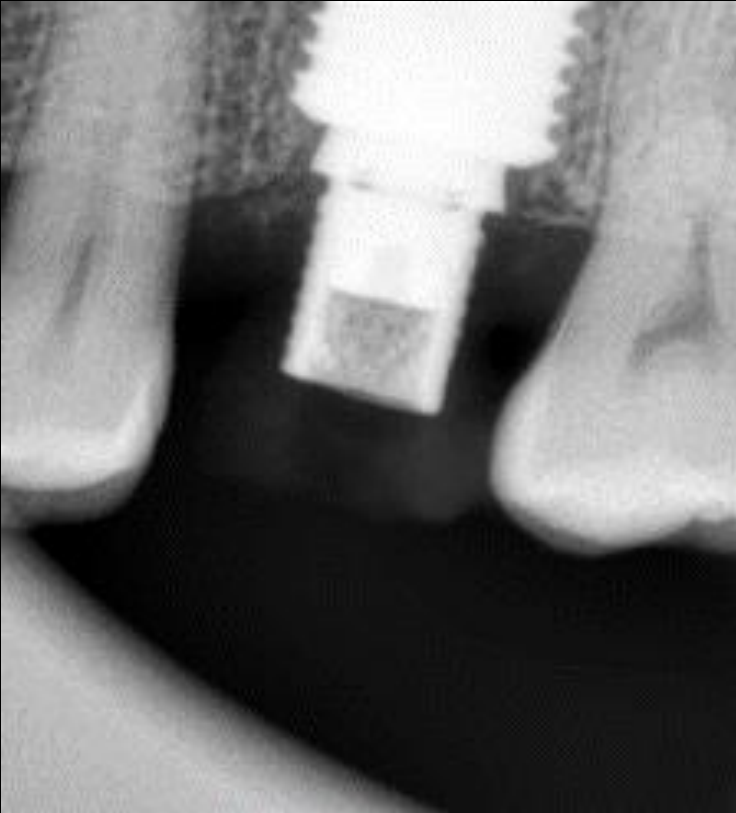
**Initial clinical
situation**

**Surgical
procedure**

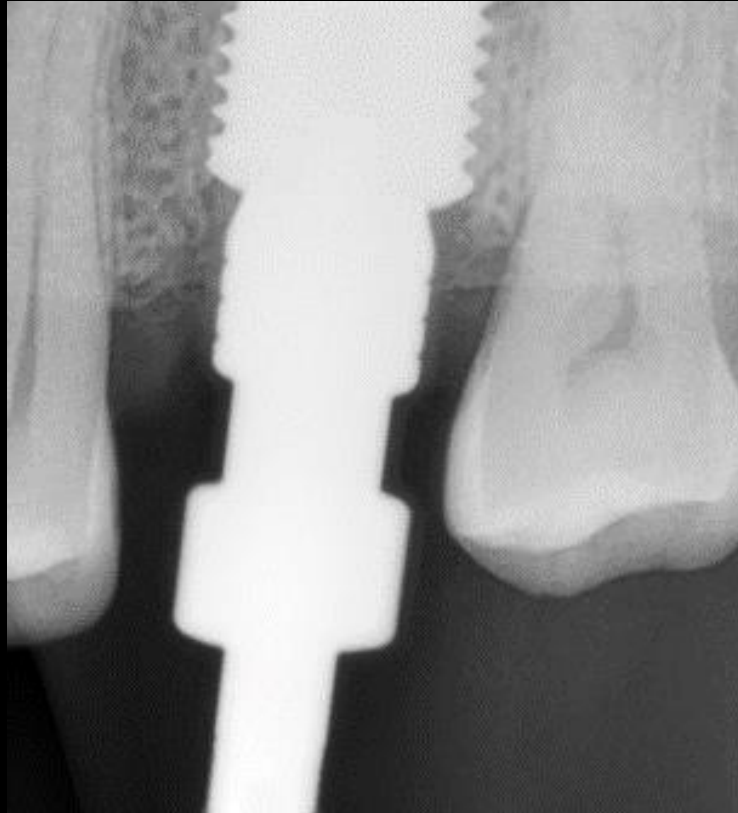**Restorative
procedure**

Outcome

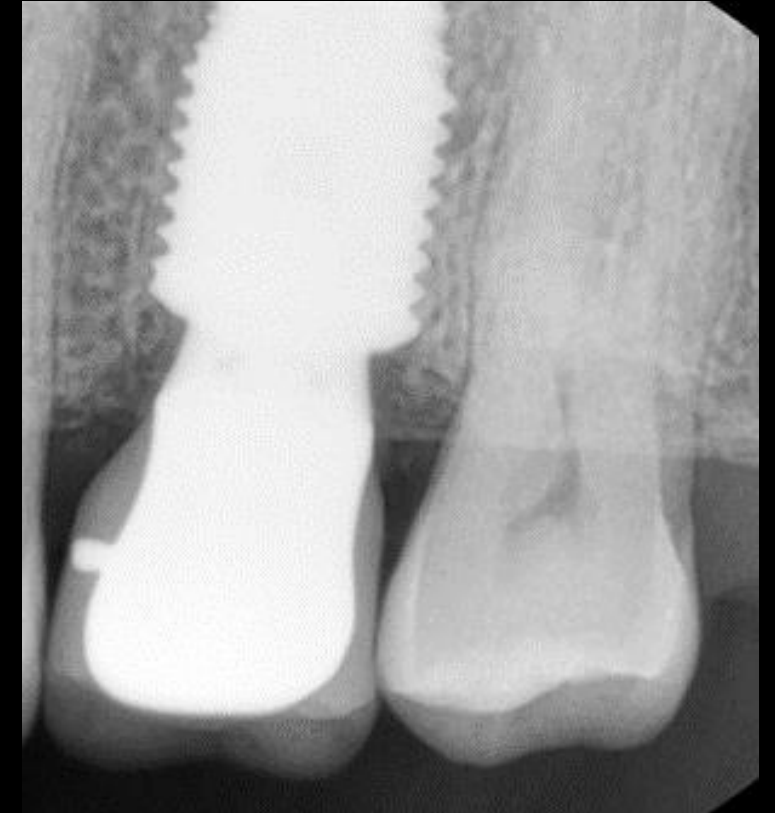Temporary and final prosthetic



X-ray 2.5 months after surgery



X-ray 4 months after surgery



X-ray 4.5 months after surgery

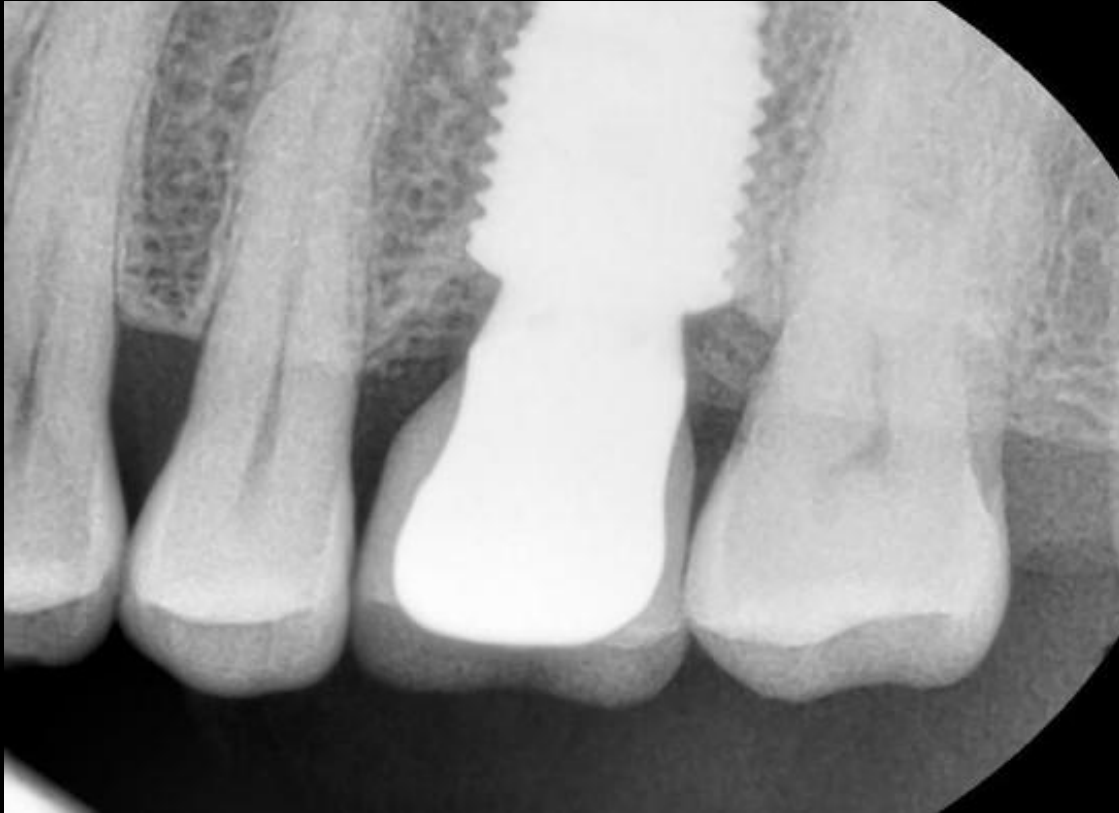**Initial clinical
situation**

**Surgical
procedure**

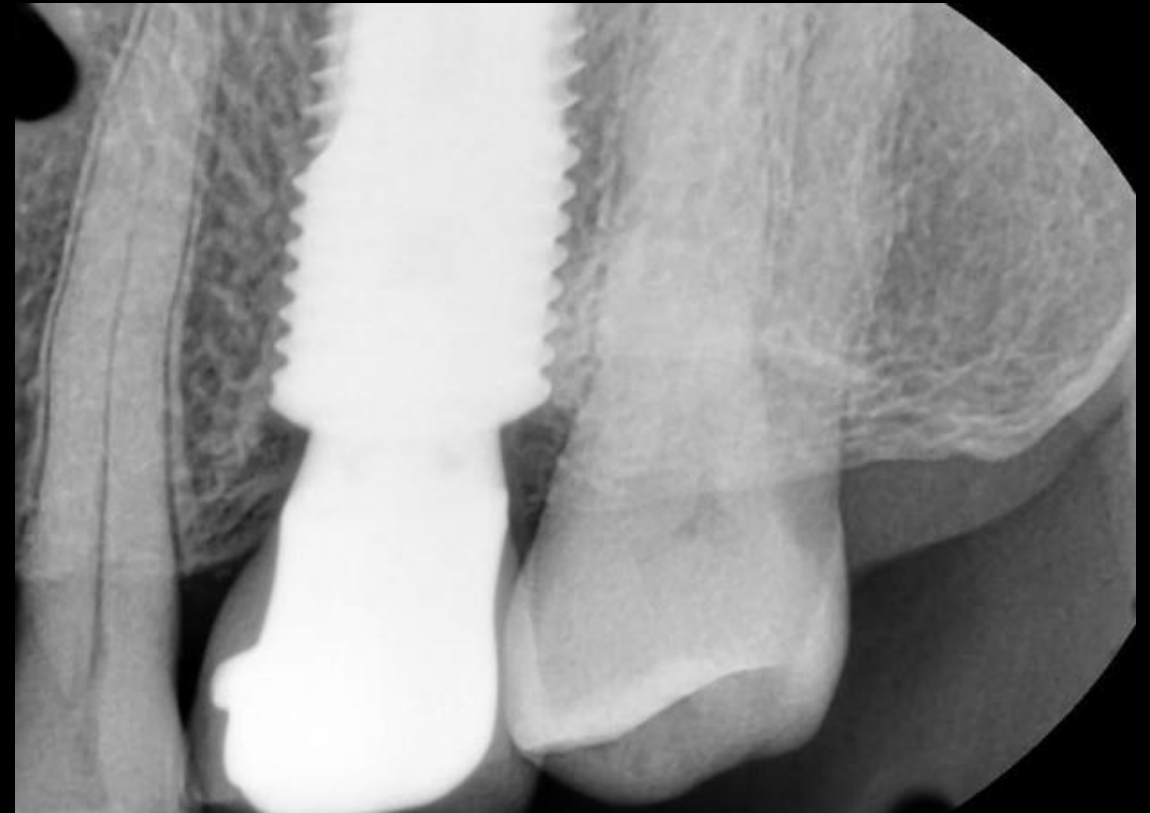
**Restorative
procedure**

Outcome

Patient follow-up



X-ray at 6 years



X-ray at 11 years

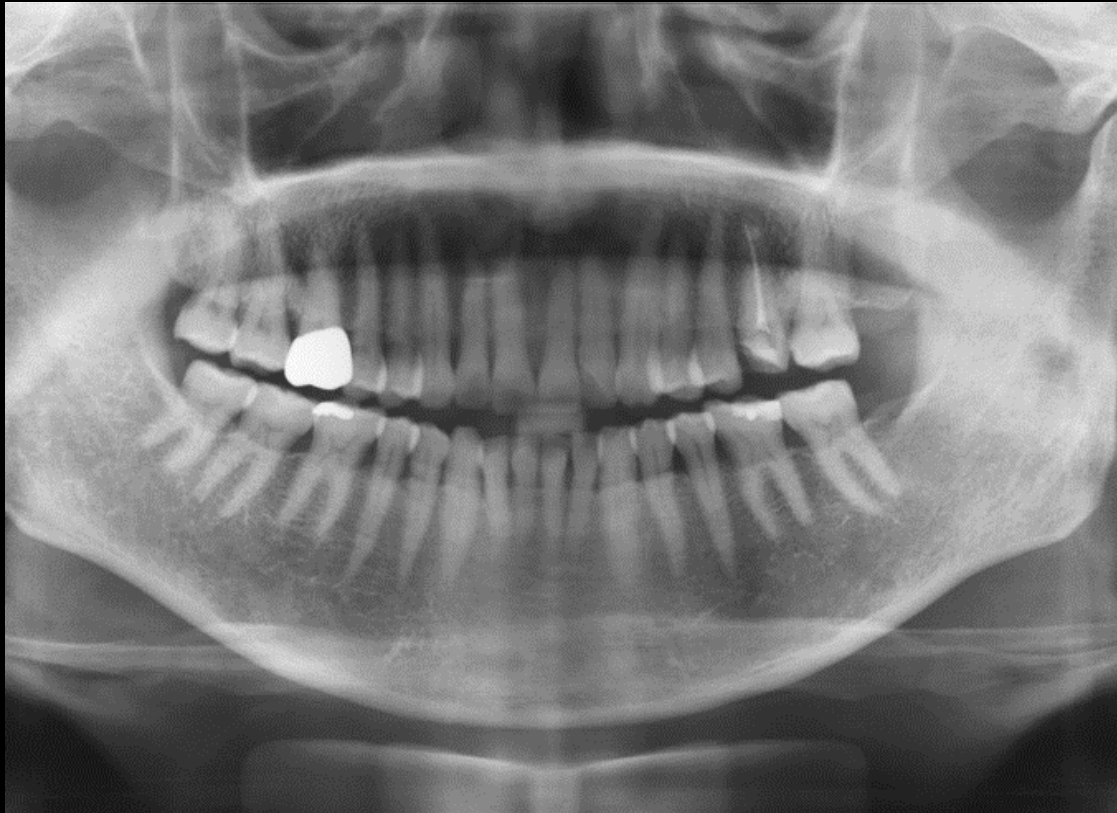
**Initial clinical
situation**

**Surgical
procedure**

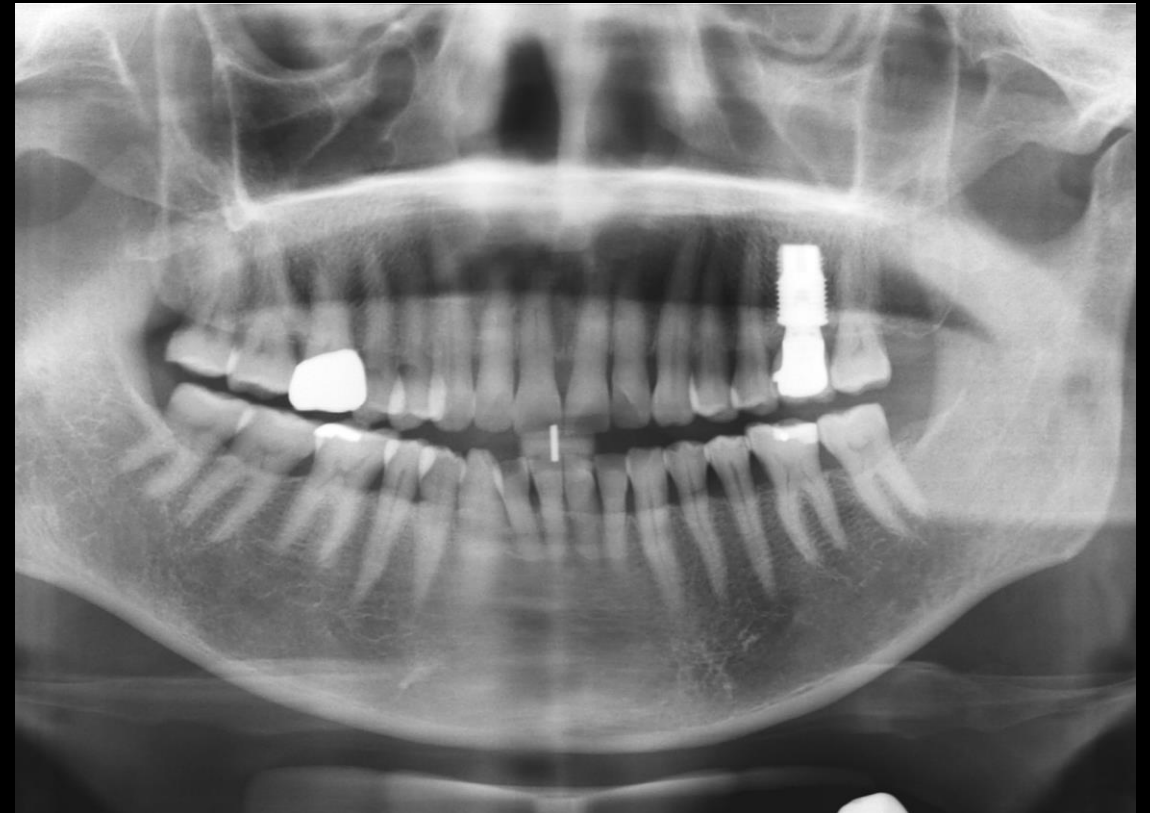**Restorative
procedure**

Outcome

Before and after



Presurgical panoramic image



47 months follow-up panoramic image

Case courtesy of Lee, Myung Ho, D.D.S.



GMT 83545 GB 2302 © Nobel Biocare Services AG, 2023. . All rights reserved. Distributed by: Nobel Biocare. Nobel Biocare, the Nobel Biocare logotype and all other trademarks are, if nothing else is stated or is evident from the context in a certain case, trademarks of Nobel Biocare. Please refer to nobelbiocare.com/trademarks for more information. Product images are not necessarily to scale. All product images are for illustration purposes only and may not be an exact representation of the product. Please contact the local Nobel Biocare sales office for current product assortment and availability. Disclaimer: For prescription use only. Caution: Federal (United States) law or the law in your jurisdiction may restrict this device to sale by or on the order of a licensed clinician, medical professional or physician. See Instructions For Use for full prescribing information, including indications, contraindications, warnings and precautions. Ti-oss® (Chiyewon Co., Ltd.) is distributed as creos™ xenoform since January 2023. Legal Manufacturer: Chiyewon Co., Ltd. 6F, 192 Gyeongchunro, Guri si, Gyeonggido, Korea 11927.

Nobel Biocare does not take any liability for any injury or damage to any person or property arising from the use of this clinical case. This clinical case is not intended to recommend any measures, techniques, procedures or products, or give advice, and is not a substitute for medical training or your own clinical judgement as a healthcare professional. Viewers should never disregard professional medical advice or delay seeking medical treatment because of something they have seen in this clinical case. Full procedure is not shown. Certain sequences have been cut.