

CLINICAL CASE



# Nobel Biocare N1™ system

Immediate placement and  
loading of a single tooth  
restoration in the  
premolar area

Giacomo Fabbri  
Italy





**Giacomo Fabbri**

**Patient**

51-year-old female, smoker

**Clinical situation**

Clinical intraoral situation demonstrates good condition except the second premolar (FDI position 25) that is non-vital with a vertical fracture. X-ray evaluation shows a radiotransparent area on the mesial aspect of the root extended to the apex.

**Surgical solution**

Considering the ideal status of the soft tissue volume and architecture, and the integrity of the buccal bone plate, it was decided to proceed with an immediate post-extraction implant and immediate loading.

**Restorative solution**

Immediate temporization using full digital workflow and TempShell approach at N1 base level. Final restoration in full-contour zirconia using Universal Abutment at Base level.

**Surgery date**

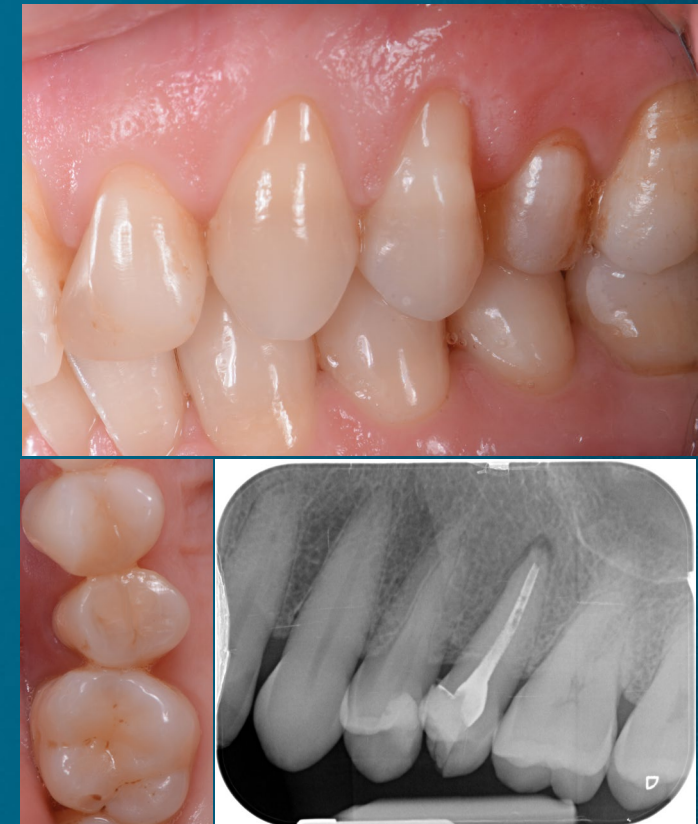February 2021

**Total treatment time**

12 weeks

**Tooth position**

25





**Initial clinical  
situation**

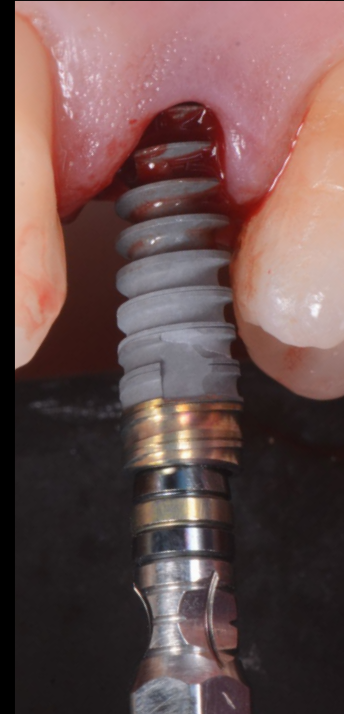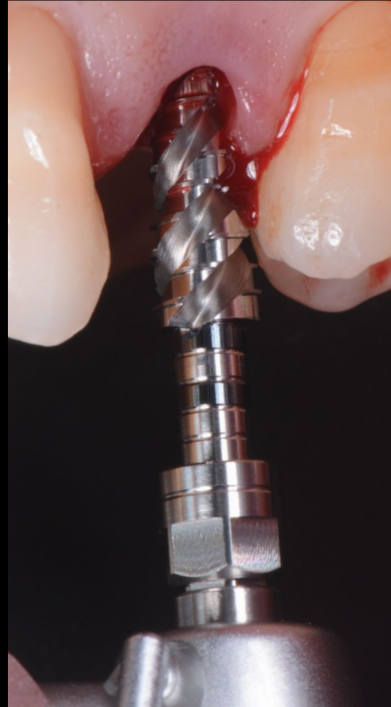
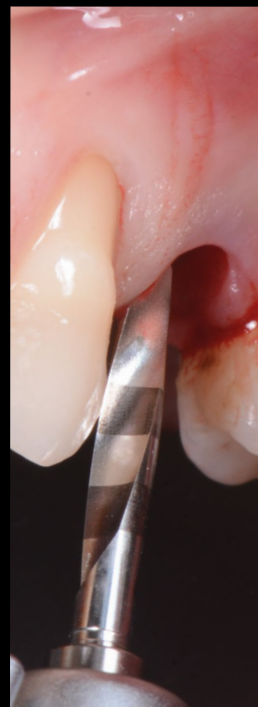**Treatment  
planning**

**Surgical  
procedure**

**Restorative  
procedure**

**Outcome**

**After tooth extraction the implant site was prepared in accordance with the manufacturer's instructions for the Nobel Biocare N1 Implant system. The pilot osteotomy was created with the OsseoDirector™, then the final osteotomy was created with the OsseoShaper™ to a torque of 23 Ncm. An N1 RP 13 mm implant was placed achieving 51 Ncm of final implant insertion torque.**



**Initial clinical  
situation**

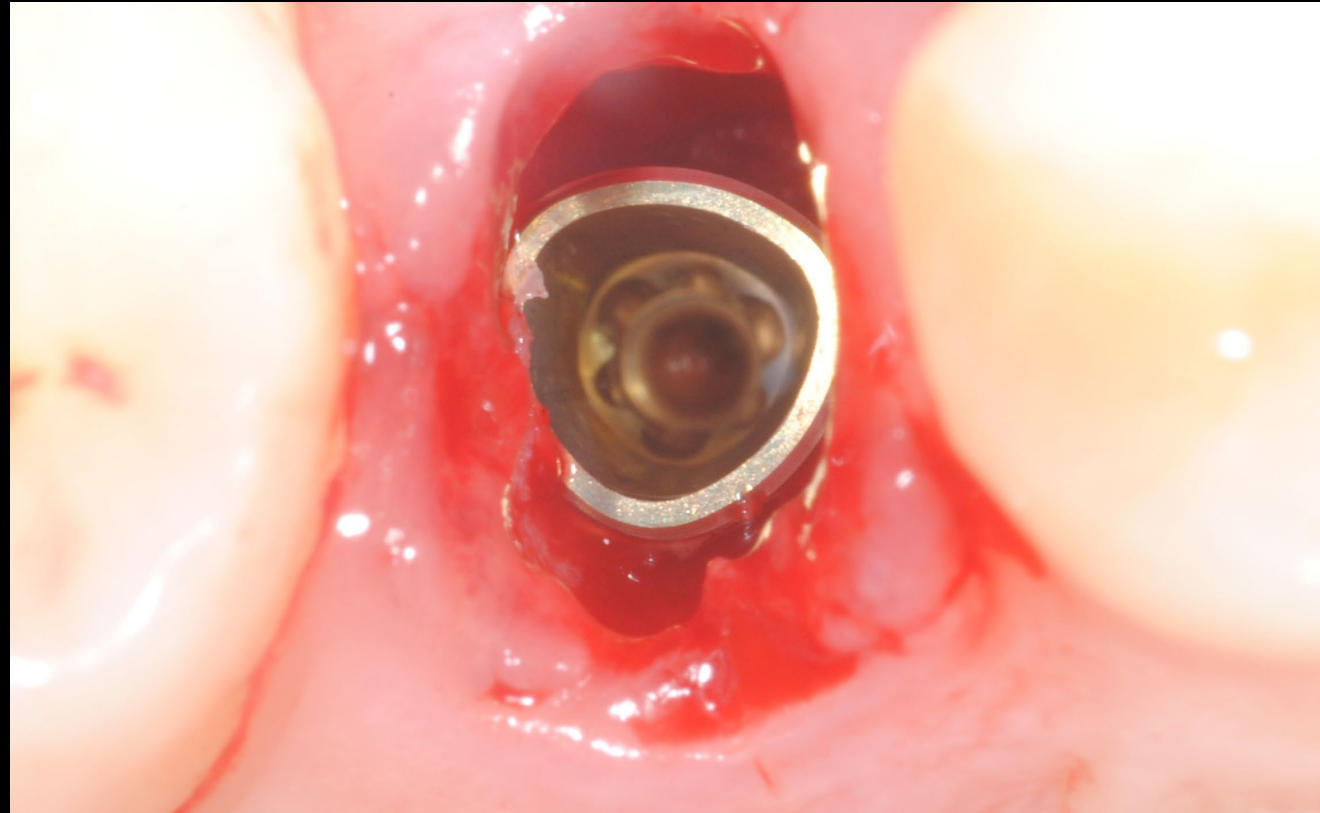
**Treatment  
planning**

**Surgical  
procedure**

**Restorative  
procedure**

**Outcome**

**The implant was placed approximately 3.5 mm below the buccal free gingival margin.  
The flat side of the tri-lobe was placed on the buccal aspect in accordance with the manufacturer's instructions.**





**Initial clinical  
situation**

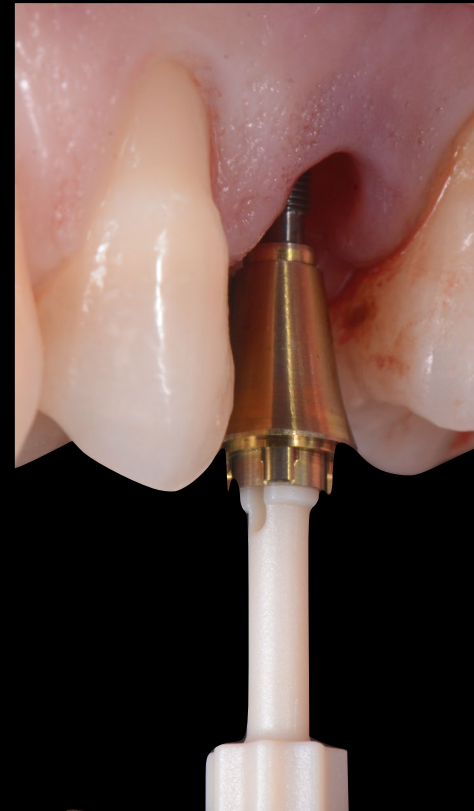
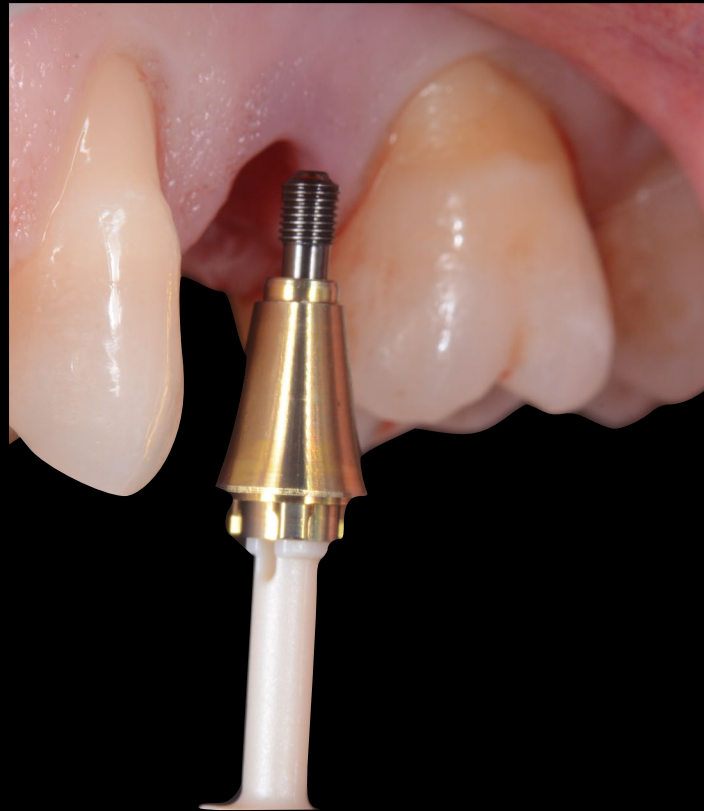**Treatment  
planning**

**Surgical  
procedure**

**Restorative  
procedure**

**Outcome**

**The Xeal™ N1 Base RP 1.75 mm was placed immediately after the implant placement and tightened to the final torque of 20 Ncm.**



**Initial clinical  
situation**

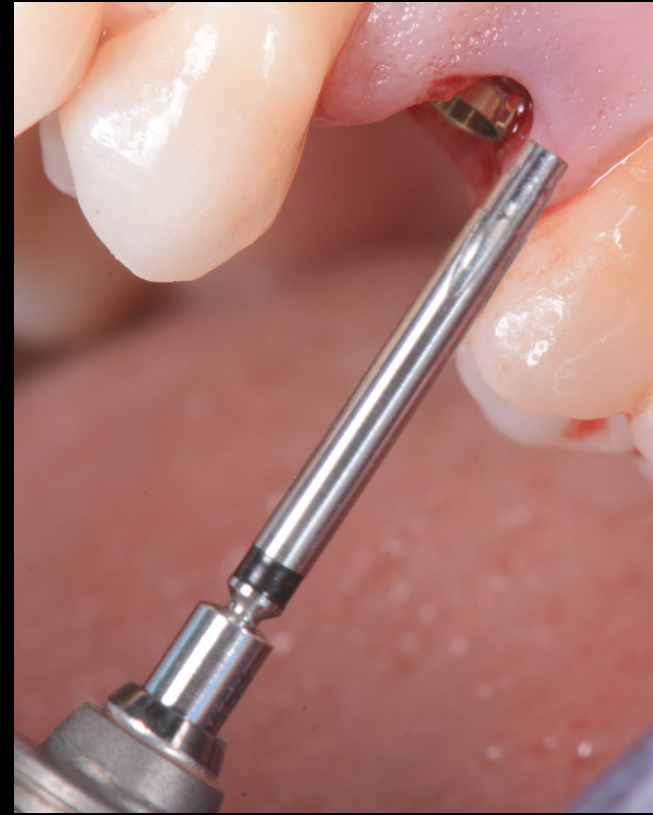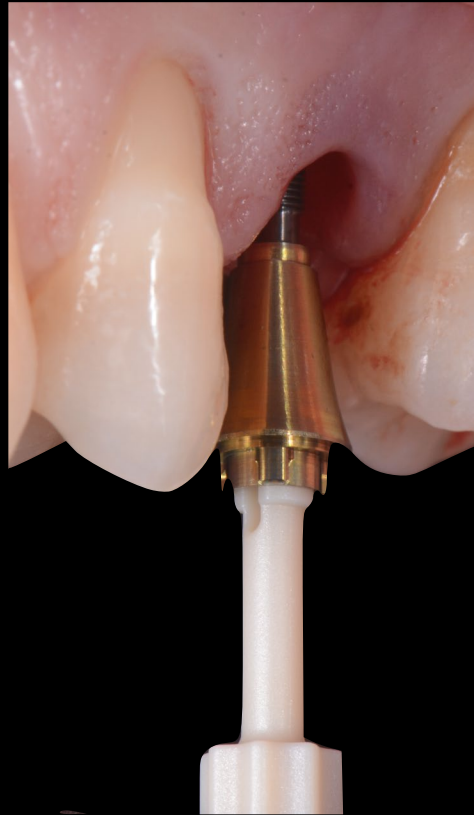**Treatment  
planning**

**Surgical  
procedure**

**Restorative  
procedure**

**Outcome**

**The N1 Base was placed using a plastic handle, then once in situ the final torque was achieved using the N1 Base screwdriver attached to the dedicated prosthetic torque wrench.**



**Initial clinical  
situation**

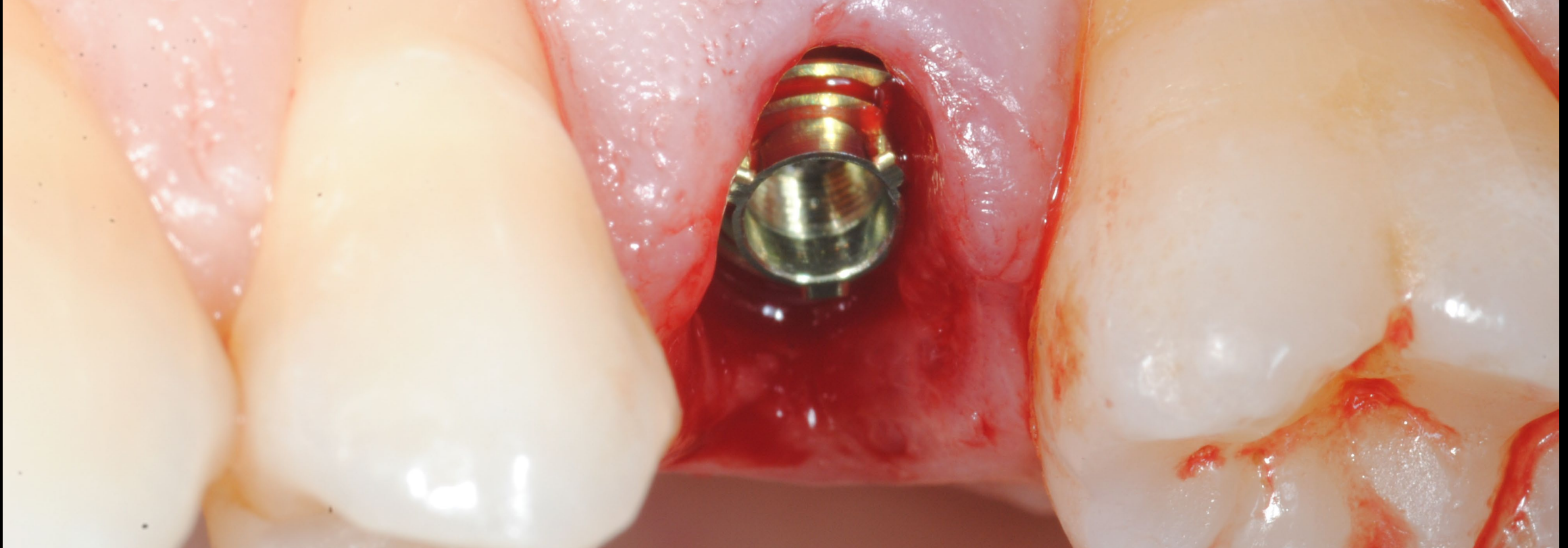
**Treatment  
planning**

**Surgical  
procedure**

**Restorative  
procedure**

**Outcome**

**N1 Base in situ. The new trioval prosthetic platform is located about 1.75 mm below the buccal soft tissue level.**





**Initial clinical  
situation**

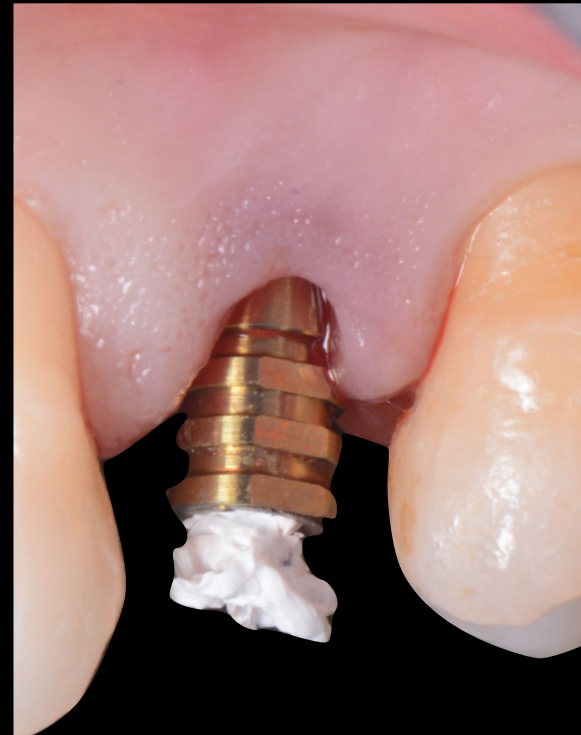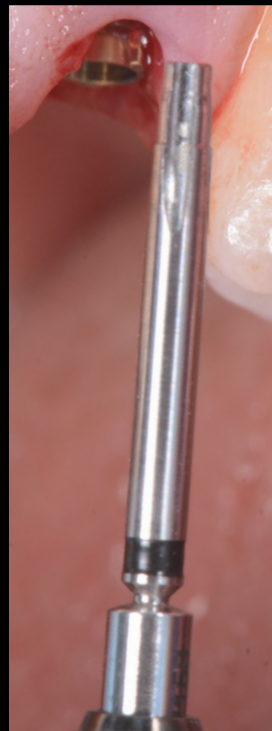**Treatment  
planning**

**Surgical  
procedure**

**Restorative  
procedure**

**Outcome**

**N1 Base titanium temporary abutment was placed in order to proceed with an immediate temporization using the fully digital workflow of a TempShell provisional. The screw access channel was closed with Teflon in order to protect the screw head during the restorative procedure.**



**Initial clinical  
situation**

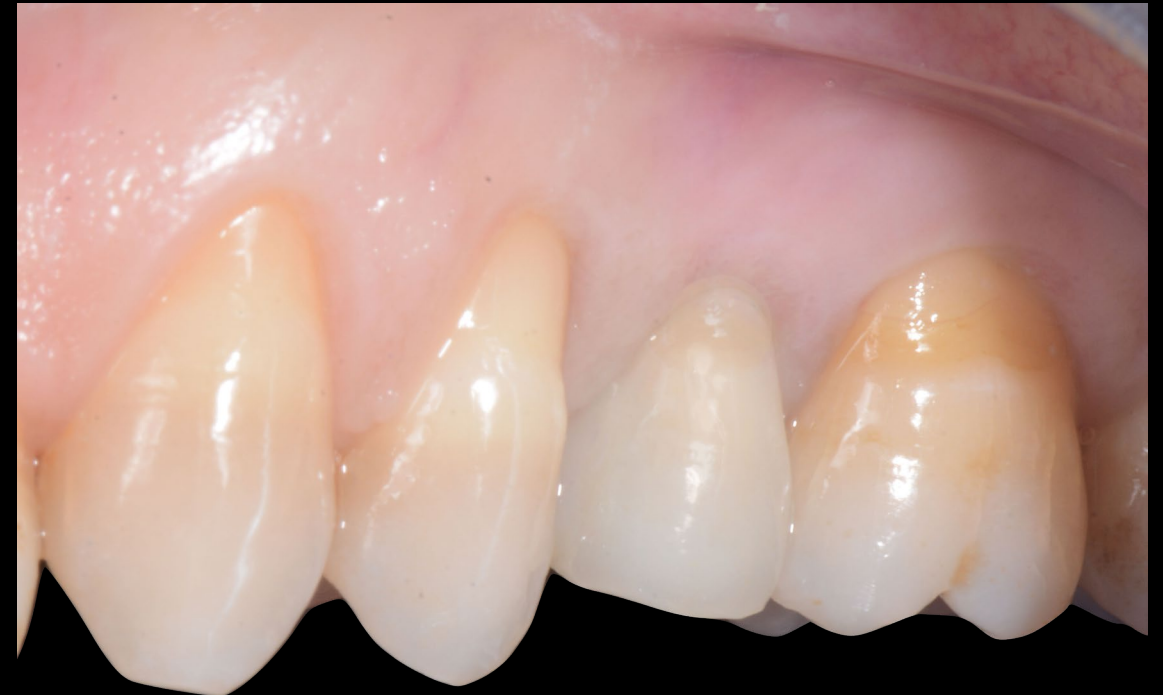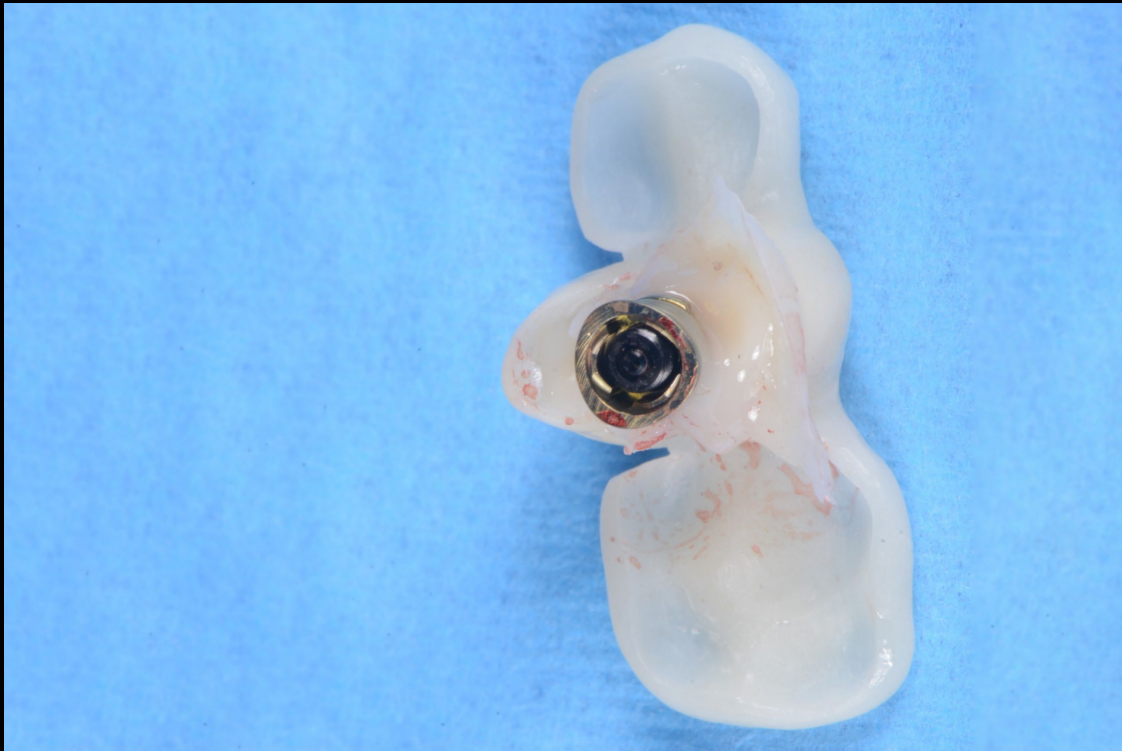
**Treatment  
planning**

**Surgical  
procedure**

**Restorative  
procedure**

**Outcome**

The temporary abutment was fixed to the TempShell using flowable composite. The temporary restoration was then placed in situ and tightened to 20 Ncm with Omnigrip Mini. The clinical view shows the result immediately after the surgery.



**Initial clinical  
situation**

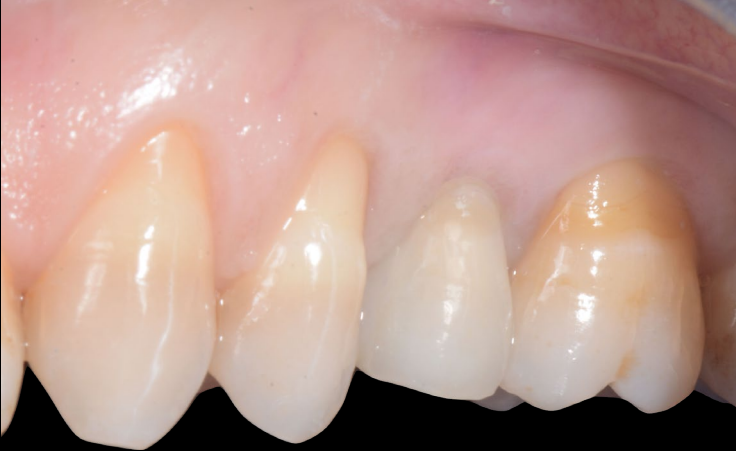**Treatment  
planning**

**Surgical  
procedure**

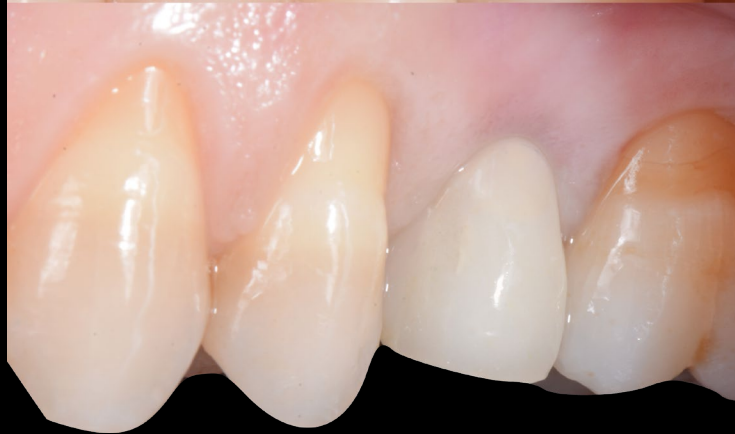**Restorative  
procedure**

**Outcome**

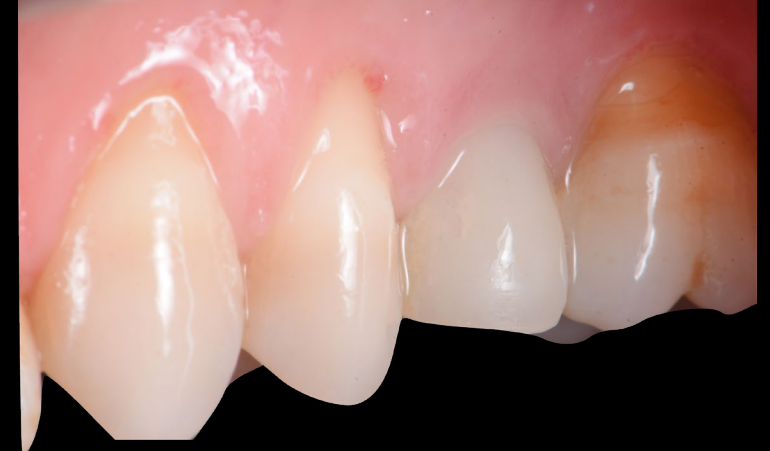**Day 0**



**4 weeks**



**10 weeks**



**Clinical view immediately after the surgery**

**Clinical view at 4 weeks after the surgery**

**Clinical view 10 weeks after the surgery.  
Note the excellent tissue stability and appearance.**



**Initial clinical  
situation**

**Treatment  
planning**

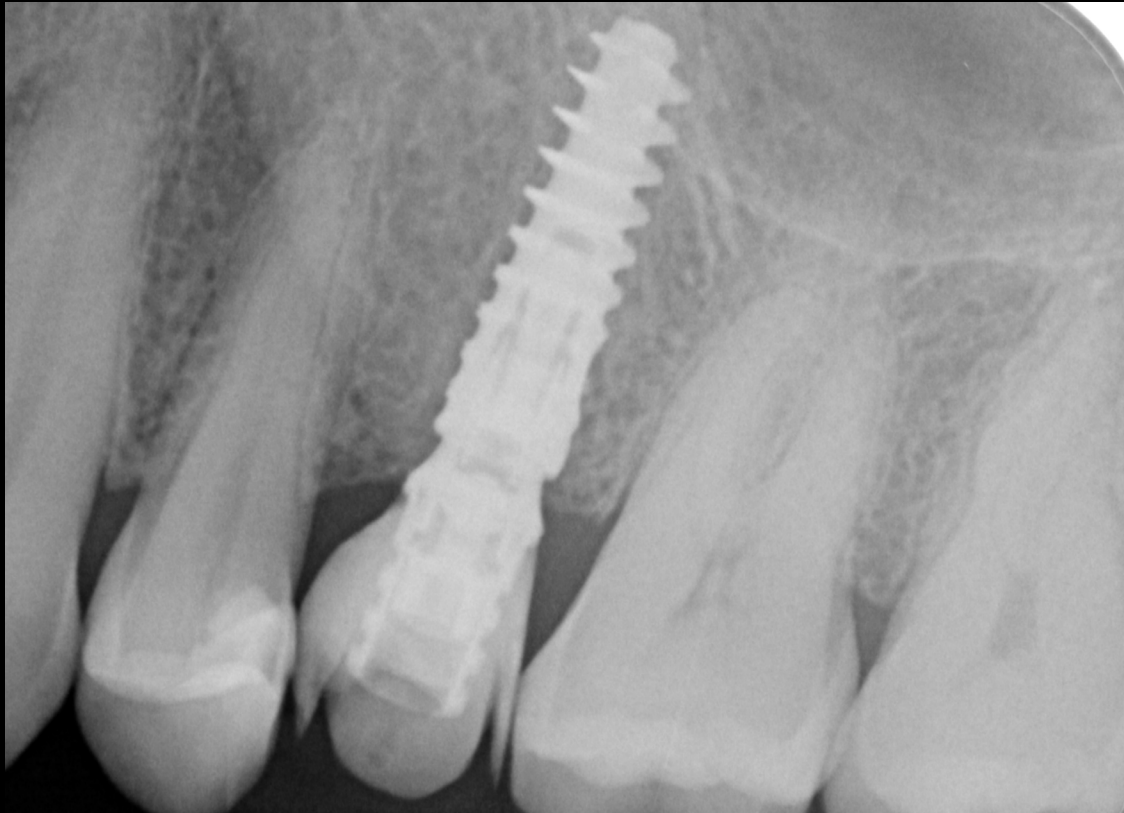
**Surgical  
procedure**

**Restorative  
procedure**

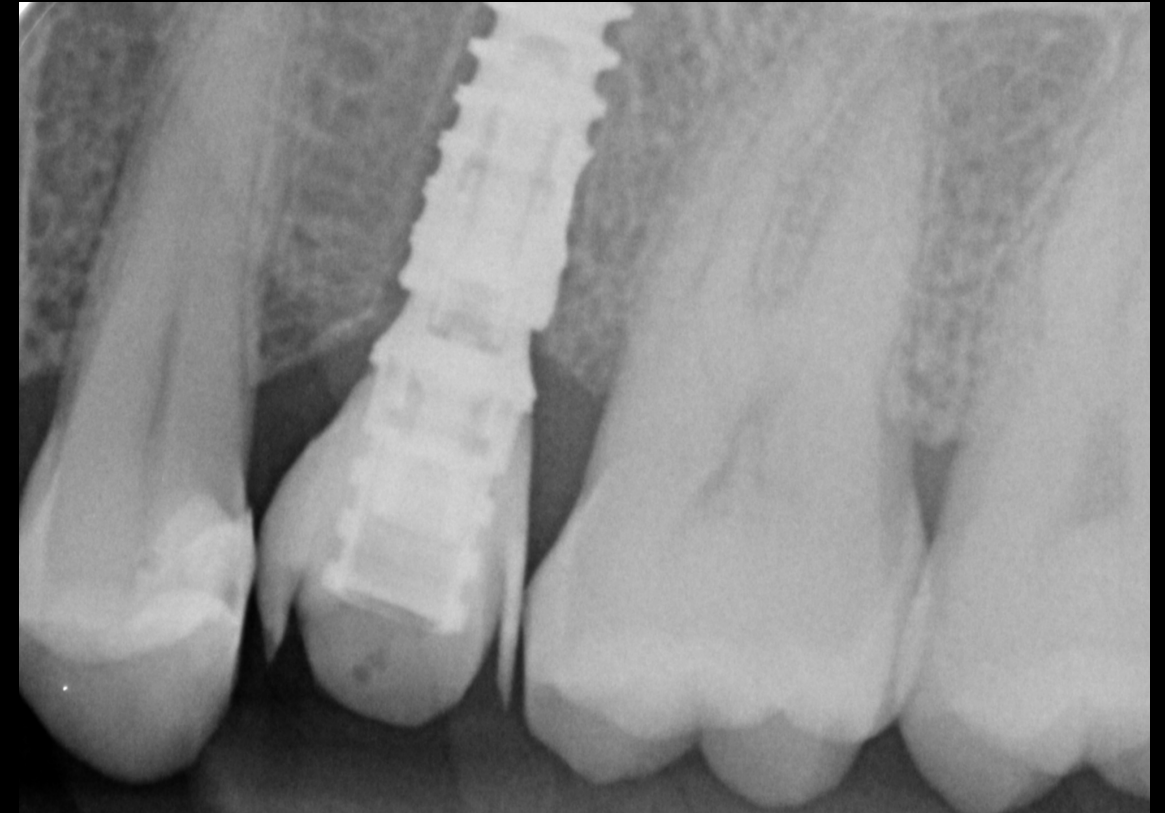**Outcome**

**Day 0**

**10 weeks**



**X-ray evaluation immediately after the surgery**



**X-ray evaluation 10 weeks after the surgery**

**Initial clinical  
situation**

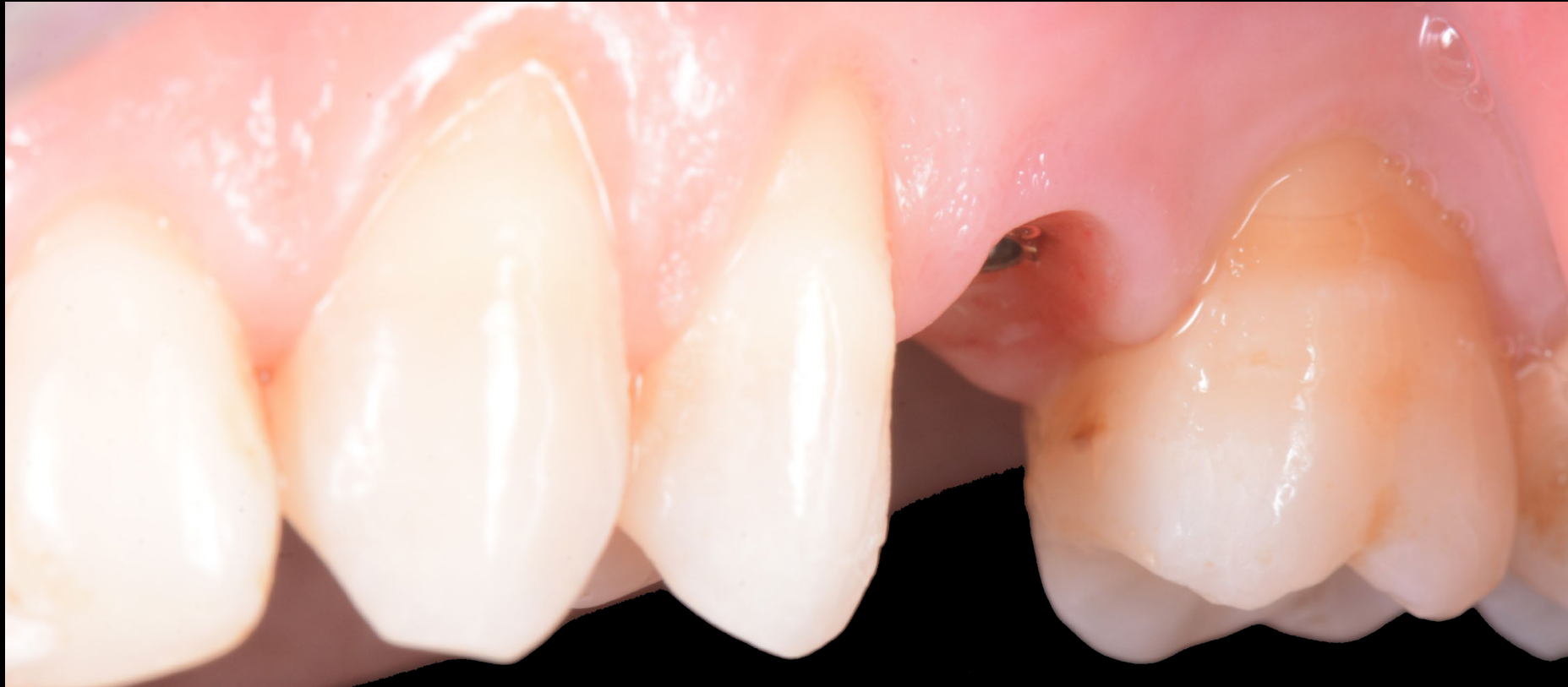**Treatment  
planning**

**Surgical  
procedure**

**Restorative  
procedure**

**Outcome**

**The temporary restoration was removed 10 weeks after the surgery to take the final impression. Soft tissue volume, morphology and quality appeared stable and healthy.**



**Initial clinical  
situation**

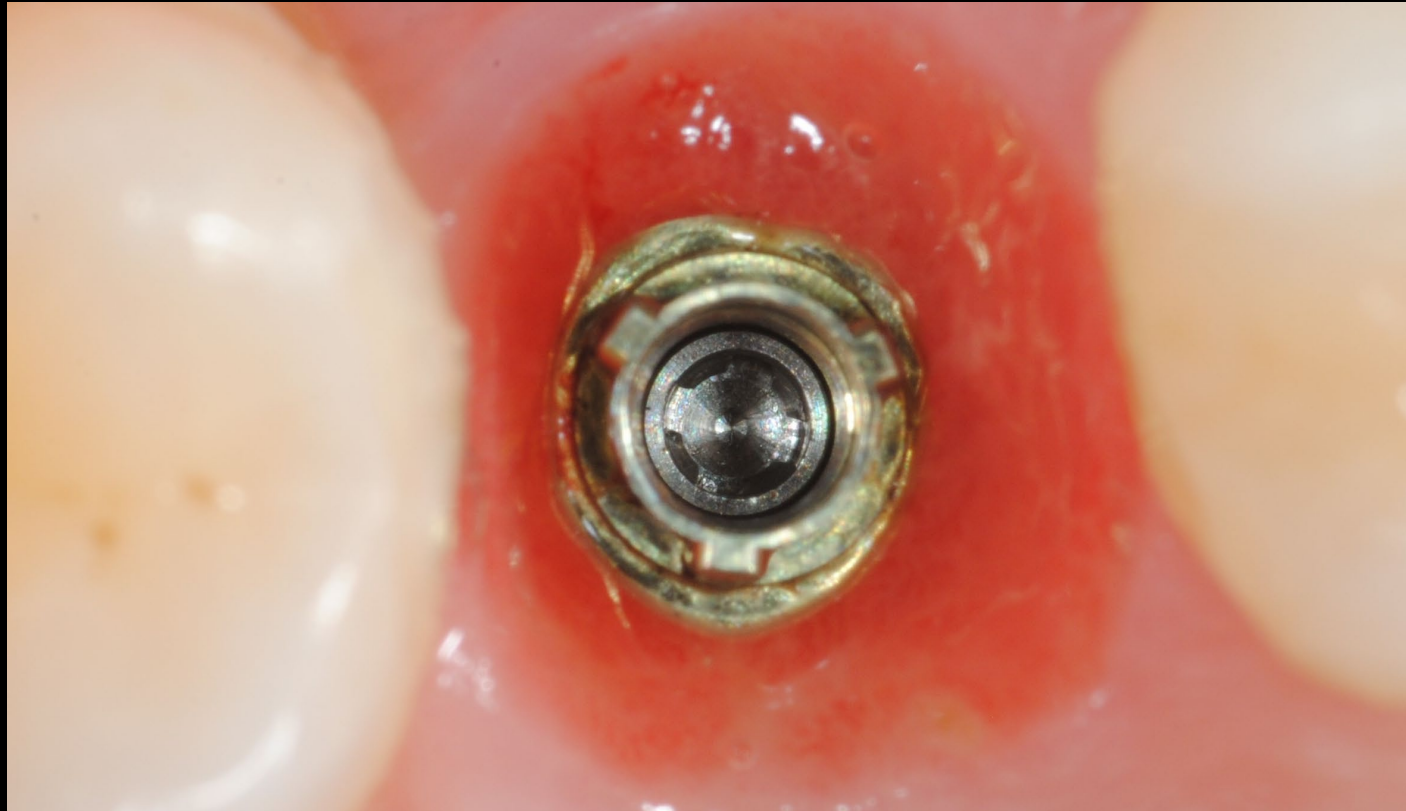
**Treatment  
planning**

**Surgical  
procedure**

**Restorative  
procedure**

**Outcome**

**Occlusal view of the clinical situation 10 weeks after the surgery.**





**Initial clinical  
situation**

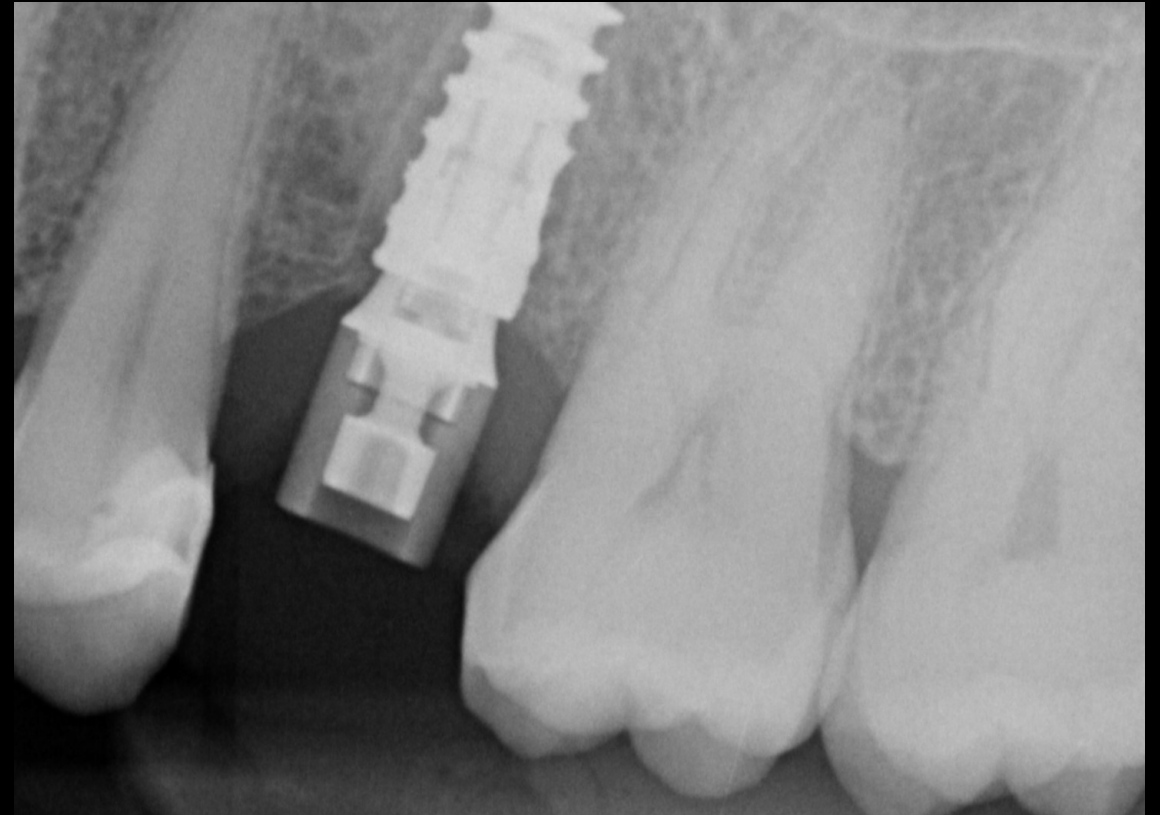
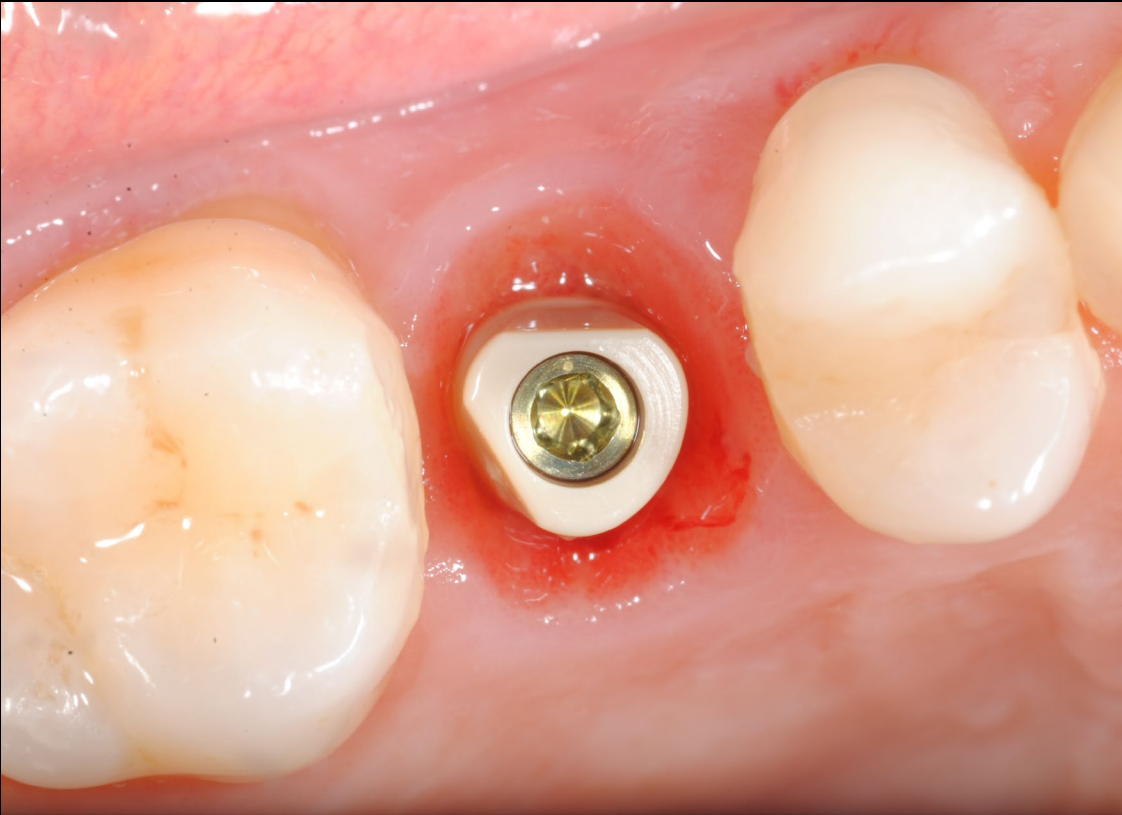
**Treatment  
planning**

**Surgical  
procedure**

**Restorative  
procedure**

**Outcome**

**Final impression was acquired using an intraoral scanner and the IOS Healing Abutment N1 Base. Clinical view and the X-ray show the IOS abutment in situ.**



Initial clinical  
situation

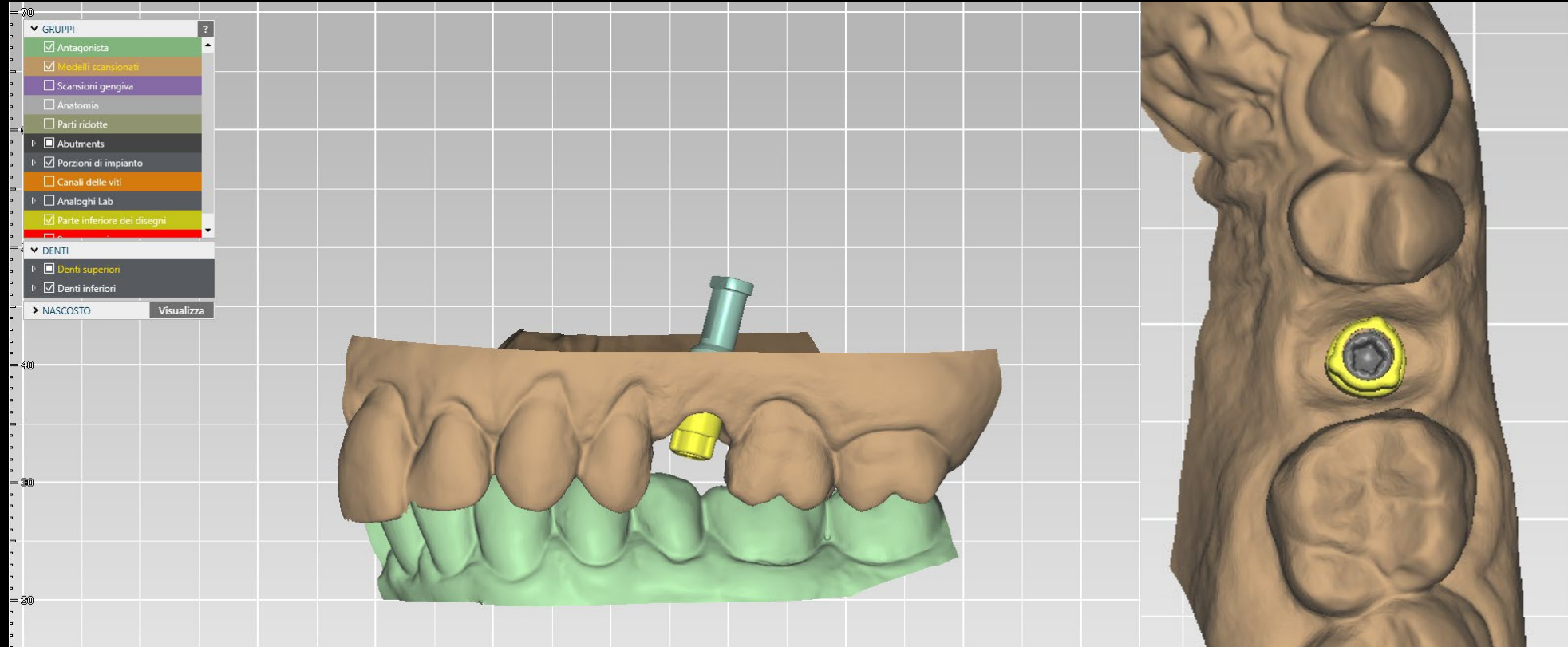
Treatment  
planning

Surgical  
procedure

Restorative  
procedure

Outcome

The final restoration on a Universal Abutment was designed and planned using DTX Studio Lab.



Initial clinical  
situation

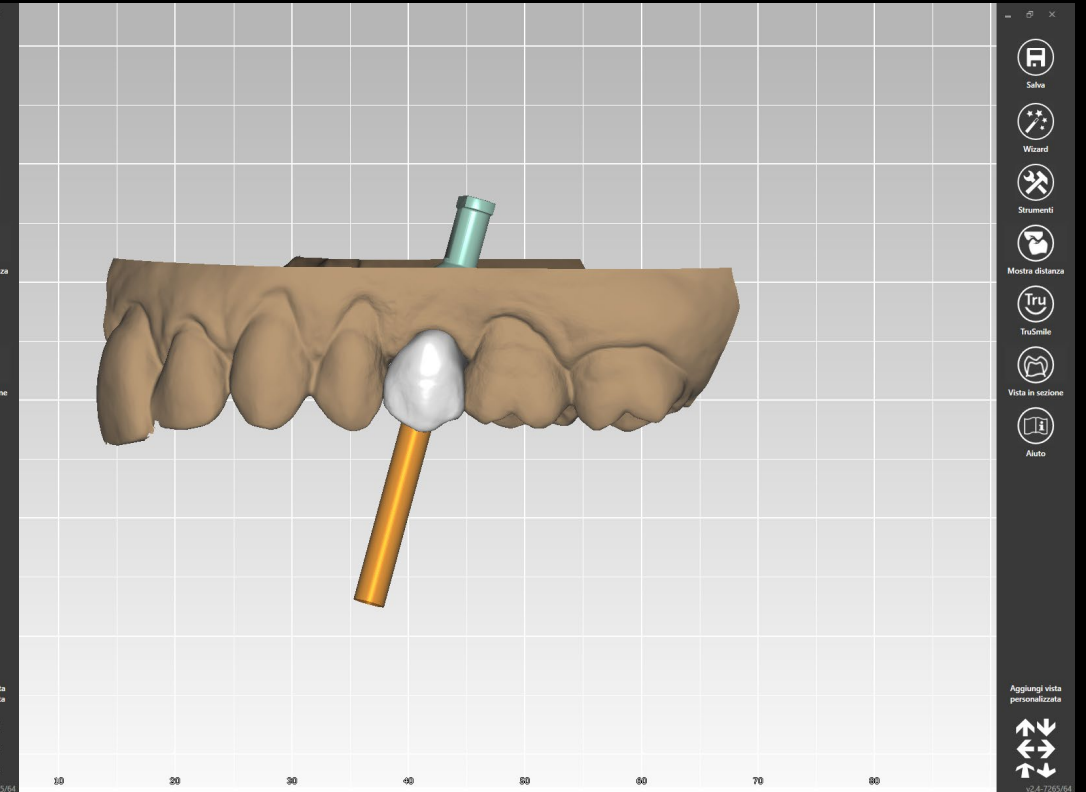
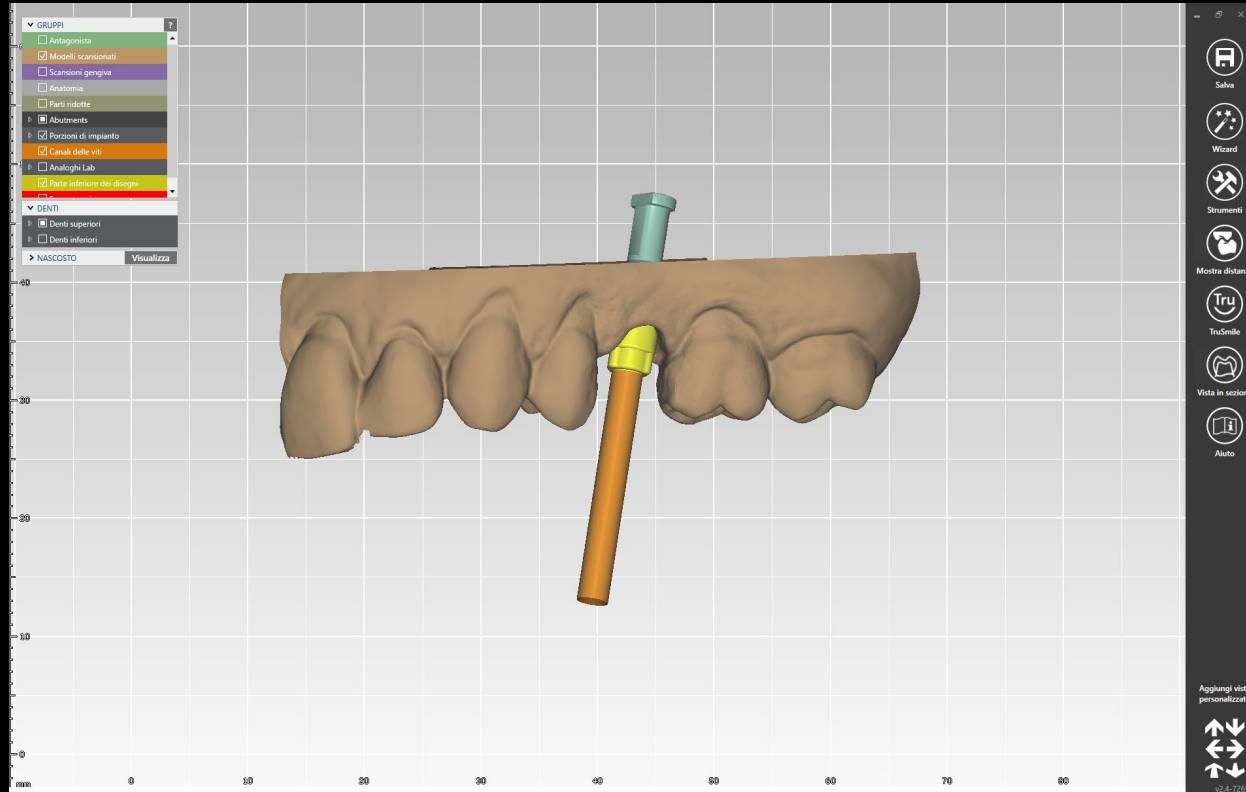
Treatment  
planning

Surgical  
procedure

Restorative  
procedure

Outcome

The final restoration was designed and planned using DTX software and the universal abutment.





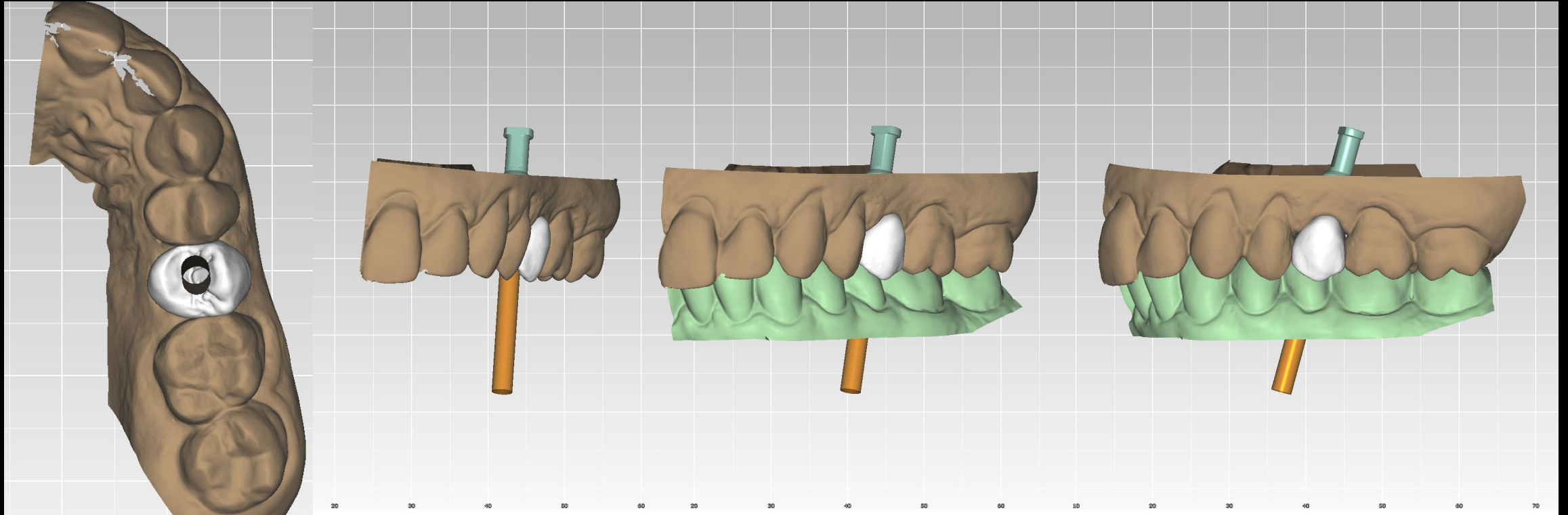
Initial clinical  
situation

Treatment  
planning

Surgical  
procedure

Restorative  
procedure

Outcome



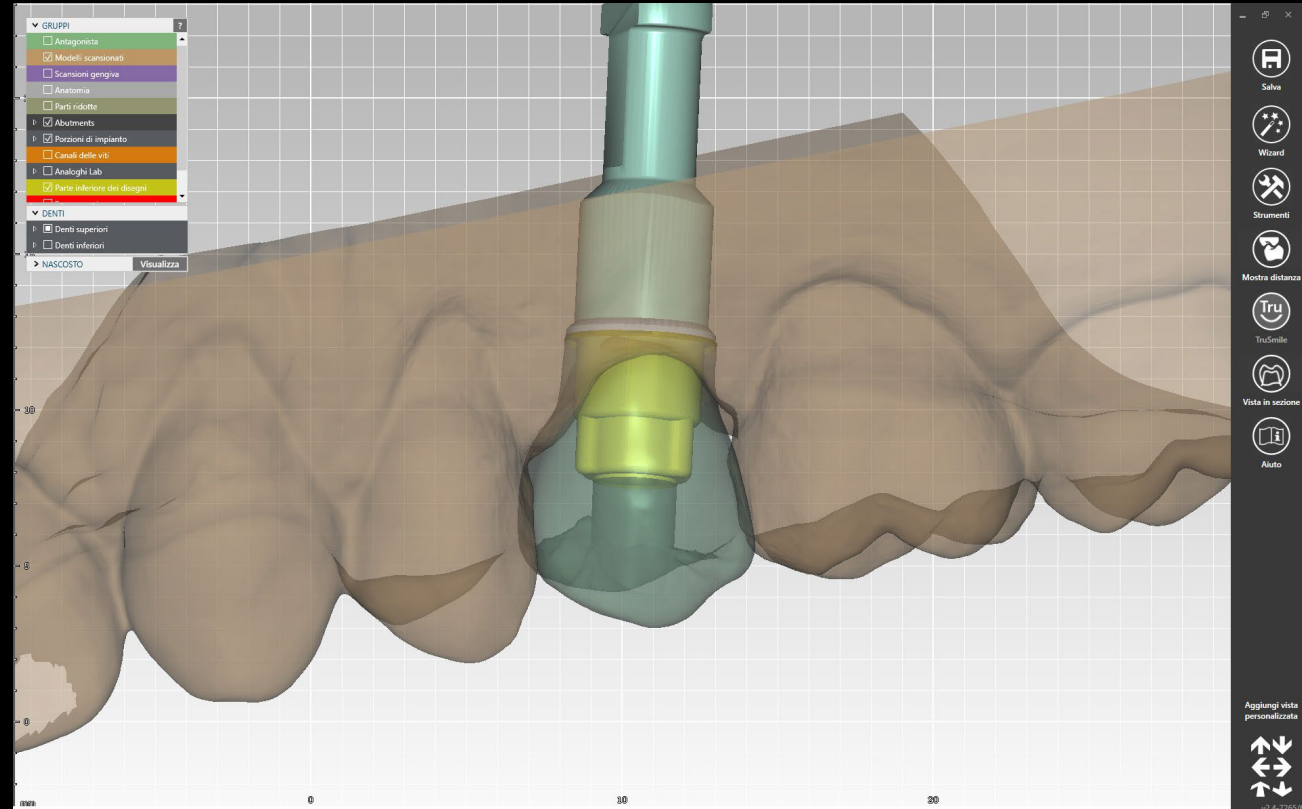
Initial clinical  
situation

Treatment  
planning

Surgical  
procedure

Restorative  
procedure

Outcome



**Initial clinical  
situation**

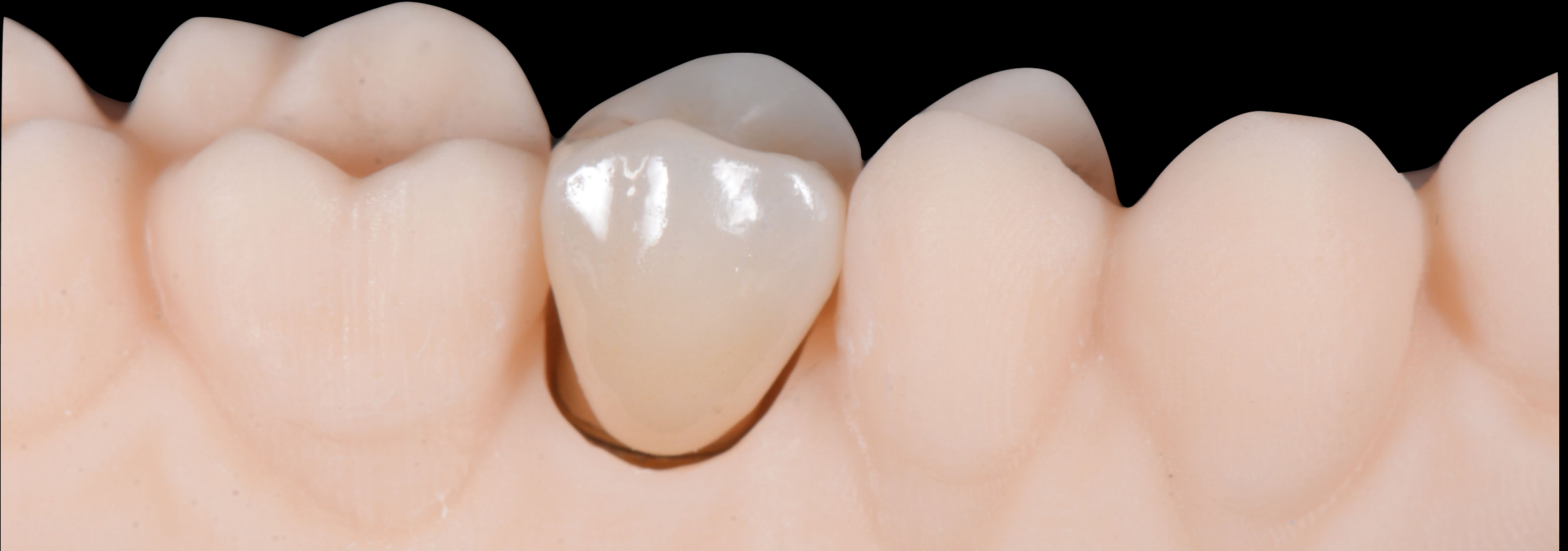**Treatment  
planning**

**Surgical  
procedure**

**Restorative  
procedure**

**Outcome**

**A NobelProcera® full-contour zirconia crown was cemented in the lab on the Universal Abutment in order to obtain a final screw-retained restoration.**





**Initial clinical  
situation**

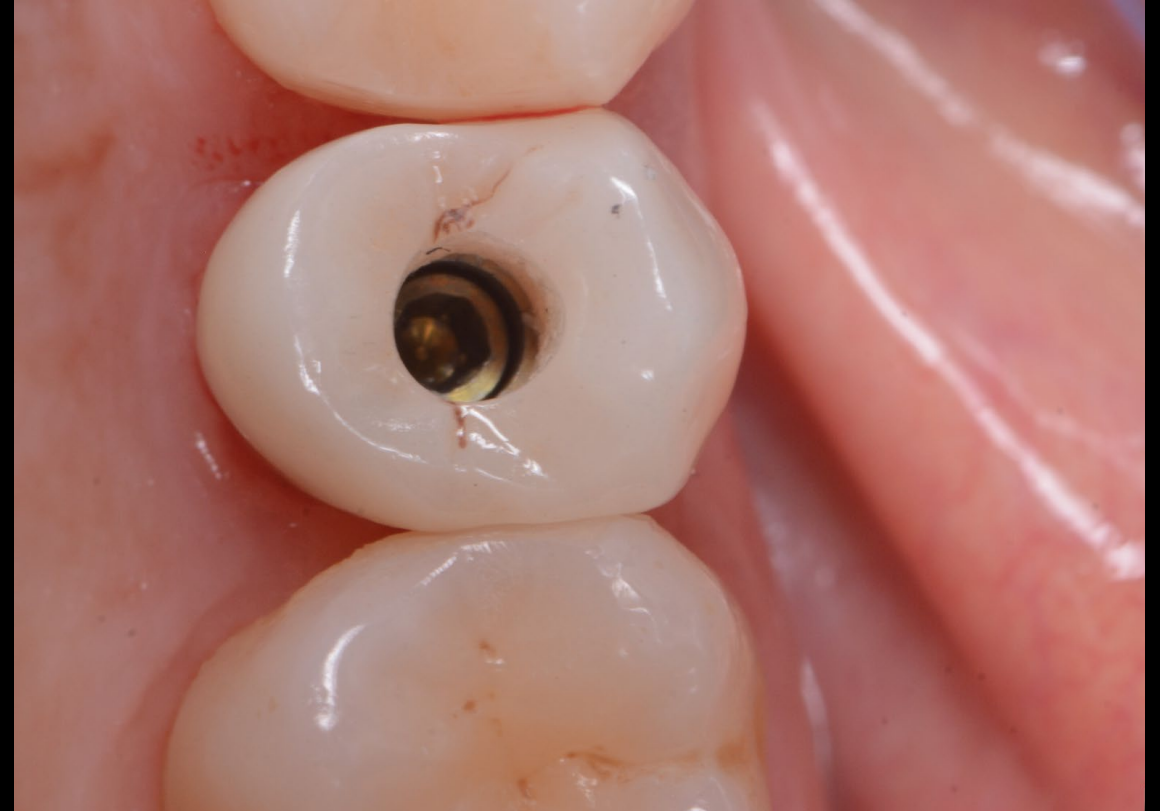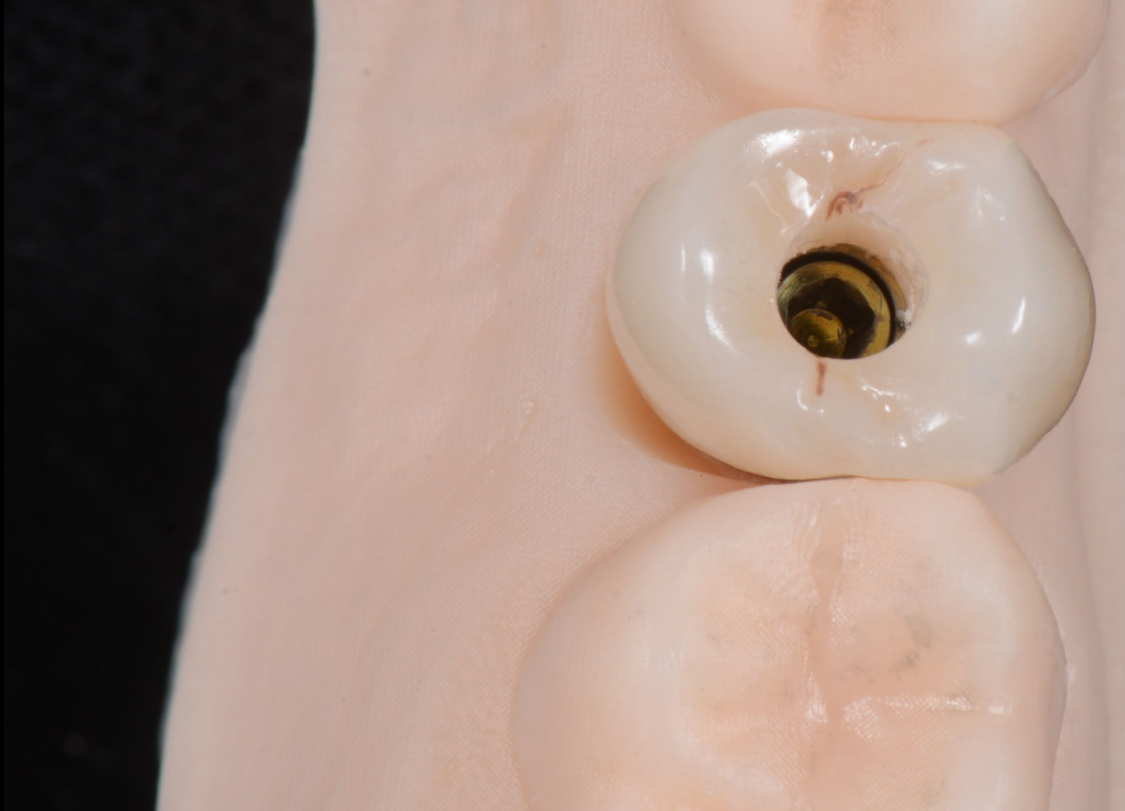**Treatment  
planning**

**Surgical  
procedure**

**Restorative  
procedure**

**Outcome**

**Occlusal view of the restoration on the 3D printed model and intraoral.**



**Initial clinical  
situation**

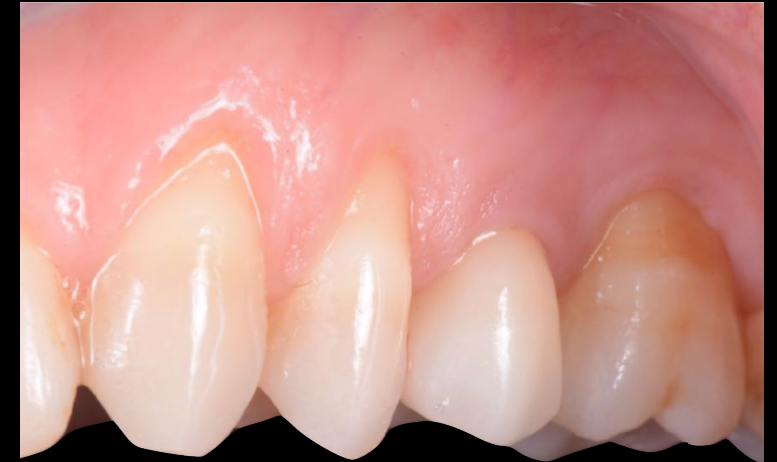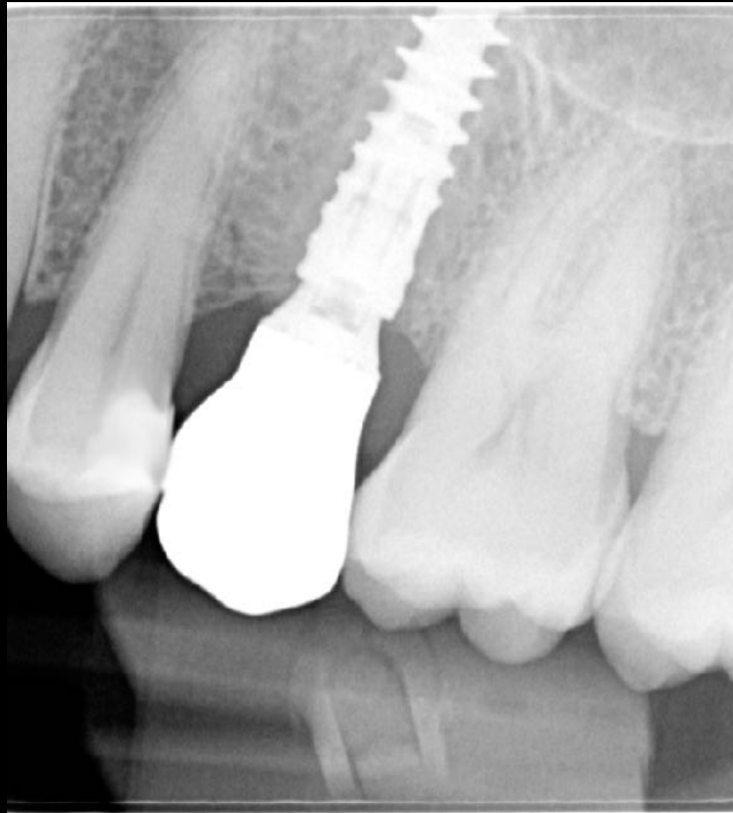
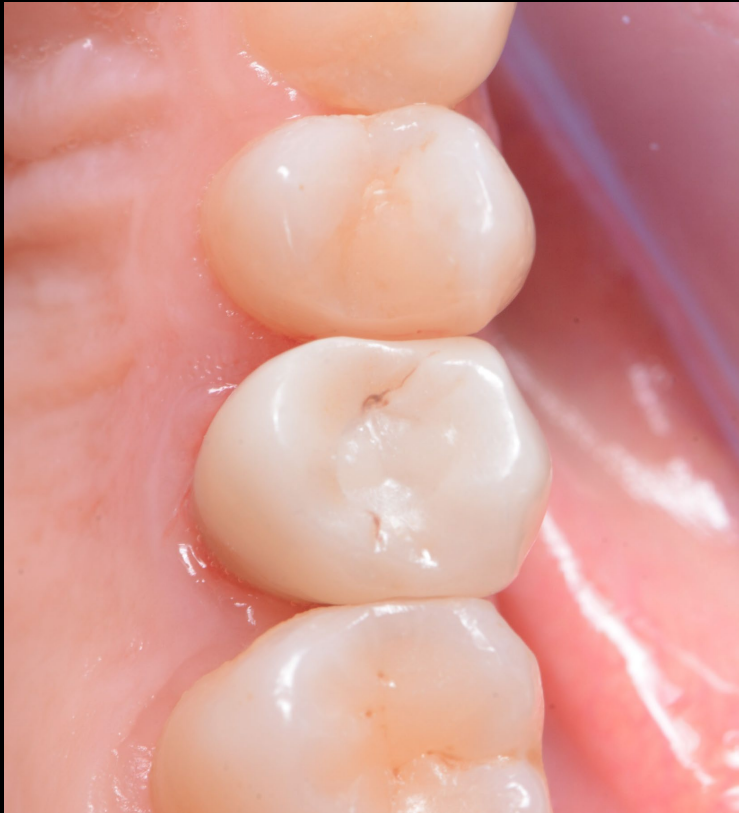**Treatment  
planning**

**Surgical  
procedure**

**Restorative  
procedure**

**Outcome**

**Final result: clinical views and X-ray show an excellent integration and stability. The marginal bone levels are ideal and the soft tissue architecture is correct. The screw access channel was closed with Teflon and composite.**



**Initial clinical  
situation**

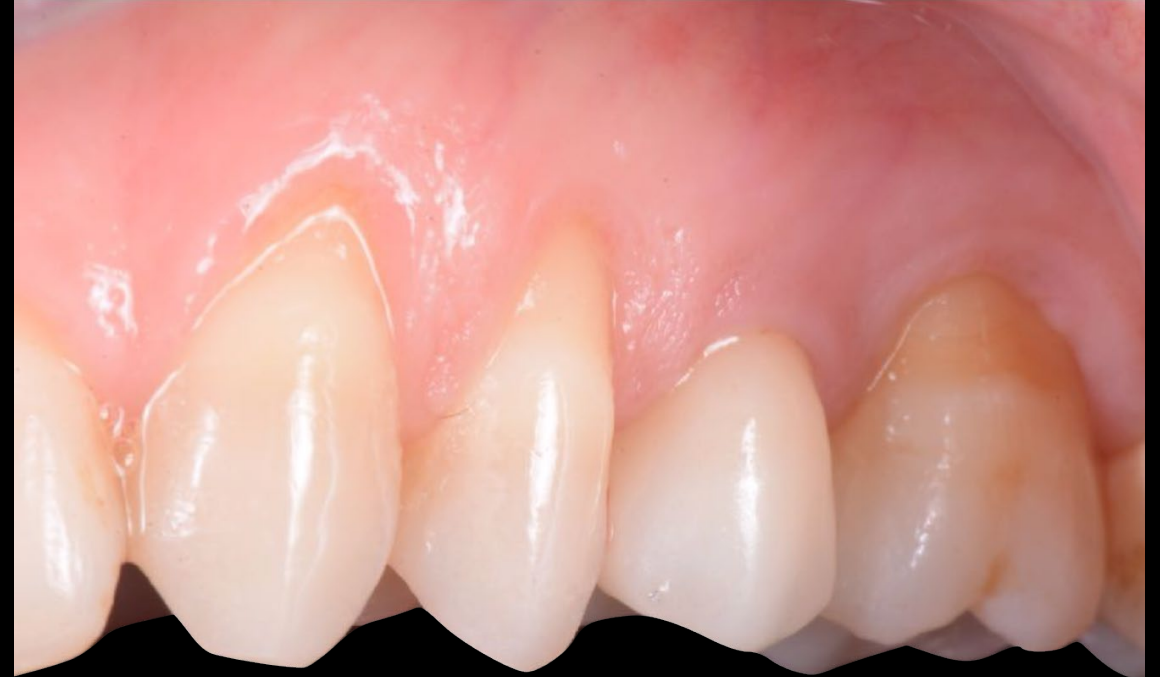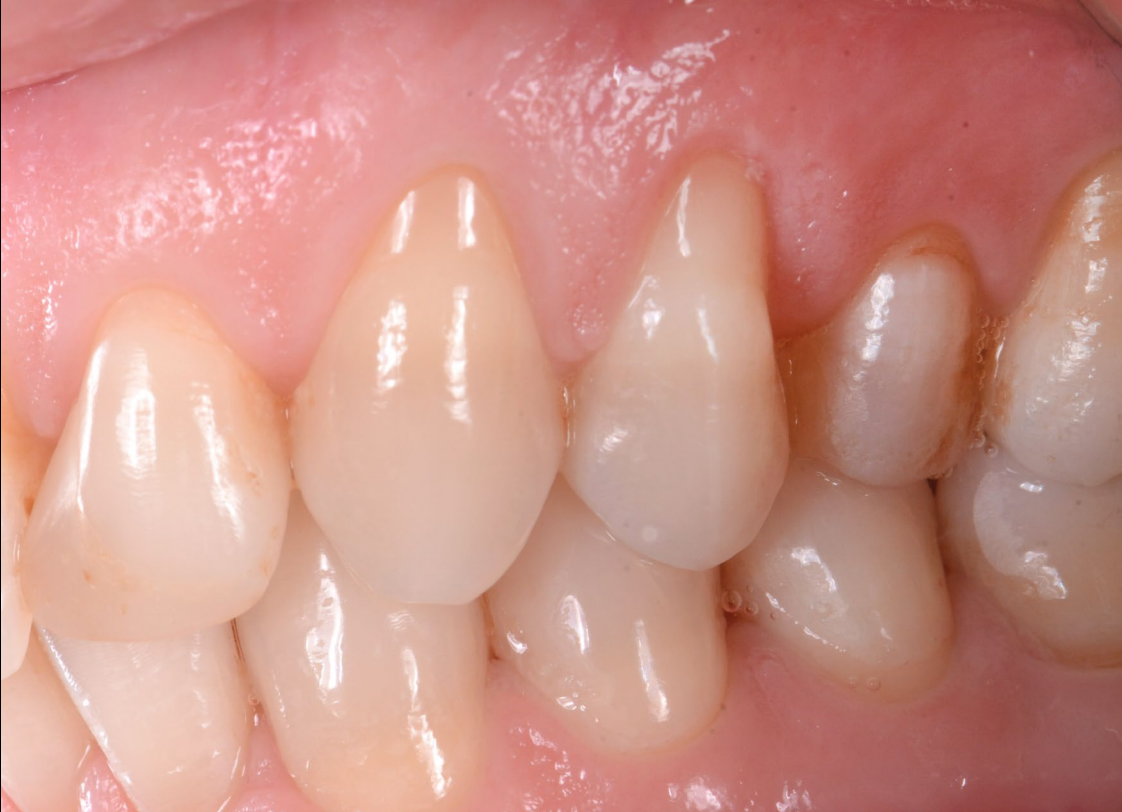**Treatment  
planning**

**Surgical  
procedure**

**Restorative  
procedure**

**Outcome**

**Initial situation and the final result: clinical views show an excellent integration stability.**





**Initial clinical  
situation**

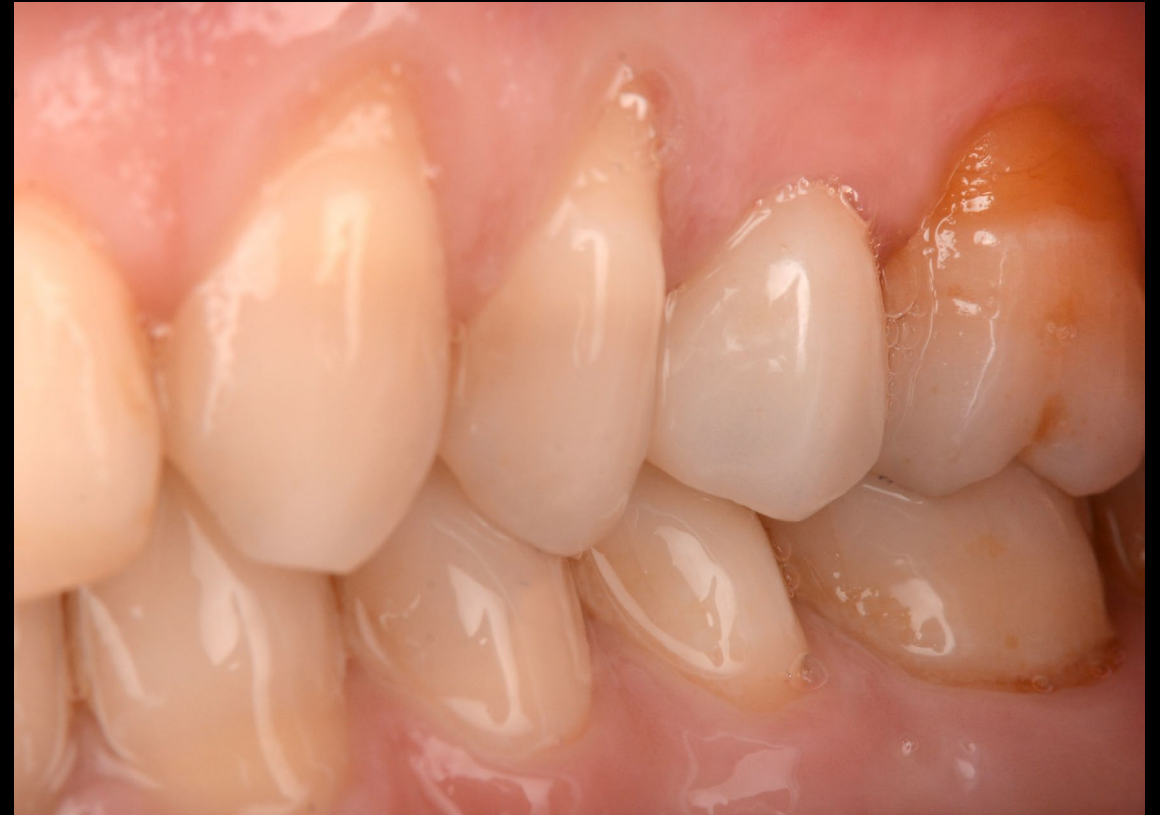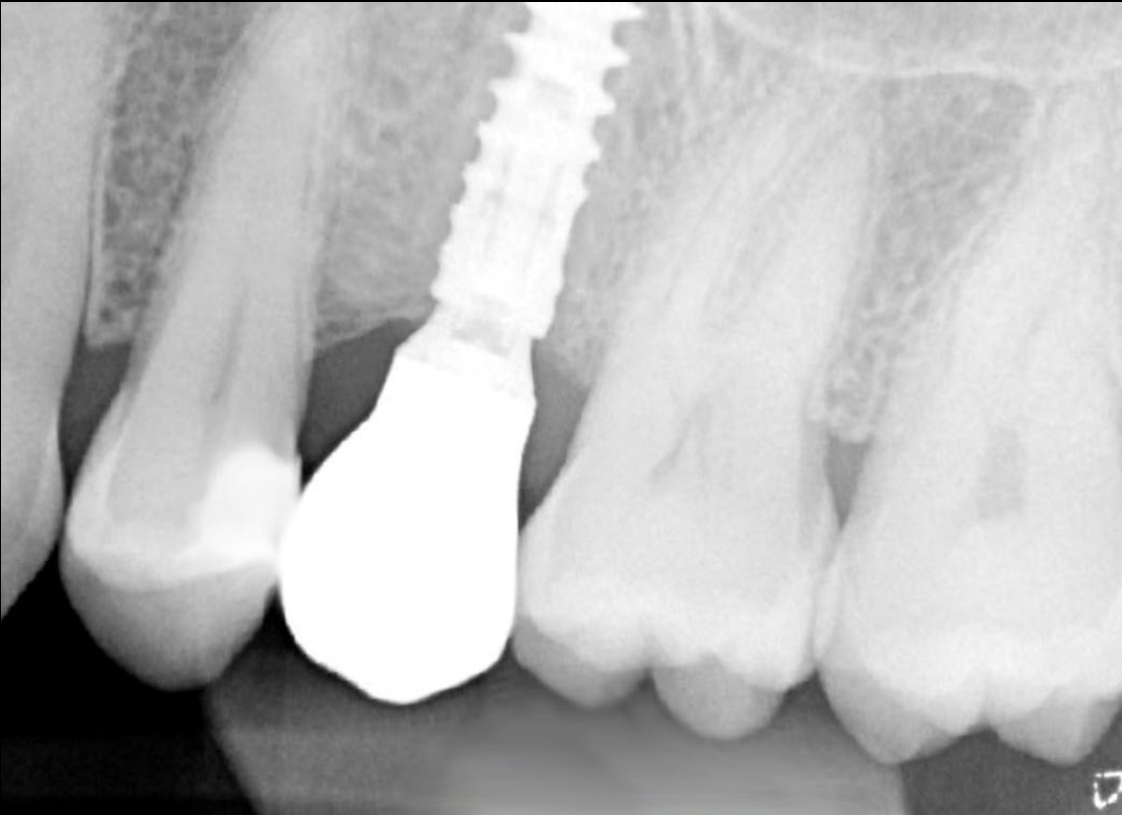**Treatment  
planning**

**Surgical  
procedure**

**Restorative  
procedure**

**Outcome**

**X-ray and clinical evaluation after 9 months of function.  
Note the excellent bone and soft tissue health.**



**Case courtesy of Dr. Giacomo Fabbri**



GMT 84725 GB 2208 © Nobel Biocare Services AG, 2022. All rights reserved. Nobel Biocare, the Nobel Biocare logotype and all other trademarks are, if nothing else is stated or is evident from the context in a certain case, trademarks of Nobel Biocare. Please refer to [nobelbiocare.com/trademarks](https://nobelbiocare.com/trademarks) for more information. Product images are not necessarily to scale. Disclaimer: Some products may not be regulatory cleared/released for sale in all markets. Please contact the local Nobel Biocare sales office for current product assortment and availability. For prescription use only. Caution: Federal (United States) law restricts this device to sale by or on the order of a licensed clinician, medical professional or physician. See Instructions For Use for full prescribing information, including indications, contraindications, warnings and precautions. Nobel Biocare does not take any liability for any injury or damage to any person or property arising from the use of this clinical case. This clinical case is not intended to recommend any measures, techniques, procedures or products, or give advice, and is not a substitute for medical training or your own clinical judgement as a healthcare professional. Viewers should never disregard professional medical advice or delay seeking medical treatment because of something they have seen in this clinical case. Full procedure is not shown. Certain sequences have been cut.