

Bi-maxillary full-arch edentulous restoration with immediate loading using X-Guide® navigated surgery, and X-Act Teeth pre-fabricated provisional technique

Dr. Renaud Noharet
France





Dr. Renaud Noharet

Patient description:

53 years old, female, no systemic diseases, no oral pathology, presents with esthetic and functional complaints.

Clinical situation:

Missing and mobile teeth in the maxilla and mandible impacting functional and esthetic outcomes. Severe periodontitis.

Surgical solution:

Extraction of remaining upper and lower teeth, immediate implant placement with N1™ implant system using navigated surgery with X-guide®, then immediate loading with pre-fabricated provisional using X-Act teeth technique.

Temporization:

Immediate loading with printed/milled provisional connected on Multi-unit Abutment.

Surgery date(s):

First surgery : April 17, 2023
Second surgery :
September 4, 2023

Total treatment time:

Phase 1 with 4 months follow-up

Tooth position(s):

Full-arch rehabilitation in the maxilla and mandible

“Using navigation technology has been a game-changer for our surgical procedures. It provides real-time assistance during implant placement ensuring precision and safety. Moreover, it streamlines the immediate loading phase, allowing patients to receive temporary prosthetics faster. This comprehensive workflow significantly improves the efficiency and predictability of complex full-arch rehabilitations, leading to an enhanced experience for our patients.”

Dr. Renaud Noharet

More on X-Act Teeth
protocol



**Data
collection**

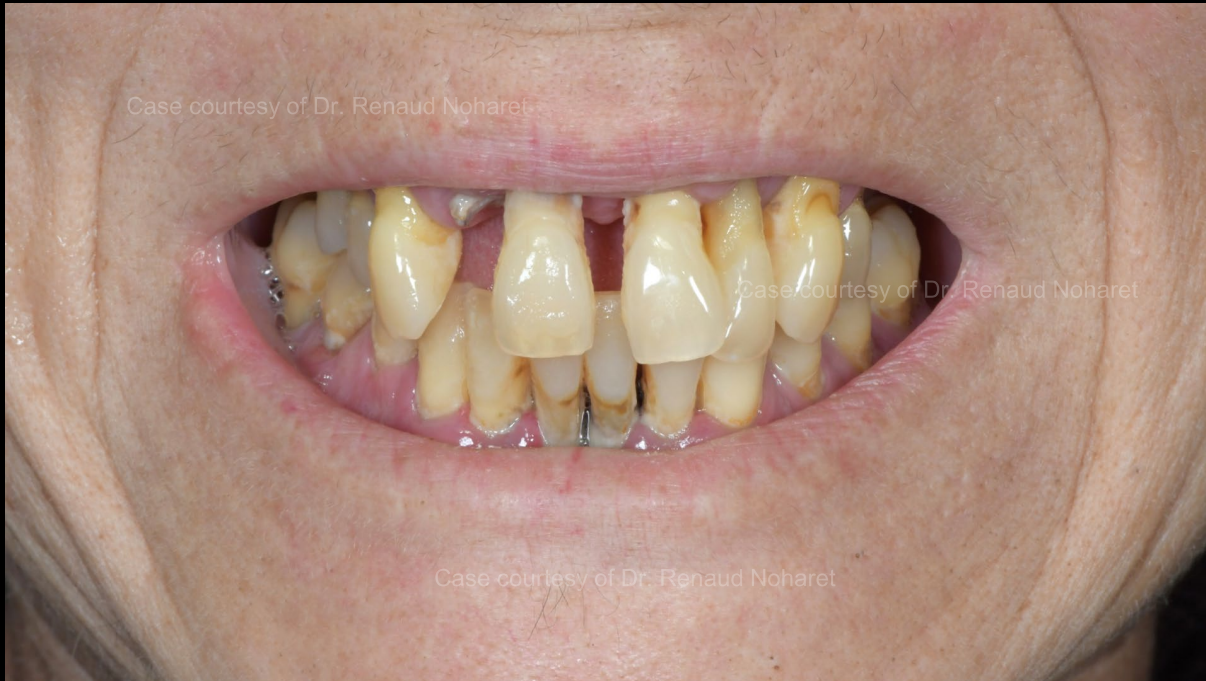**Treatment
planning**

**Surgical
procedure**

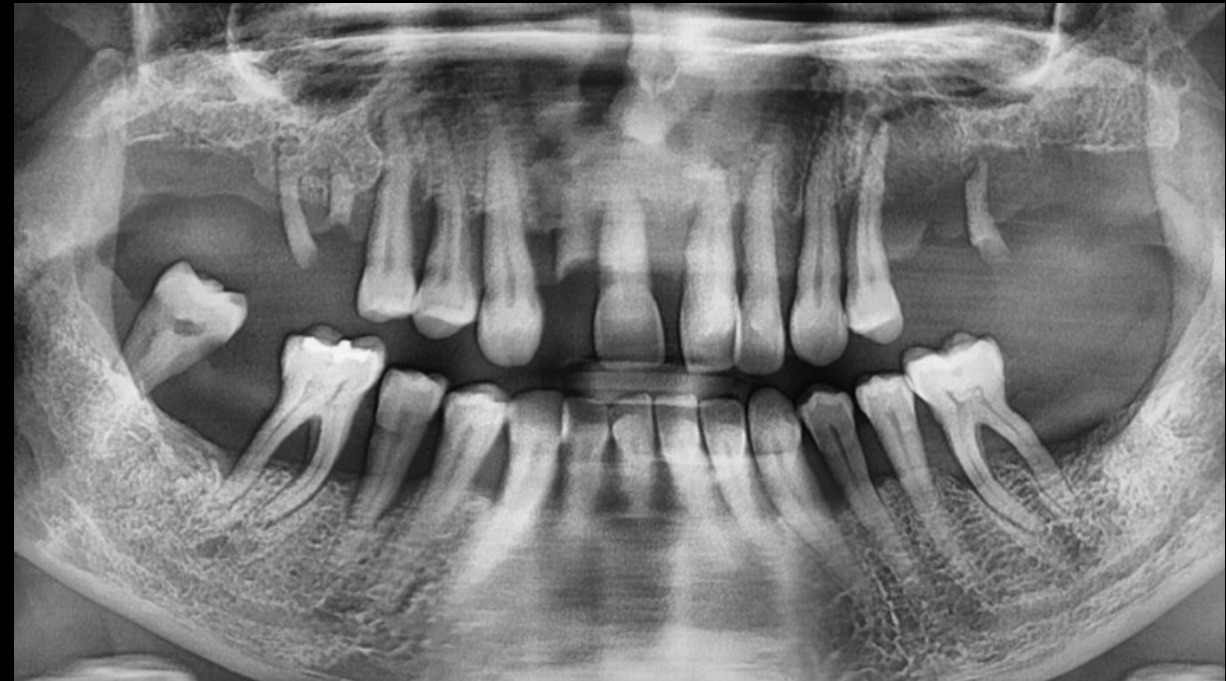
**Post-surgical
impression**

**Immediate
loading**

**Digital records and
final restoration**



Initial situation.



Pre-op orthopantomogram (OPG).

**Data
collection**

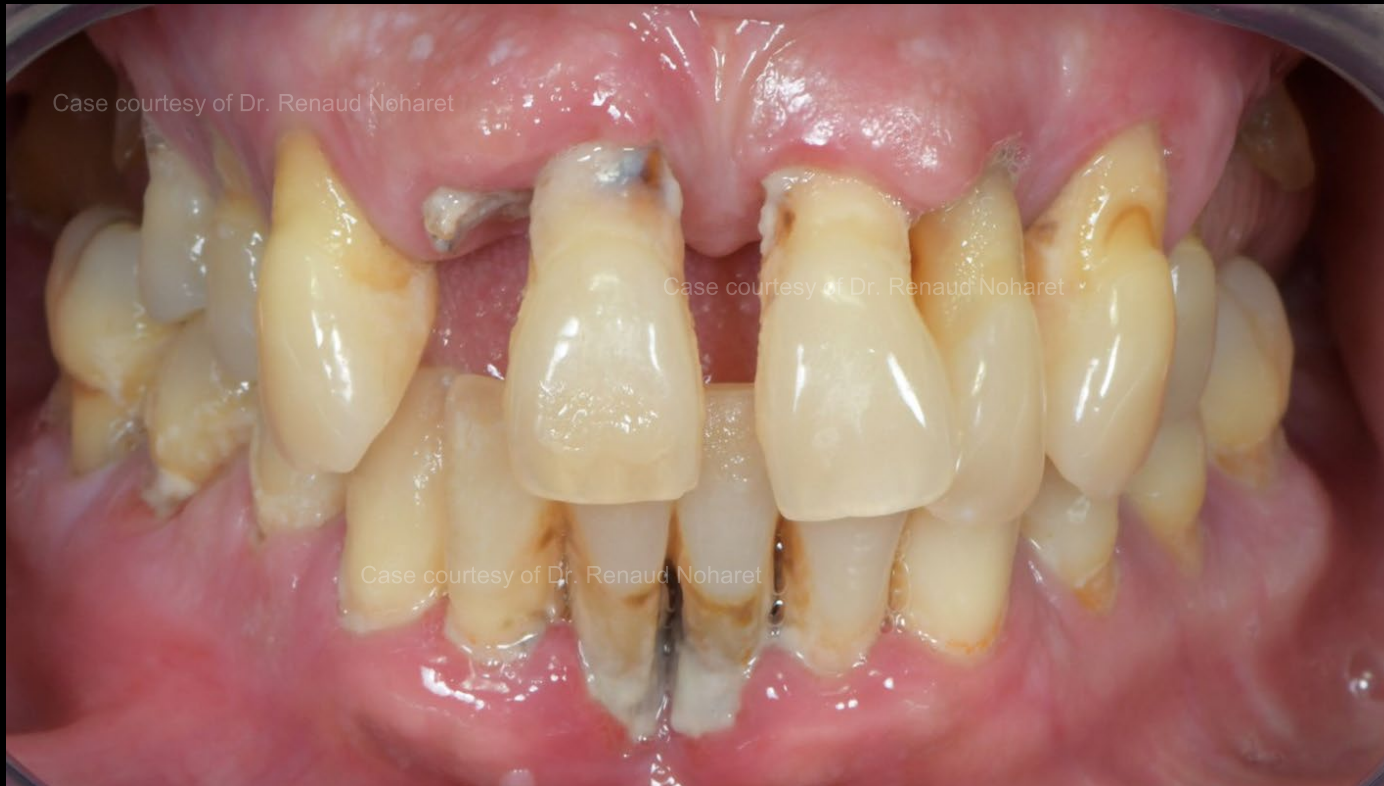**Treatment
planning**

**Surgical
procedure**

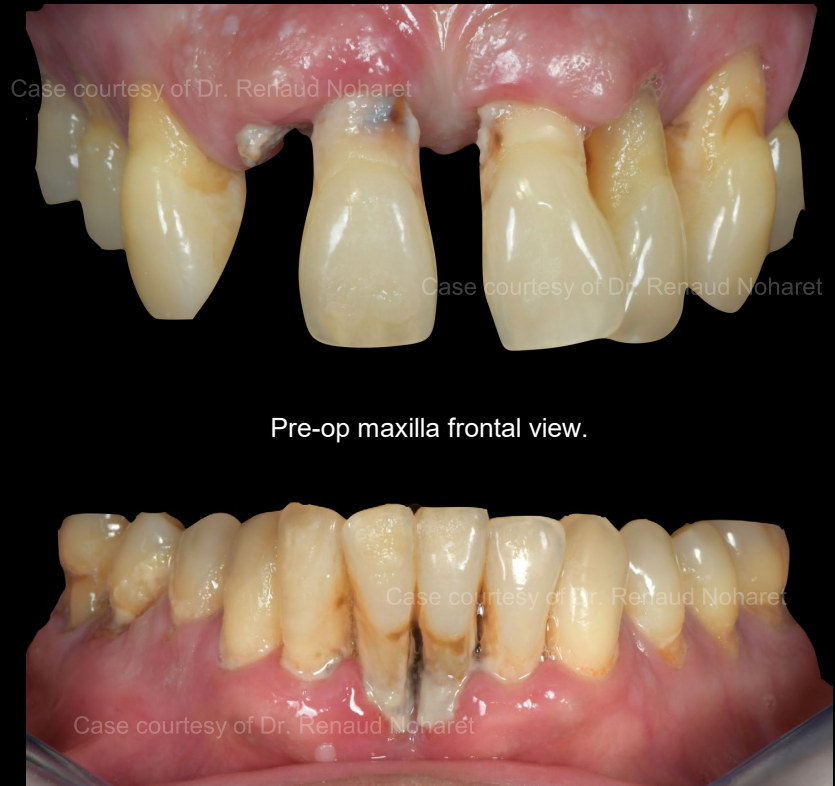**Post-surgical
impression**

**Immediate
loading**

**Digital records and
final restoration**



Pre-op bite frontal view.



Pre-op maxilla frontal view.

Pre-op mandible frontal view.

**Data
collection**

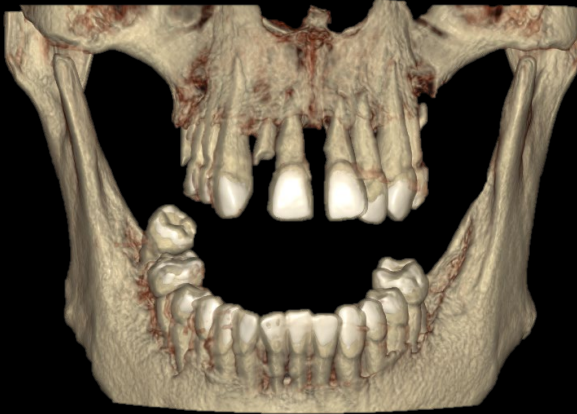
**Treatment
planning**

**Surgical
procedure**

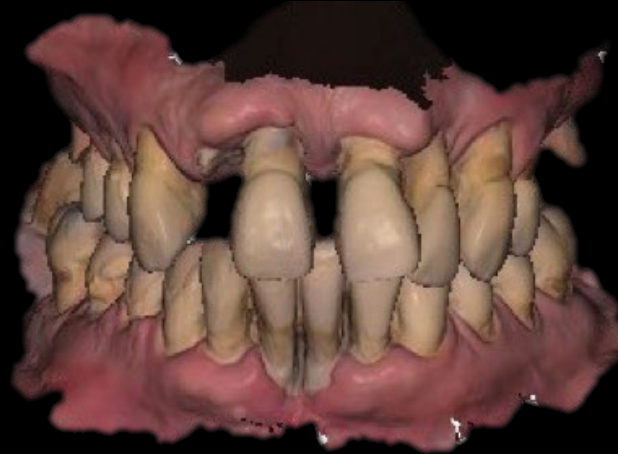**Post-surgical
impression**

**Immediate
loading**

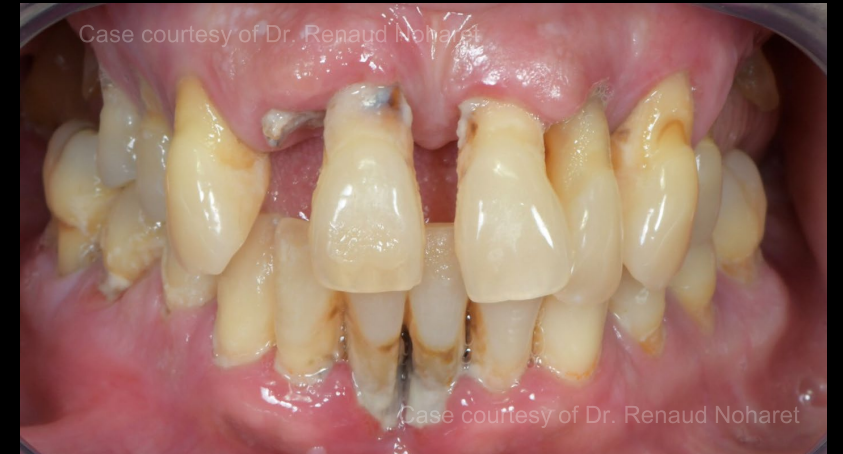**Digital records and
final restoration**



DICOM file.



PLY scan.



Clinical pictures.



DTX Studio™ Suite

**Data
collection**

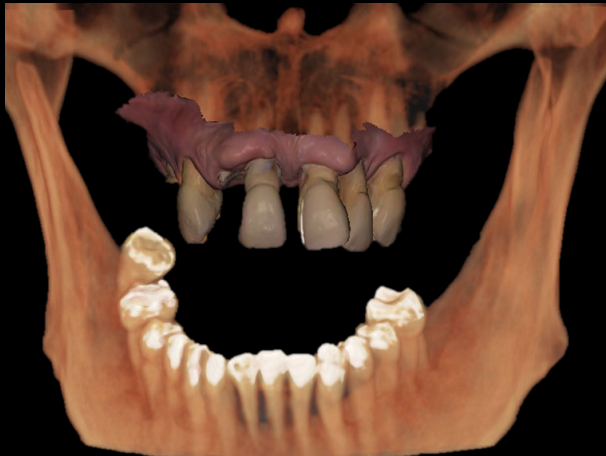**Treatment
planning**

**Surgical
procedure**

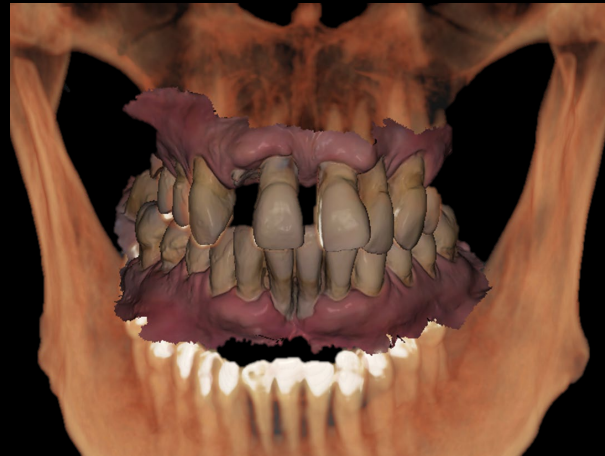**Post-surgical
impression**

**Immediate
loading**

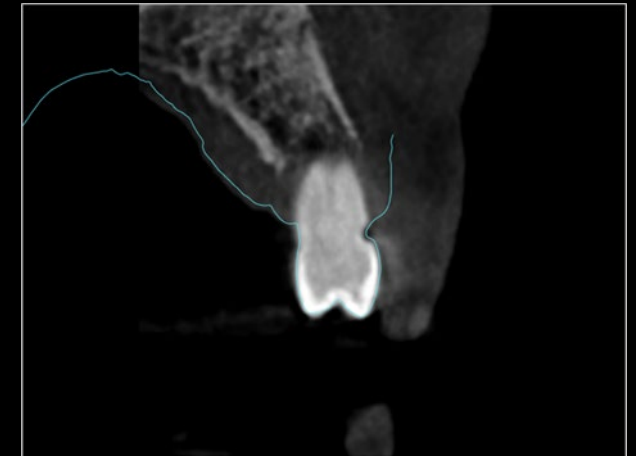**Digital records and
final restoration**



Merging DICOM & PLY files.



Merging DICOM & PLY with intraoral images.



Cross section alignment between DICOM & PLY scan



DTX Studio™ Suite

Data
collection

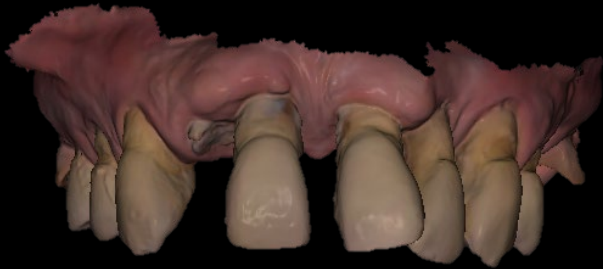Treatment
planning

Surgical
procedure

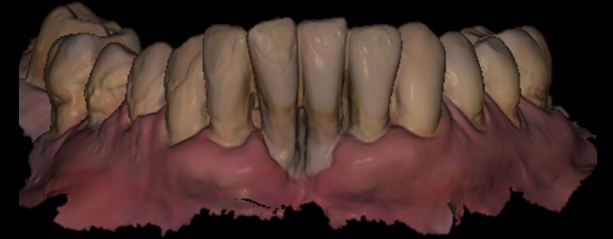
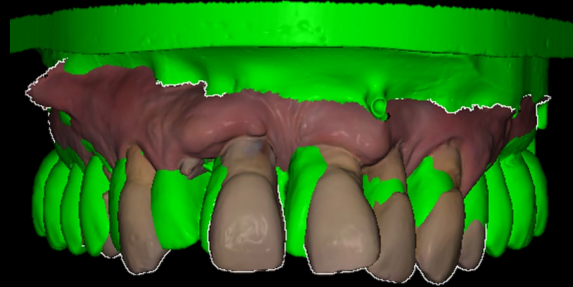
Post-surgical
impression

Immediate
loading

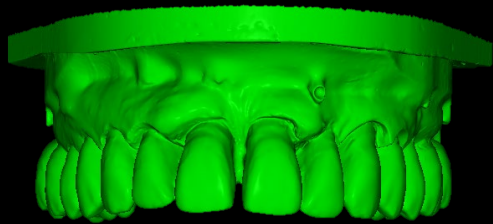Digital records and
final restoration



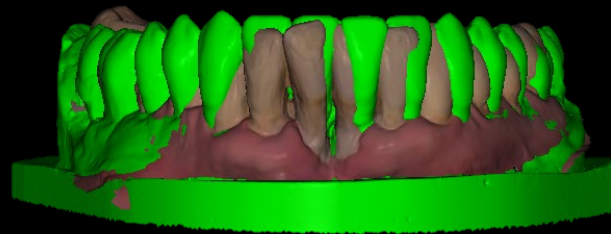
Pre-op maxillary PLY scan.



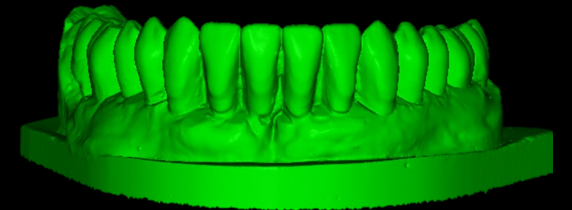
Pre-op mandibular PLY scan.



Prosthetic wax-up STL of maxilla shared by the dental lab.



Prosthetic wax-up merged with initial intraoral situation.



Prosthetic wax-up STL of mandible shared by the dental lab.

Data
collection


Treatment
planning

Surgical
procedure

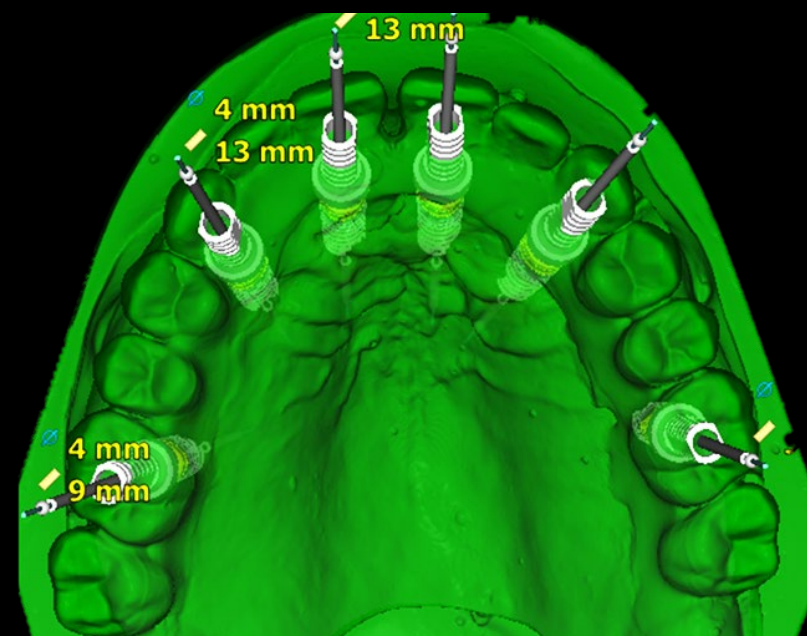
Post-surgical
impression

Immediate
loading

Digital records and
final restoration



Frontal view of N1™ implants 4 x 13 mm planned in maxilla.



Occlusal view of N1™ implants 4 x 13 mm planned in maxilla.

Data
collection


Treatment
planning

Surgical
procedure

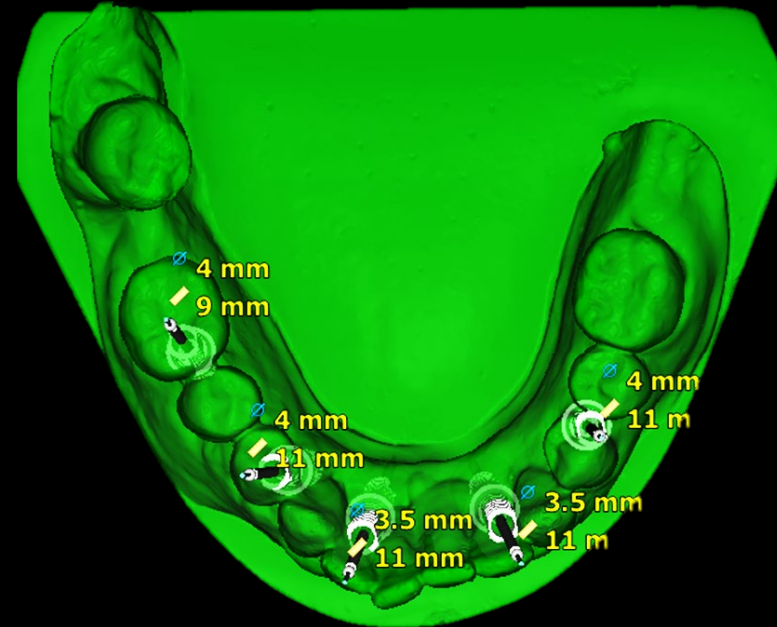
Post-surgical
impression

Immediate
loading

Digital records and
final restoration



Frontal view of N1™ implants 4 x 13 mm planned in mandible with Multi-unit Abutment.



Occlusal view of N1™ implants 4 x 13 mm planned in mandible with Multi-unit Abutment.

Data
collection

**Treatment
planning**

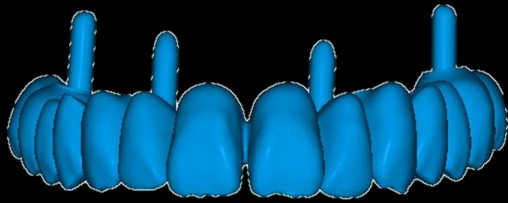
Surgical
procedure

Post-surgical
impression

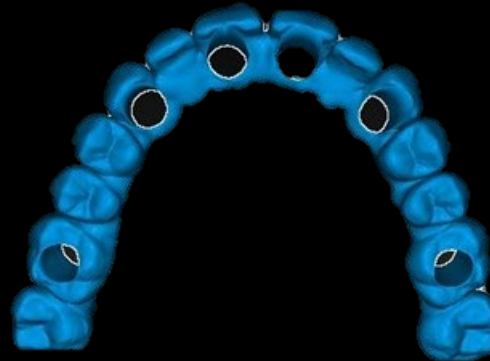
Immediate
loading

Digital records and
final restoration

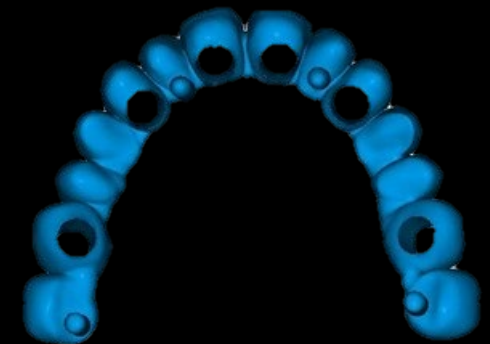
Finalization of the prosthetic wax-up, including the insertion of bone landing pins using in DTX Studio™ Lab or exocad DentalCAD® software



Frontal view of prosthetic wax-up with 4 insertion bone pins ready for printing before surgery.



Occlusal view of prosthetic wax-up with 4 insertion bone pins ready for printing before surgery.



Intaglio surface view of prosthetic wax-up with 4 insertion bone pins ready for printing before surgery.



DTX Studio™ Lab

Data
collection

Treatment
planning

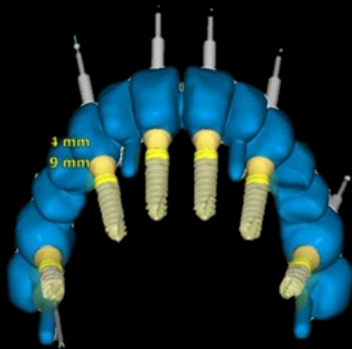
Surgical
procedure

Post-surgical
impression

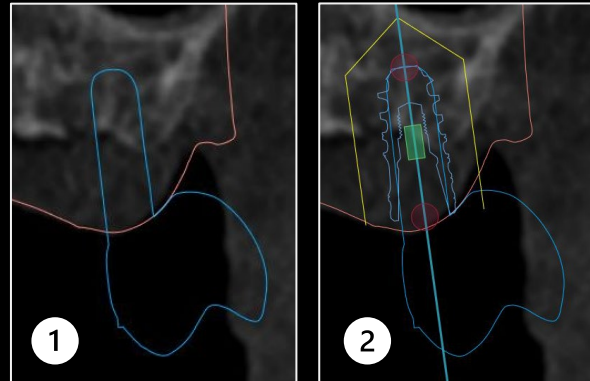
Immediate
loading

Digital records and
final restoration

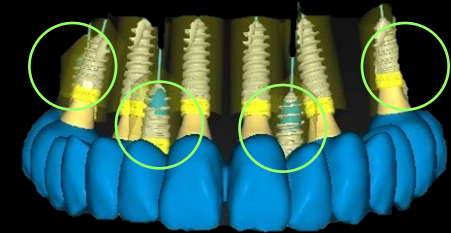
Definition inserted bone landing pins as implants in DTX Studio™ Implant software



Import of prosthetic wax-up in DTX Studio™ Implant
for referencing the insertion bone landing pins.



Cross section of the bone landing pins (1), followed
by implant placement selection to define both depth
and diameter (2).



All bone pins defined as implants in the implant
planning project before exporting the treatment plan
into X-guide® for surgical execution.



DTX Studio™ Implant

Data
collection

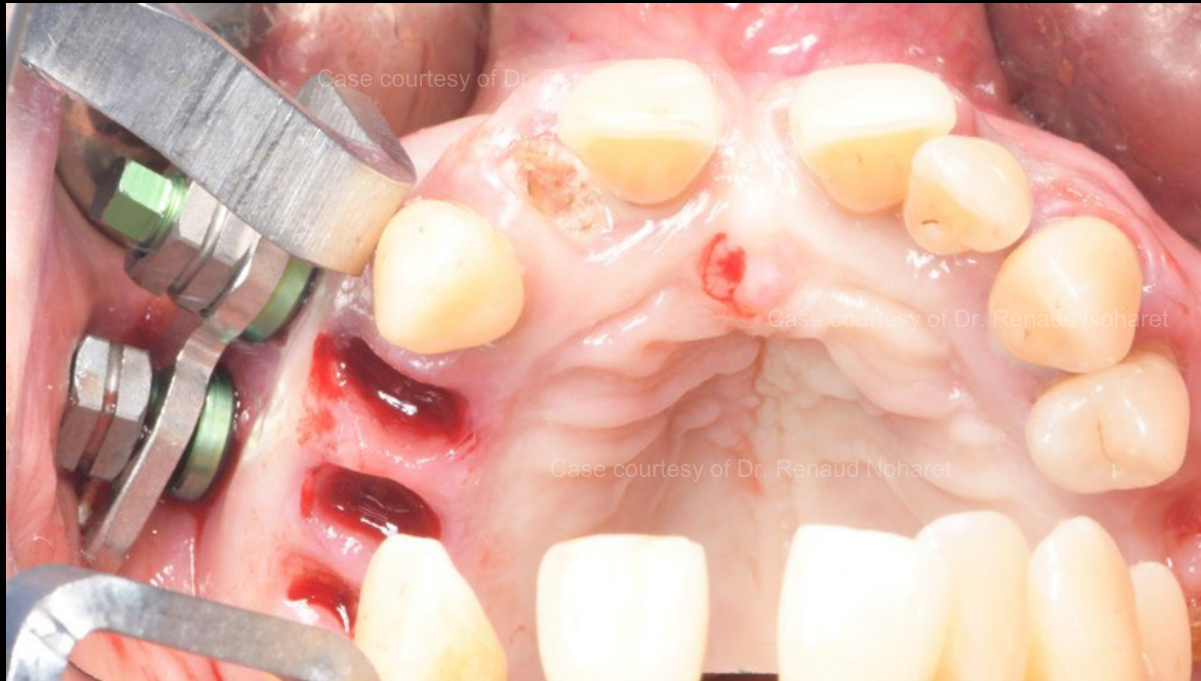Treatment
planning

Surgical
procedure

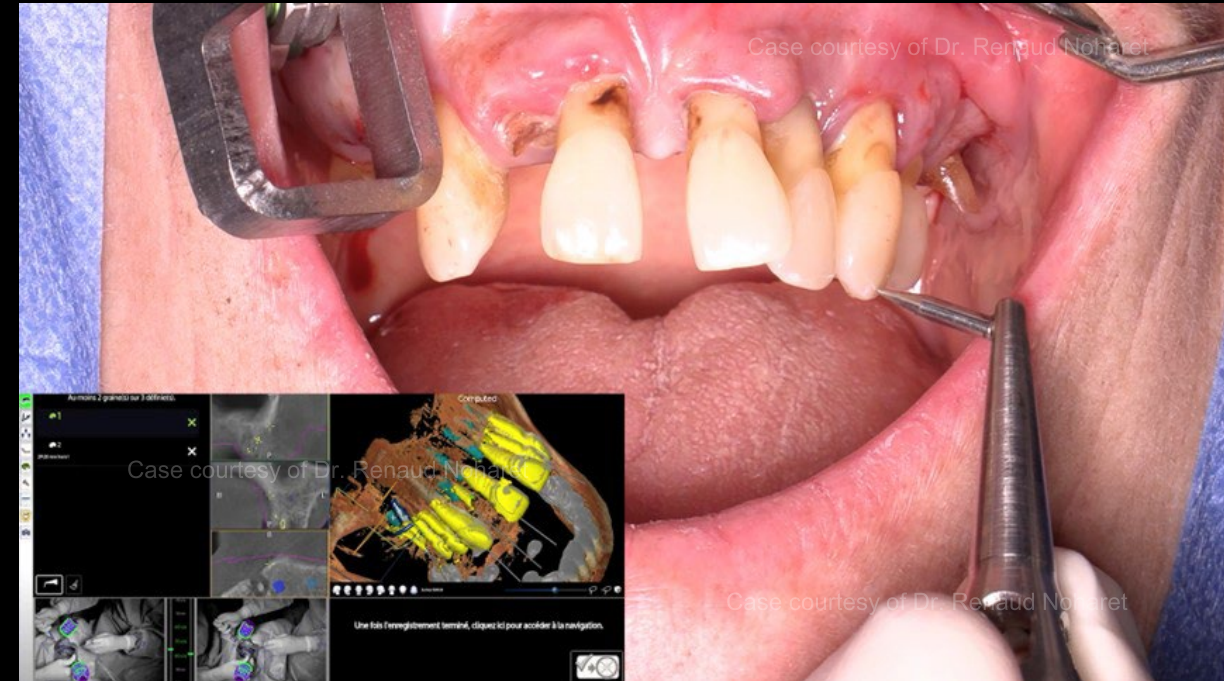
Post-surgical
impression

Immediate
loading

Digital records and
final restoration



Fixing X-Guide® tracker with EDX screws in the patient's upper jaw to prepare for X-Mark™ protocol*.



Calibration following X-Mark™ protocol (identification of clear reference points to calibrate accuracy of X-Guide®)

*The tracker is carefully placed such that no interference occurs when placing implants.

Data
collection

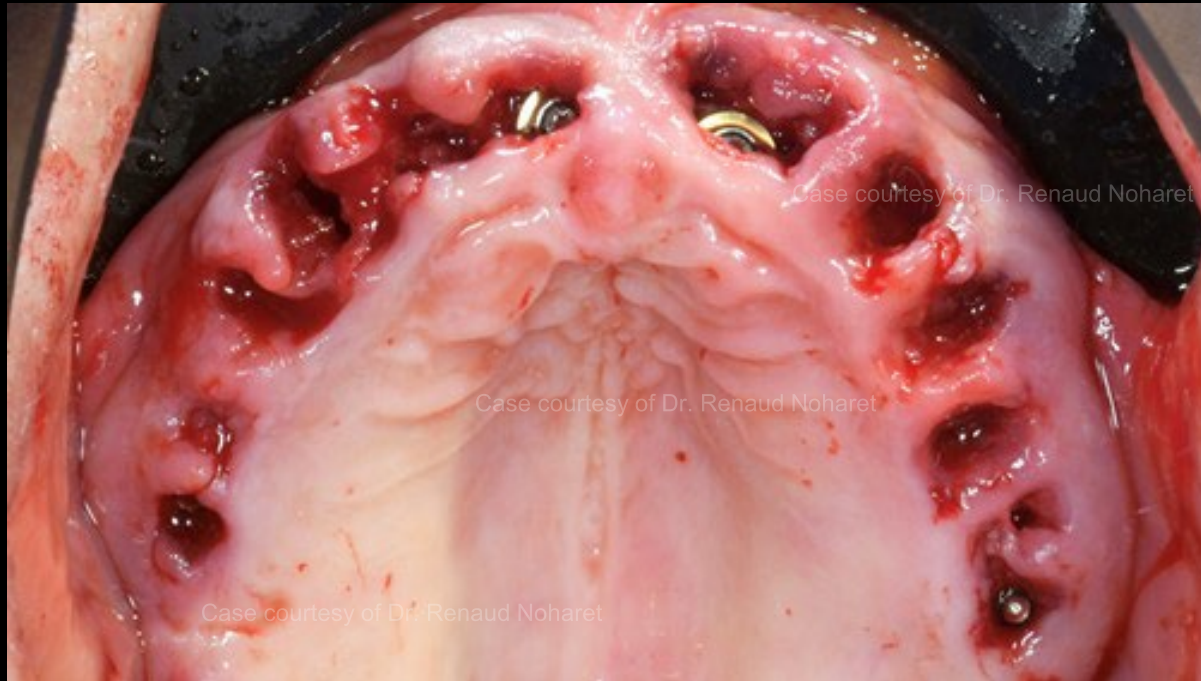Treatment
planning

**Surgical
procedure**

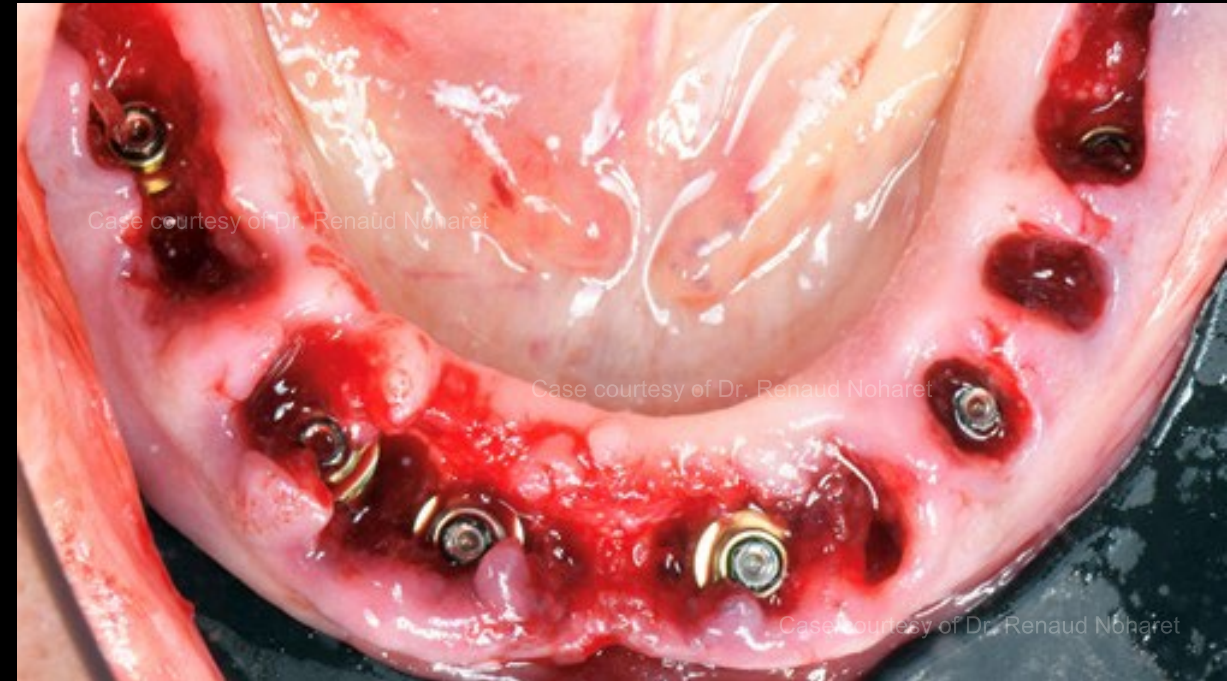Post-surgical
impression

Immediate
loading

Digital records and
final restoration



Extraction, immediate implant placement and Multi-unit Abutment placed in the maxilla*.



Extraction, immediate implant placement, and Multi-unit Abutment placed in the mandible.

*Additional osteotomies were performed to host the defined landing pins, allowing predictable prosthesis positioning

Data
collection

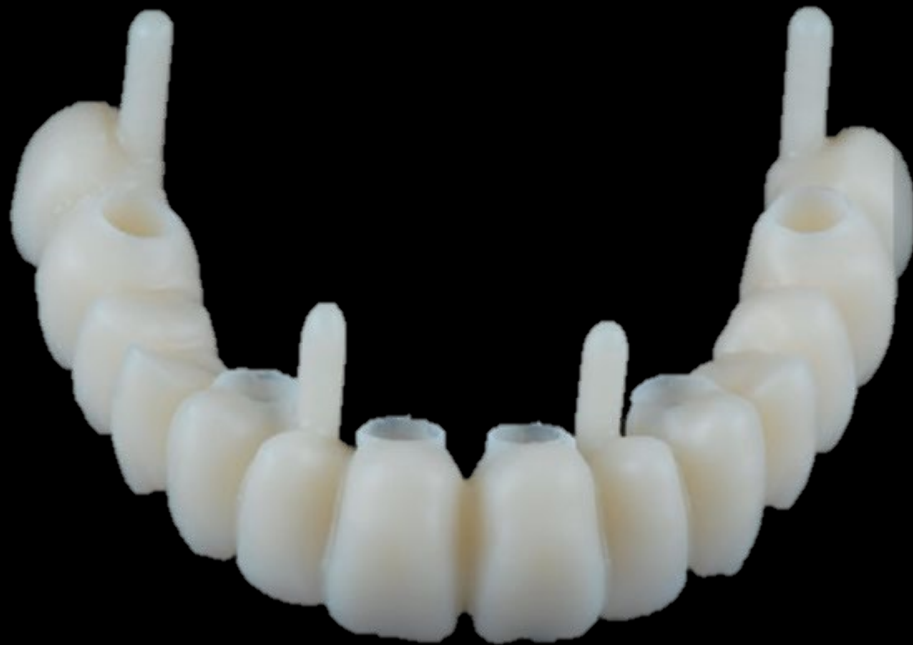Treatment
planning

**Surgical
procedure**

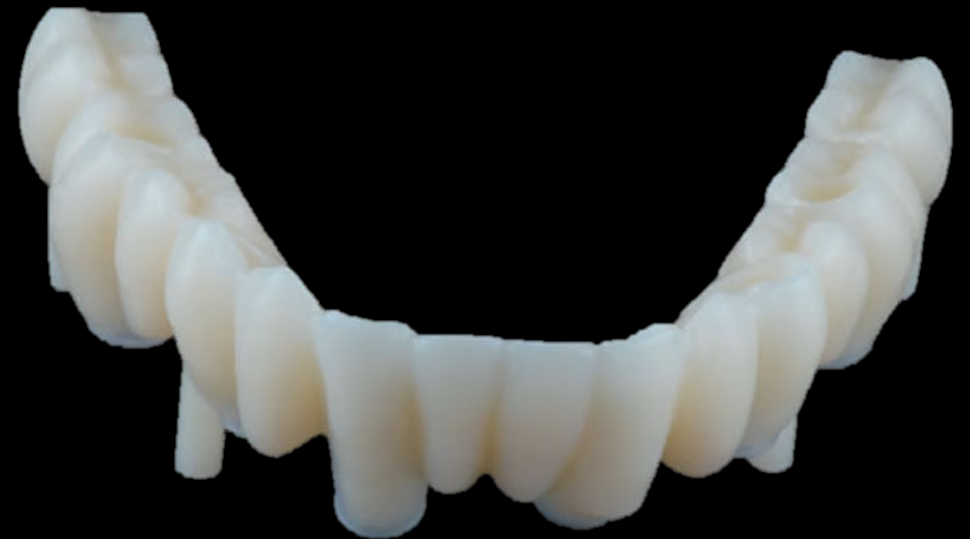Post-surgical
impression

Immediate
loading

Digital records and
final restoration



PMMA milled provisional for maxilla.



PMMA milled provisional for mandible.

Data
collection

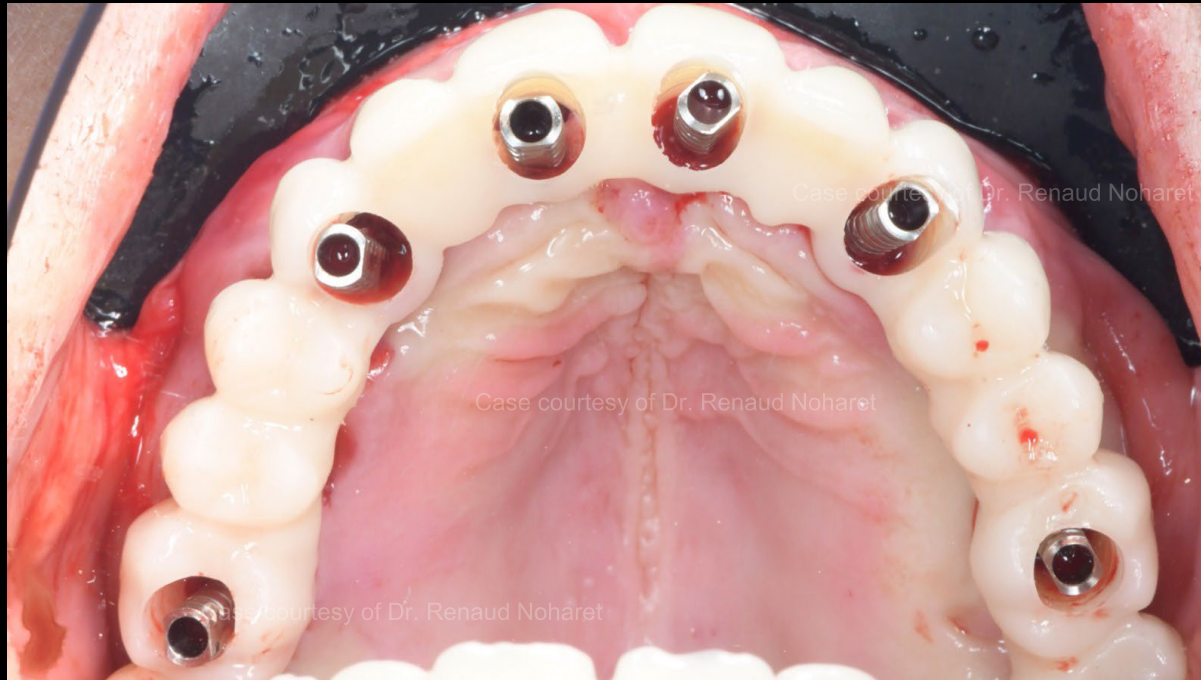Treatment
planning

Surgical
procedure

Post-surgical
impression

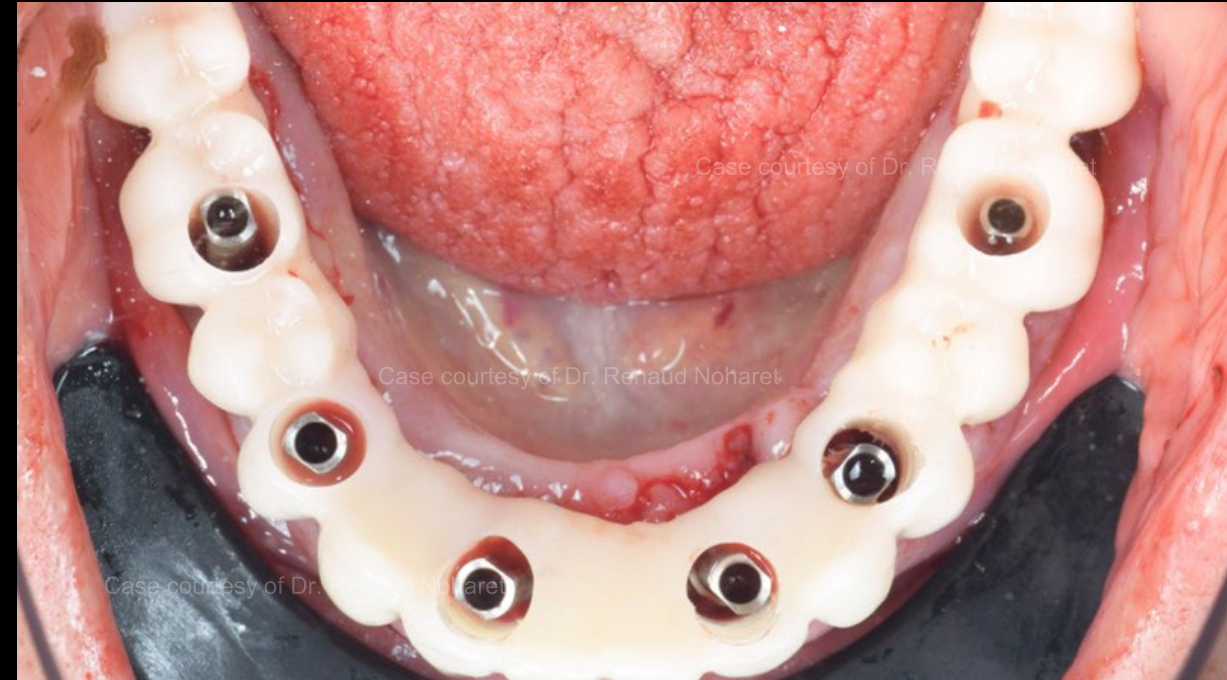
**Immediate
loading**

Digital records and
final restoration



Maxilla

Pre-fabricated temporary seated on top of temporary Multi-unit Abutment –
ready for conversion*



Mandible

Pre-fabricated temporary seated on top of temporary Multi-unit Abutment –
ready for conversion

*Composite flow must be injected within residual hole area to consolidate temporary Multi Unit Abutments and the corresponding provisional

Data
collection

Treatment
planning

Surgical
procedure

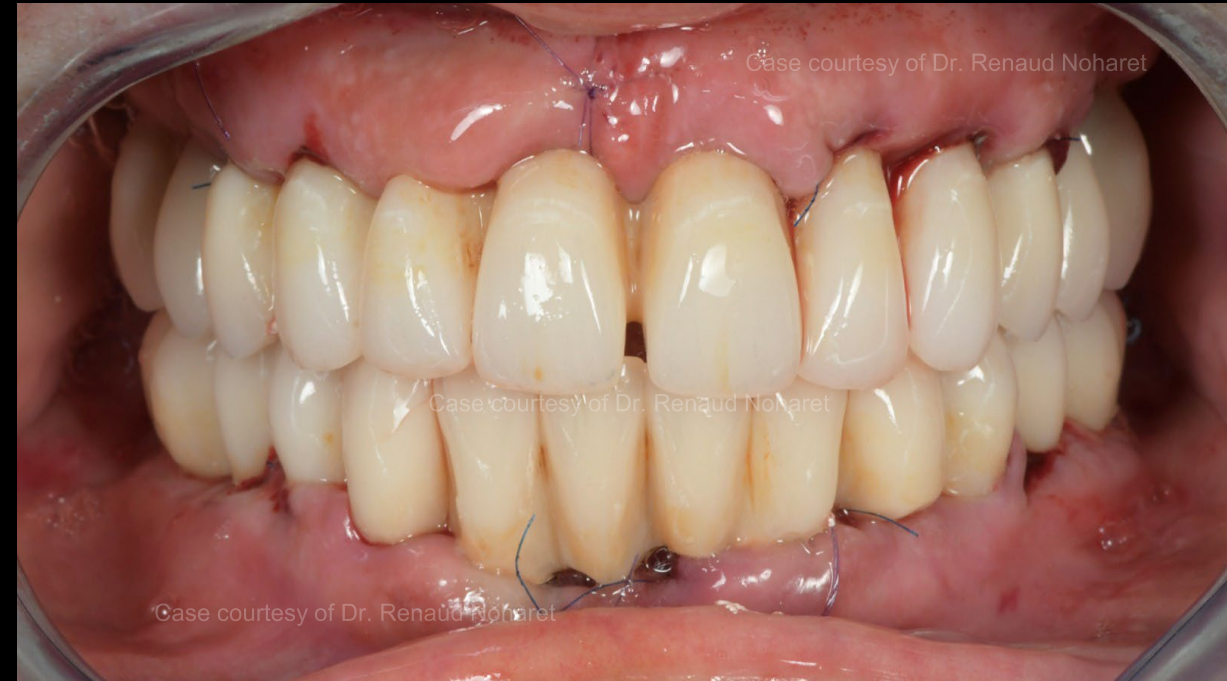Post-surgical
impression

**Immediate
loading**

Digital records and
final restoration



Provisionals post-conversion (landing pins removed post-conversion).



Provisionals placed 4 hours after surgery.

Data
collection

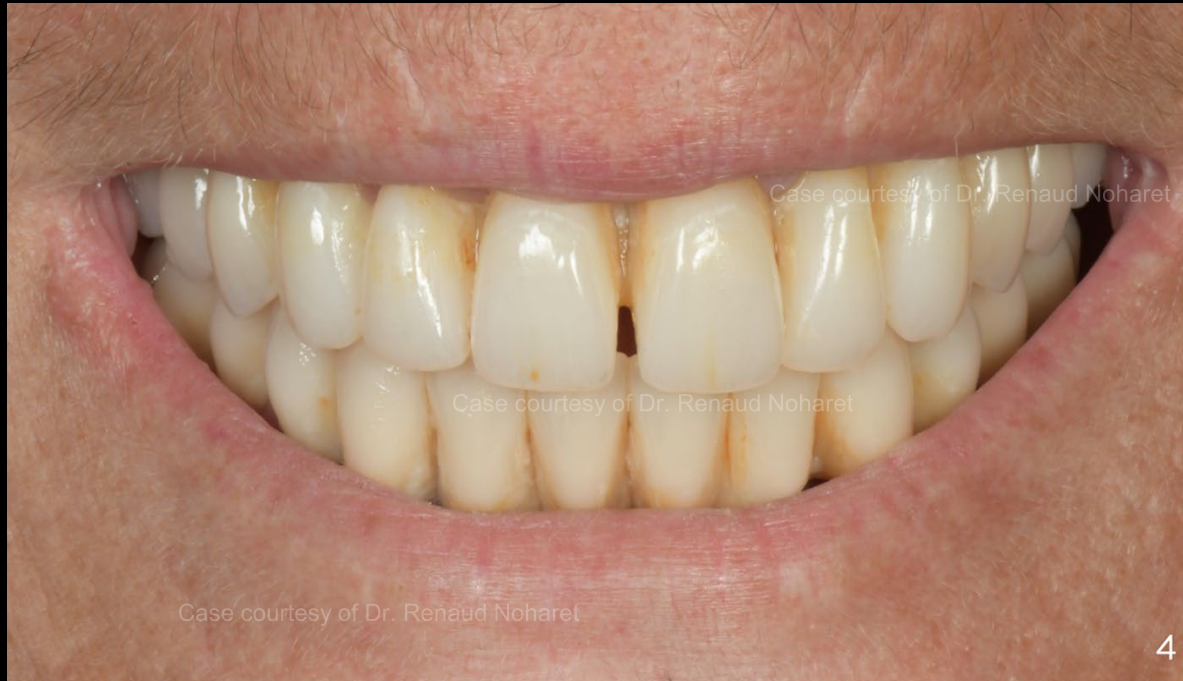Treatment
planning

Surgical
procedure

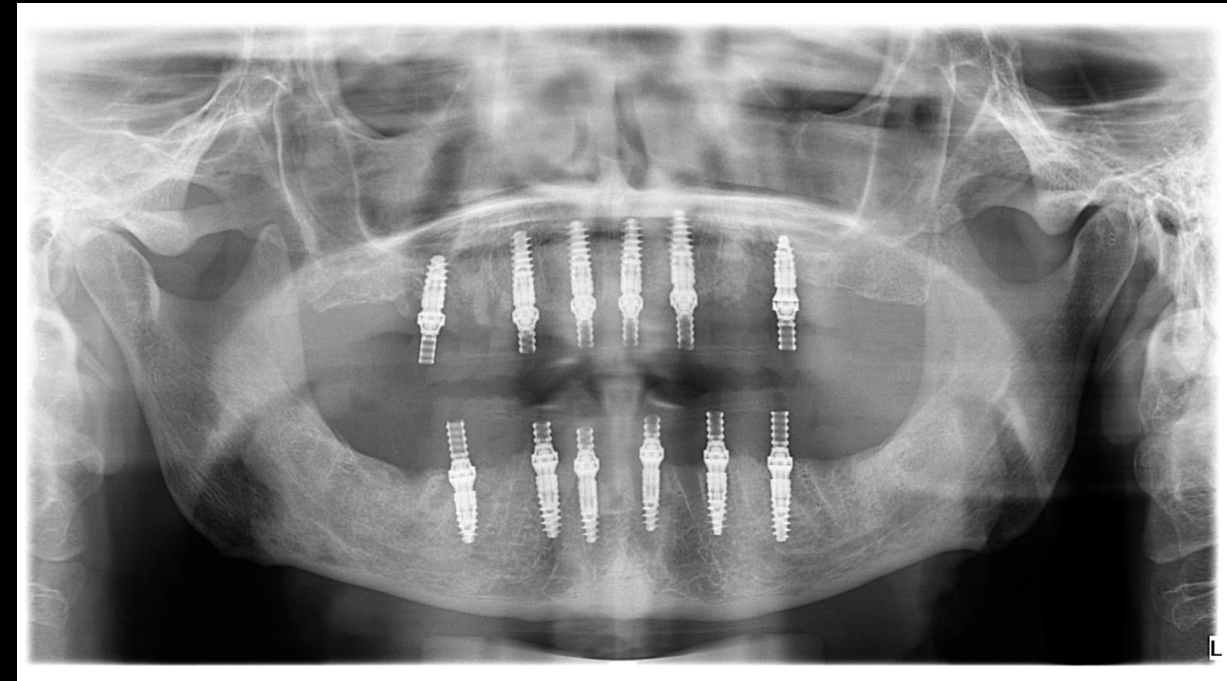
Post-surgical
impression

Immediate
loading

Digital records and
final restoration



Provisional at 4 months follow-up.



X-ray at 4 months follow-up.

Case courtesy of Dr. Renaud Noharet



GMT95579 2503 Nobel Biocare Services AG, 2025. All rights reserved. Distributed by: Nobel Biocare. Nobel Biocare, the Nobel Biocare logotype and all other trademarks are, if nothing else is stated or is evident from the context in a certain case, trademarks of Nobel Biocare. Please refer to nobelbiocare.com/trademarks for more information. Product images are not necessarily to scale. All product images are for illustration purposes only and may not be an exact representation of the product. Please contact the local Nobel Biocare sales office for current product assortment and availability. Disclaimer: For prescription use only. Caution: Federal (United States) law or the law in your jurisdiction may restrict this device to sale by or on the order of a licensed clinician, medical professional or physician. See Instructions For Use for full prescribing information, including indications, contraindications, warnings and precautions. OCS-B (Nibec Co., Ltd.) is distributed as creos™ xenogain since September 2016. Legal Manufacturer: Nibec Co., Ltd. Iwol electricity-electronic Agro-industrial Complex, 116 Bamdi-gil, Iwol-myeon, Jincheon-gun, Chungcheongbuk-do, 27816 Korea. Nobel Biocare does not take any liability for any injury or damage to any person or property arising from the use of this clinical case. This clinical case is not intended to recommend any measures, techniques, procedures or products, or give advice, and is not a substitute for medical training or your own clinical judgement as a healthcare professional. Viewers should never disregard professional medical advice or delay seeking medical treatment because of something they have seen in this clinical case. Full procedure is not shown. Certain sequences have been cut.