


Guided bone regeneration in the anterior region

using creos™ xenogain, creos™ xenoprotect
creos™ syntoprotect Ti-reinforced,
creos™ syntostitch, creos™ screw fixation,
creos™ pin fixation titanium pins,
N1™ implants

Univ.-Prof. DDr. Werner Zechner, Vienna, Austria





Prof. Werner Zechner

Patient

20-year-old male patient, nonsmoker

Clinical situation

Status post bike accident with central incisors tooth avulsion and replantation at the age of 16 (position 11 and 21), followed by failing root canal treatments and tooth loss.

Surgical solution

Guided bone regeneration (6 months post-extraction) using a 50/50 mix of autogenous and xenogenic bone graft material and a titanium-reinforced dPFTE membrane. After a six-month healing period, two Nobel Biocare N1™ implants were placed.

Products used

creos™ xenogain, creos™ syntoprotect Ti-reinforced, creos™ xenoprotect, creos™ screw fixation, creos™ pin fixation titanium pins, creos™ syntostitch, Nobel Biocare N1™ implants.

Surgery date

October 2024

Planned treatment time

9 months

Tooth position

11, 21

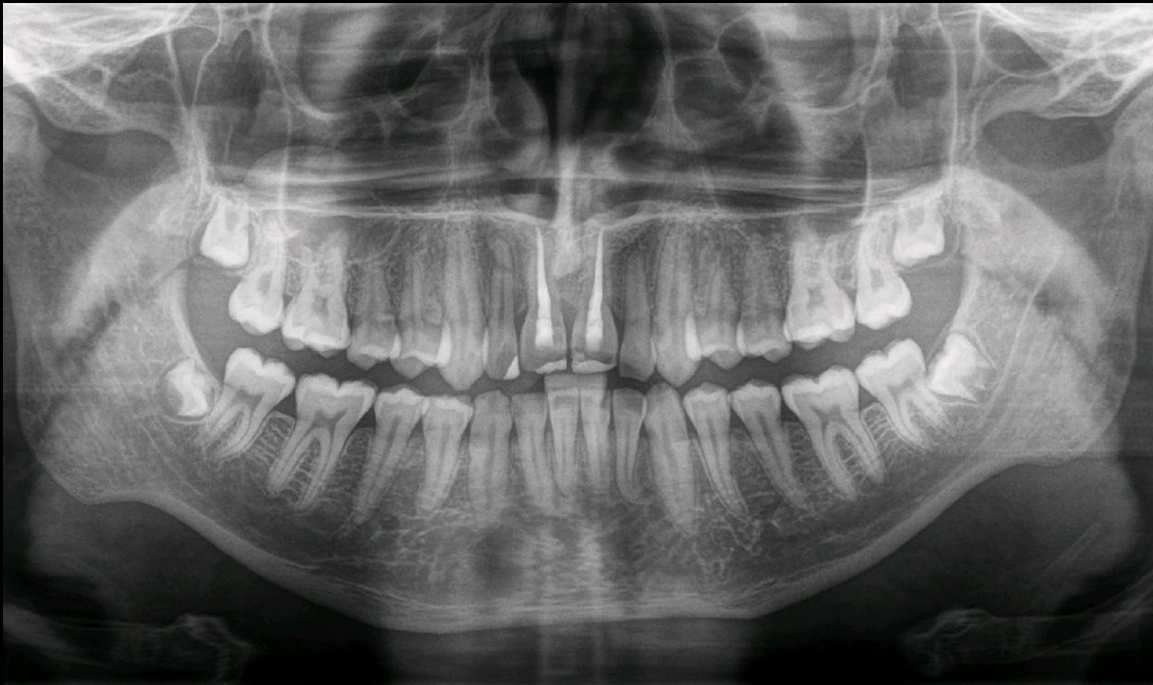**Initial clinical
situation**

**Guided Bone
Regeneration**

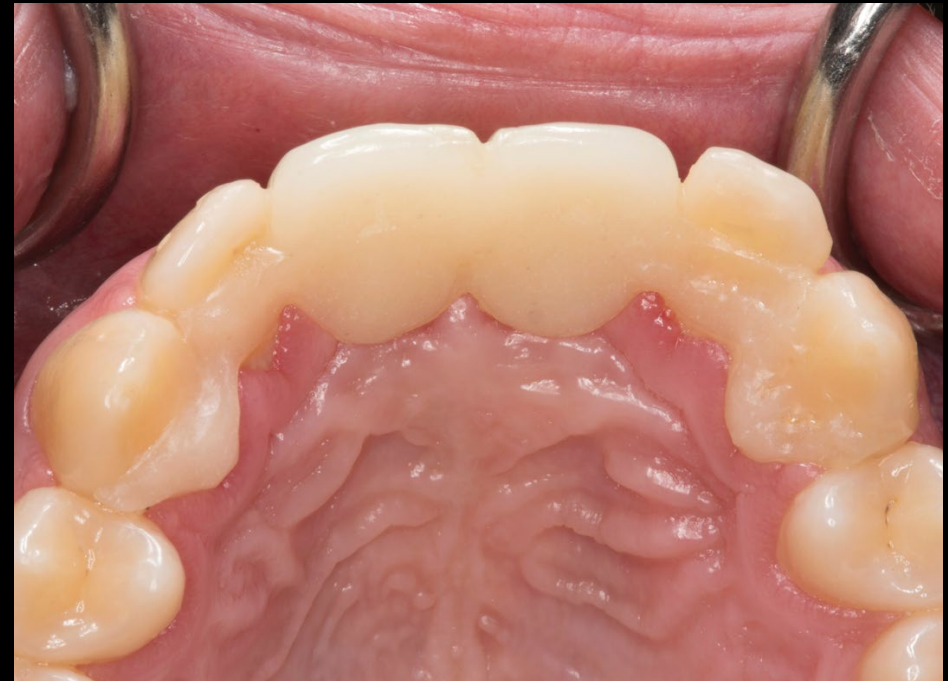Implant placement

Clinical outcome

Radiographic and clinical view



CBCT scan of initial clinical situation. Failing root canals in the anterior zone.



Initial situation before extraction.

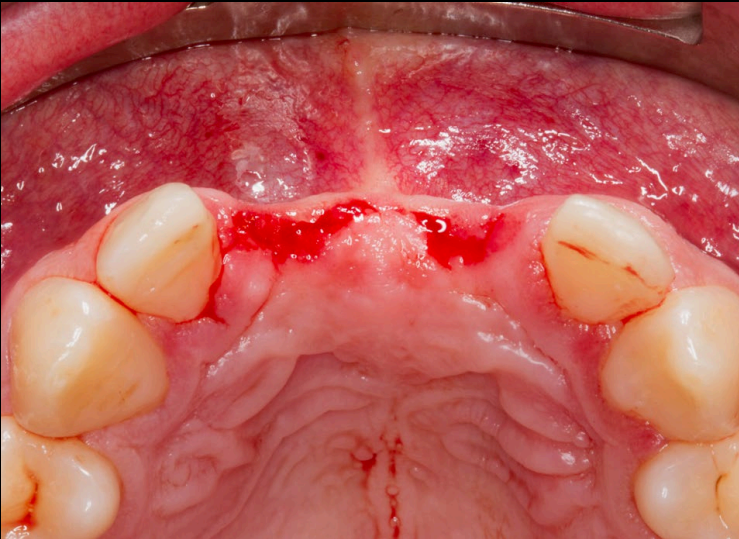
**Initial clinical
situation**

**Guided Bone
Regeneration**

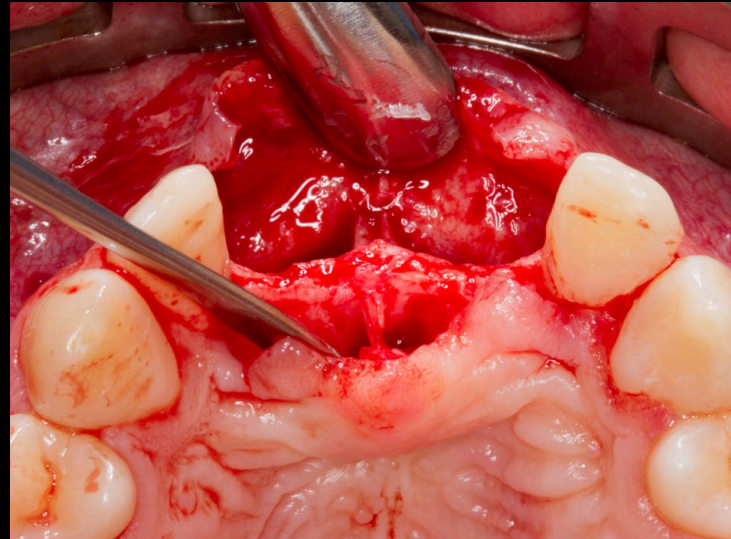
Implant placement

Clinical outcome

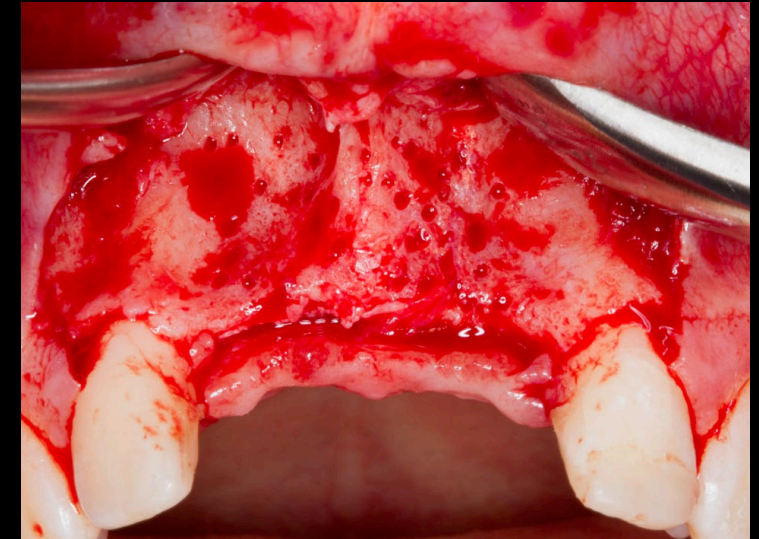
Incision and flap elevation



Crestal incision after 2 months of post-extraction healing.



Elevation of a full-thickness flap.



After elevation of a full-thickness flap and bony perforations for improved graft vascularization.

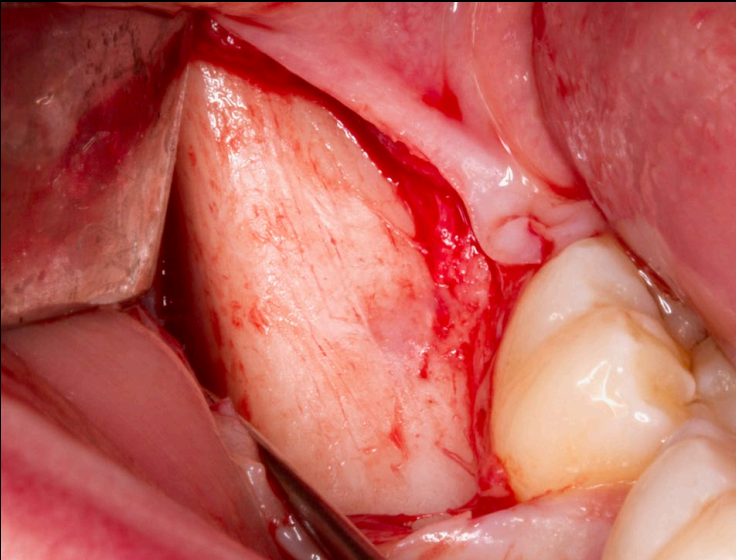
**Initial clinical
situation**

**Guided Bone
Regeneration**

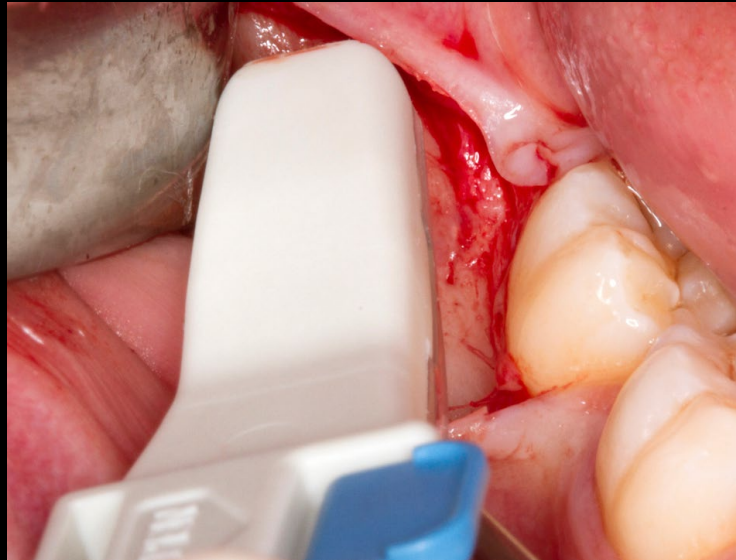Implant placement

Clinical outcome

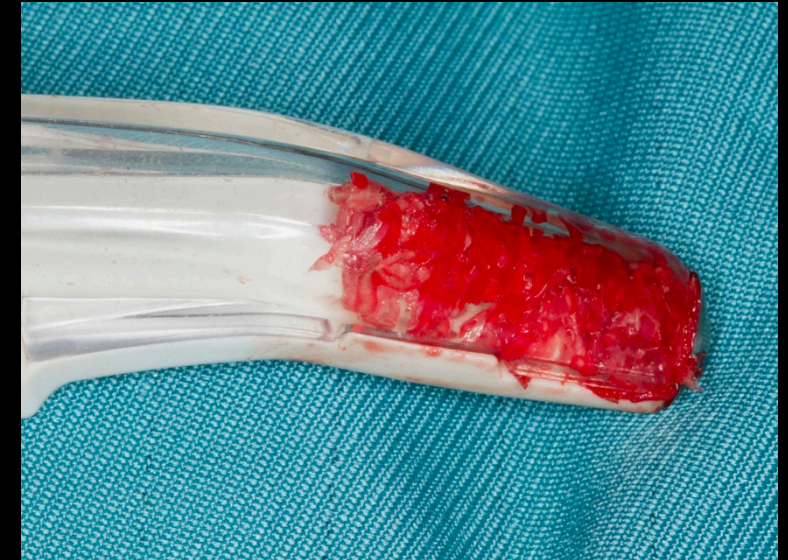Bone harvesting in the retromolar area of the mandible



Preparation of harvesting site.



**Harvesting autogenous bone from the oblique line /
retromolar area using a bone scraper.**



Harvested bone.

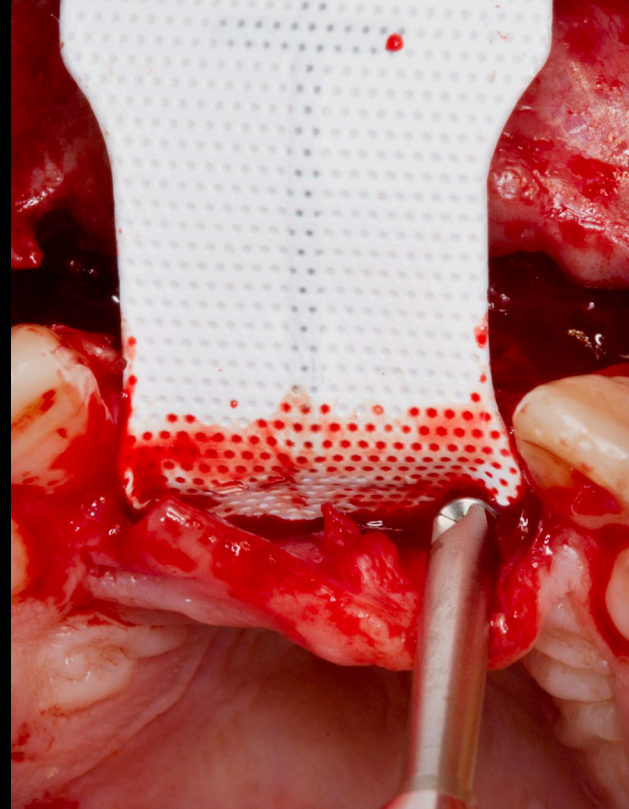
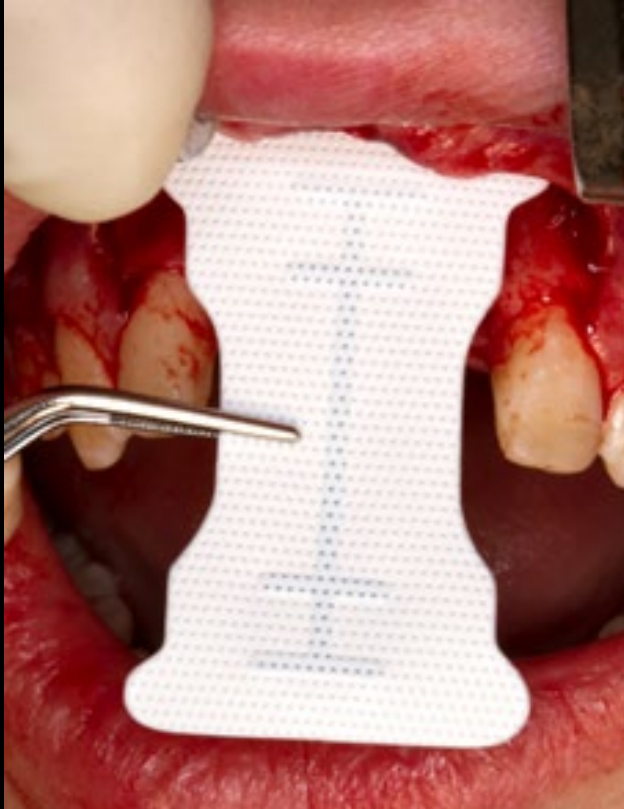
**Initial clinical
situation**

**Guided Bone
Regeneration**

Implant placement

Clinical outcome

Adaption and fixation of the membrane



Palatal fixation of a creos™ syntoprotect Ti-reinforced PTFE membrane using creos™ fixation screws on the palatal aspect of the graft site.

**Initial clinical
situation**

**Guided Bone
Regeneration**

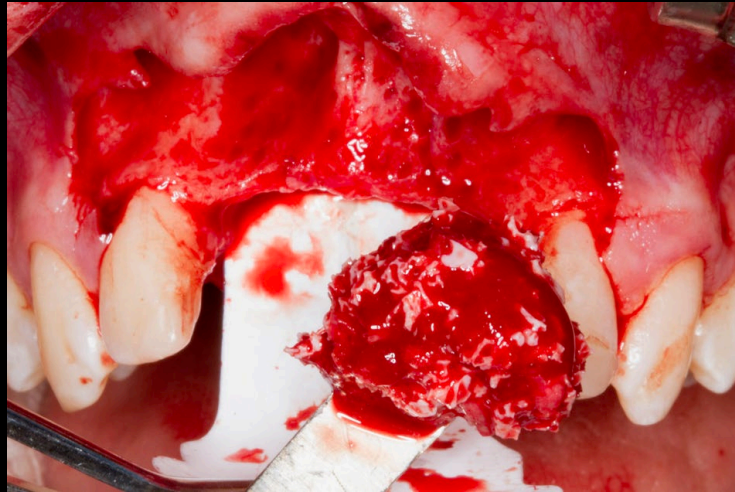Implant placement

Clinical outcome

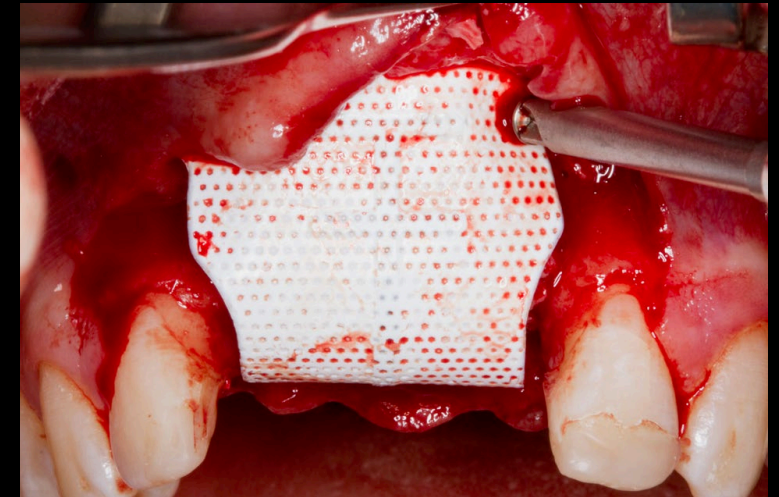
Application of the mixture of autogenous bone chips, autogenous blood and bovine graft material followed by the final fixation of the membrane



Mixing 50/50 autologous bone and creos xenogain bone graft material.



Application of the mixed grafting materials.



Fixation of the creos™ syntoprotect membrane on the buccal side.

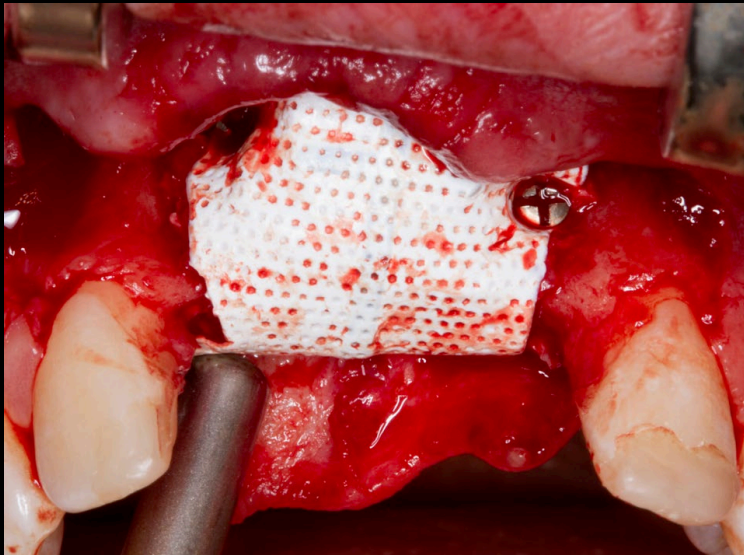
**Initial clinical
situation**

**Guided Bone
Regeneration**

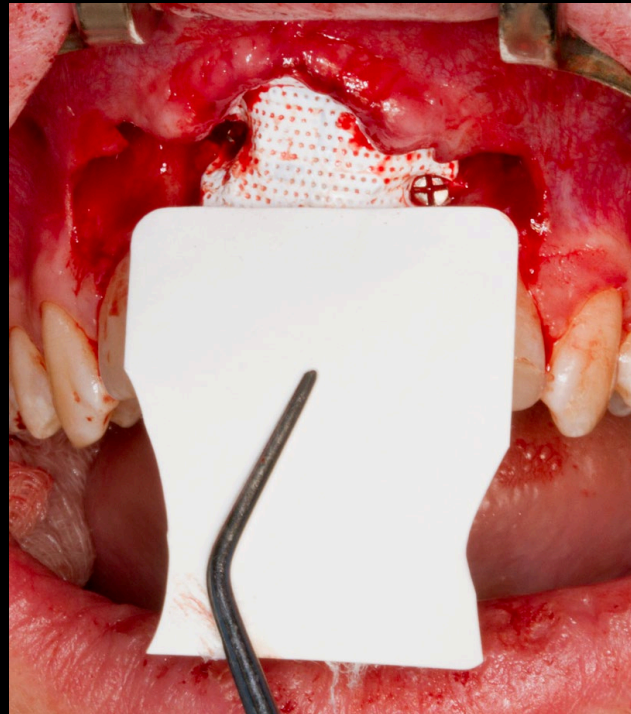
Implant placement

Clinical outcome

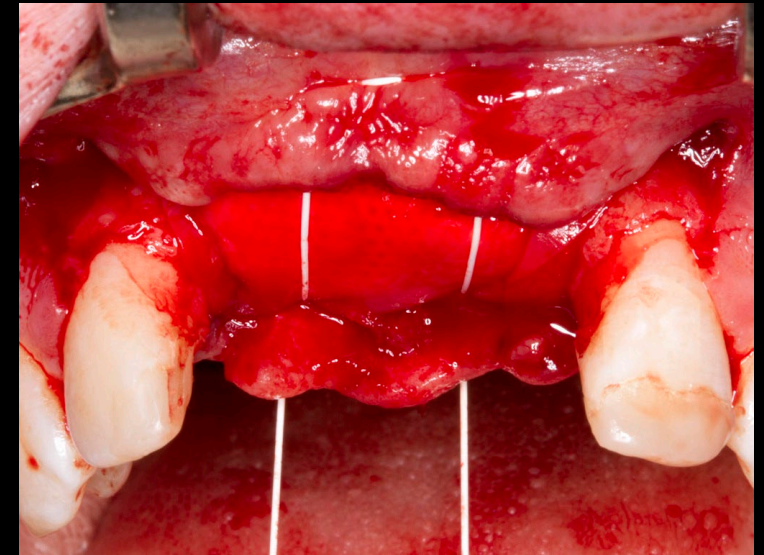
Fixation and placement of additional collagen membrane



Buccal fixation using creos™ fixation screws.



Placement of a creos™ xenoprotect membrane as an additional biocompatible barrier.



Fixation of the collagen membrane using creos™ syntostitch PTFE backpack sutures.

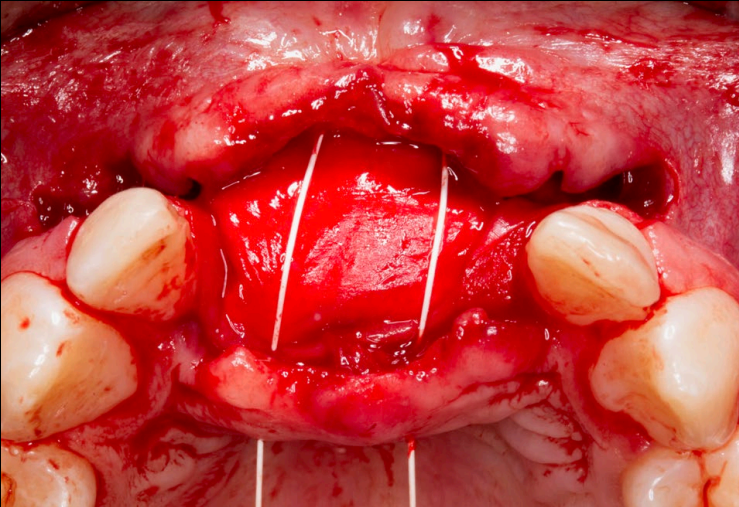
**Initial clinical
situation**

**Guided Bone
Regeneration**

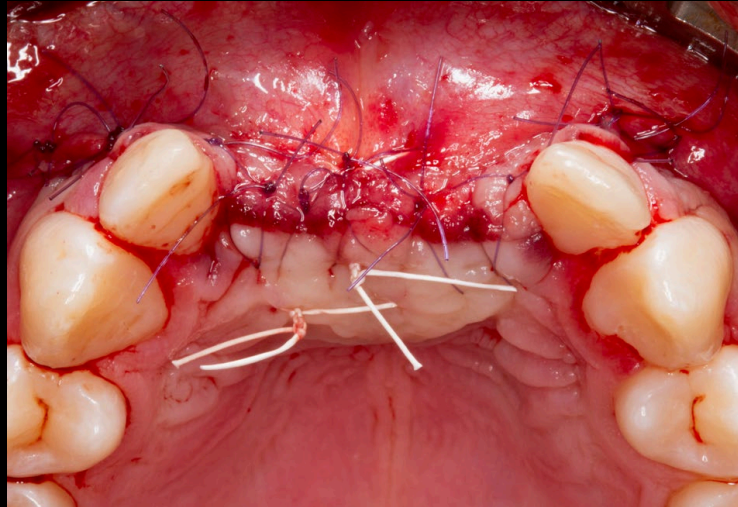
Implant placement

Clinical outcome

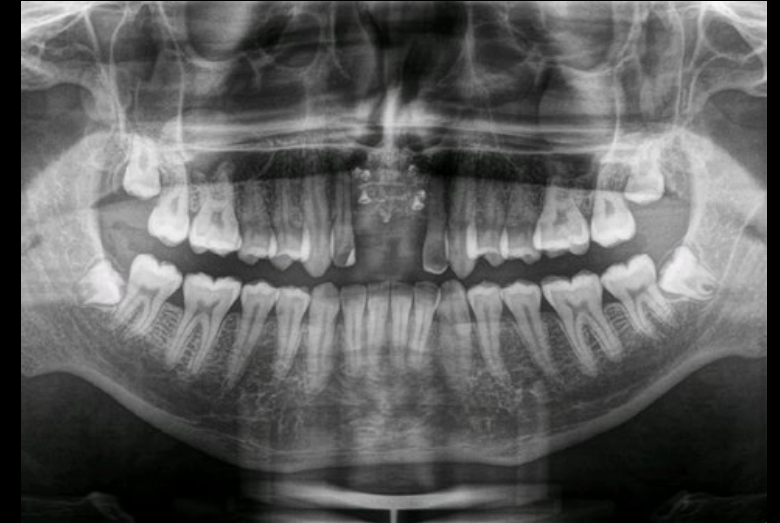Closure and radiological check



Closure using horizontal backpack mattress suture using creos™ syntostitch PTFE sutures.



Simple interrupted sutures using a resorbable monofilament suture.



Radiological check after the augmentation surgery.

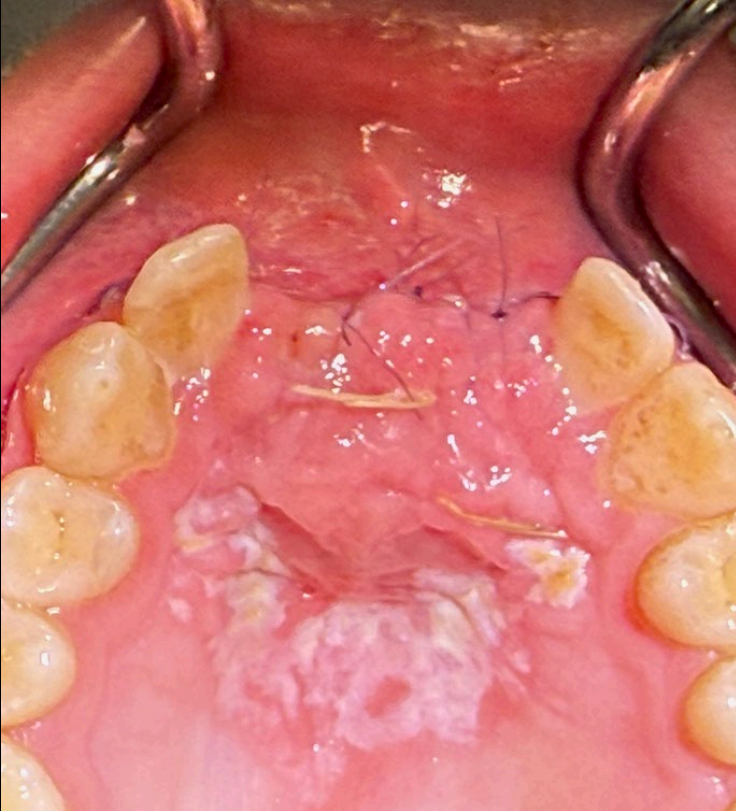**Initial clinical
situation**

**Guided Bone
Regeneration**

Implant placement

Clinical outcome

Clinical follow up after 1 week



**Clinical view at 1-week follow-up after guided bone
regeneration surgery.**

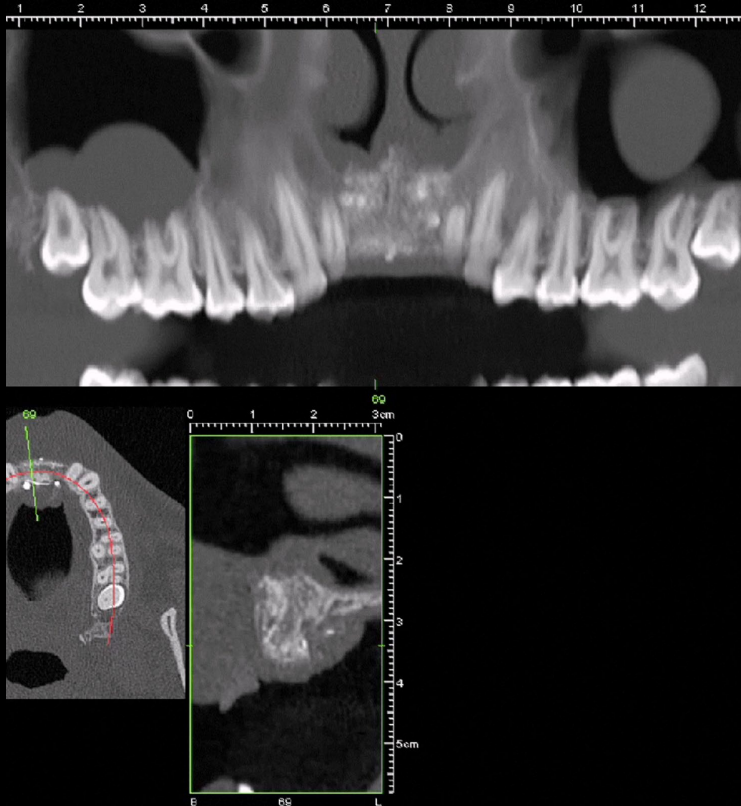
**Initial clinical
situation**

**Guided Bone
Regeneration**

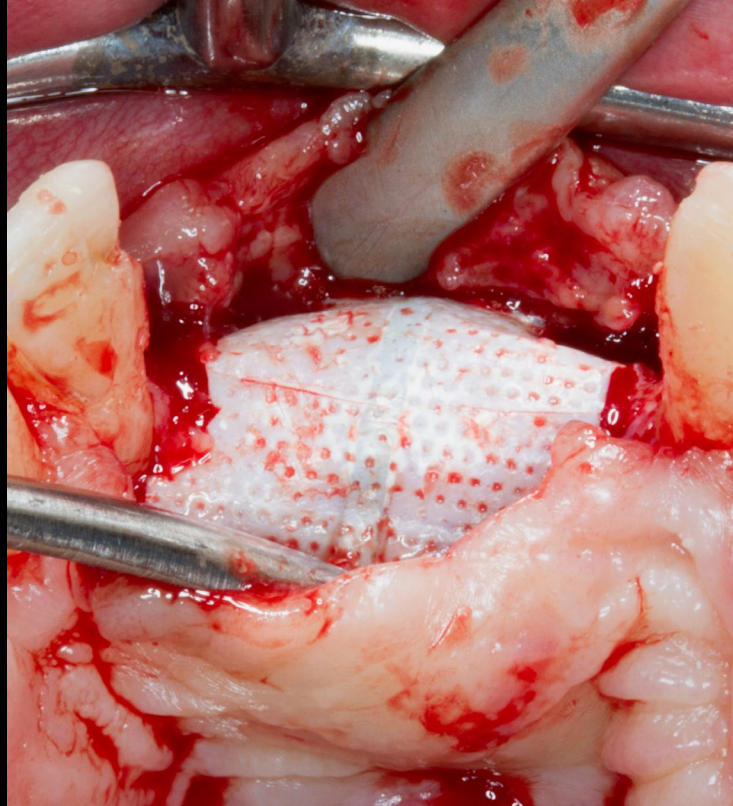
Implant placement

Clinical outcome

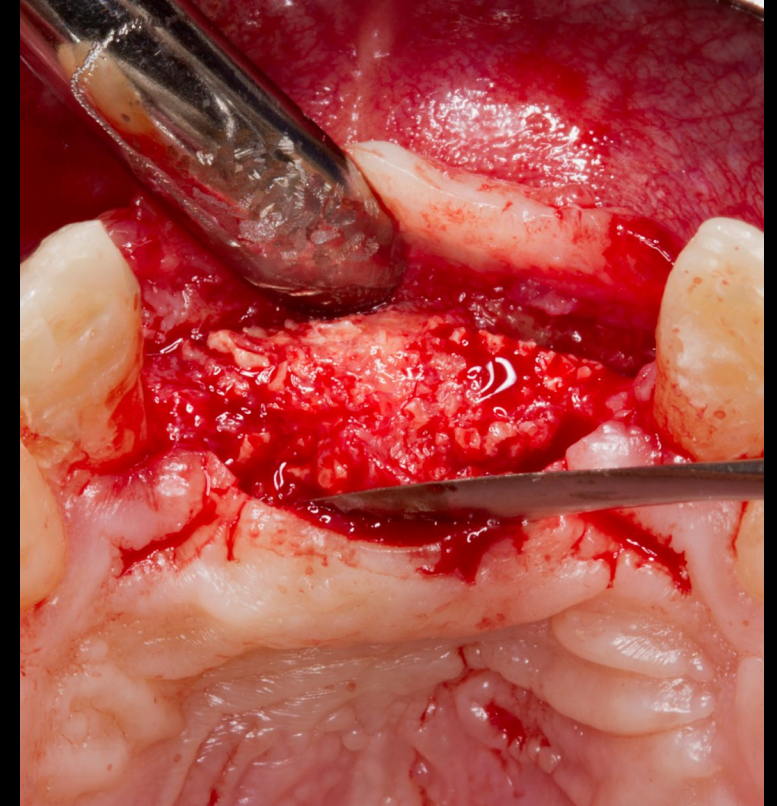
Implant placement after 6-months healing following guided bone regeneration



CBCT scan showing the augmented alveolar ridge after GBR.



creos™ syntoprotect membrane during uncovering of the augmented site at 6 months.



Augmented site showing healthy regenerated bone after healing.

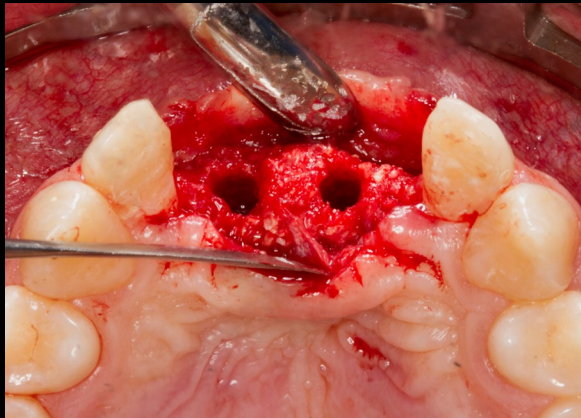
**Initial clinical
situation**

**Guided Bone
Regeneration**

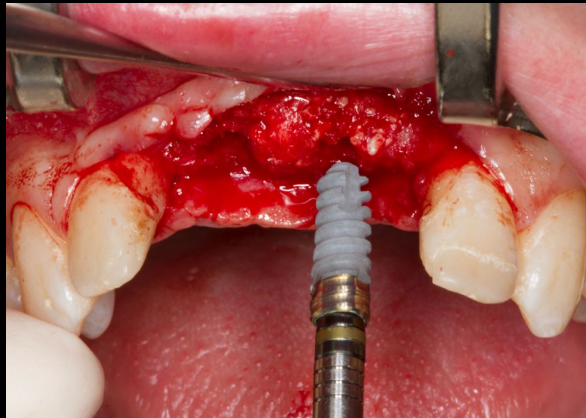
Implant placement

Clinical outcome

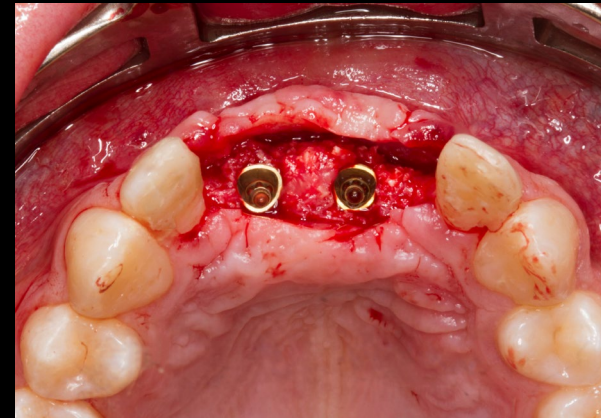
Implant placement after 6-months healing following guided bone regeneration



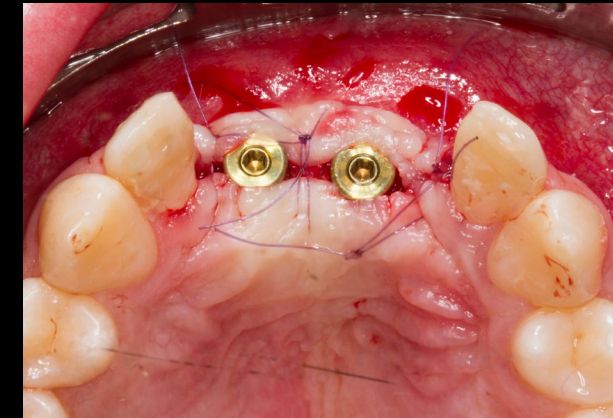
Drilled osteotomy site in augmented bone.



Insertion of a Nobel Biocare N1™ implant.



Clinical view after placement of two Nobel Biocare N1™ implants in the augmented site.



Connection of a healing abutment and suturing.

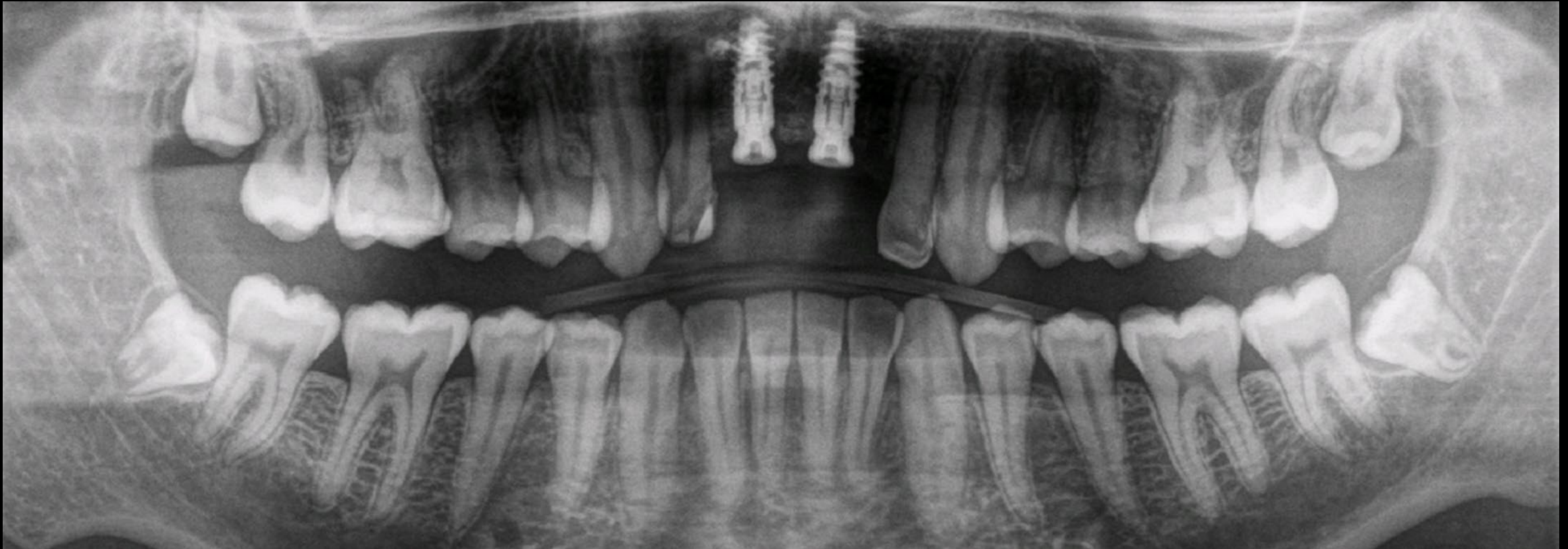
**Initial clinical
situation**

**Guided Bone
Regeneration**

Implant placement

Clinical outcome

CBCT scan after implant placement surgery



CBCT scan after implant placement surgery, 6 months post-guided bone regeneration.

**Initial clinical
situation**

**Guided Bone
Regeneration**

Implant placement

Clinical outcome

**This is a referral case; the patient will return to the referring dentist for the prosthetic phase.
Therefore, no images with the definitive crown are available.**

Case courtesy of Univ.-Prof. DDr. Werner Zechner



GMT xxxx GB 1906 © Nobel Biocare Services AG, 2019. All rights reserved. Nobel Biocare, the Nobel Biocare logotype and all other trademarks are, if nothing else is stated or is evident from the context in a certain case, trademarks of Nobel Biocare. Please refer to nobelbiocare.com/trademarks for more information. Product images are not necessarily to scale. Disclaimer: Some products may not be regulatory cleared/released for sale in all markets. Please contact the local Nobel Biocare sales office for current product assortment and availability. For prescription use only. Caution: Federal (United States) law restricts this device to sale by or on the order of a licensed clinician, medical professional or physician. See Instructions For Use for full prescribing information, including indications, contraindications, warnings and precautions. Nobel Biocare does not take any liability for any injury or damage to any person or property arising from the use of this clinical case. This clinical case is not intended to recommend any measures, techniques, procedures or products, or give advice, and is not a substitute for medical training or your own clinical judgement as a healthcare professional. Viewers should never disregard professional medical advice or delay seeking medical treatment because of something they have seen in this clinical case. Full procedure is not shown. Certain sequences have been cut.