

Horizontal and vertical ridge augmentation of a knife-edge ridge

Bastian Wessing
Germany



Bastian Wessing

Patient

54, male

Clinical situation

Missing teeth 46, 47. Late implant placement, bone quality D1. Poor bone quantity with 2-3 mm thickness at the crest, 8 mm and 6 mm residual bone on top of the nervus alveolaris inferior in region 46 and 47 respectively.

Surgical solution

creos xenoprotect membrane Horizontal and vertical augmentation by GBR using "tenting screw technique"

Surgery date

GBR: 25.02.2015

Implant placement: 14.08.2015

Free gingival flap: 04.12.2015

Prosthetic restoration: 18.03.2016

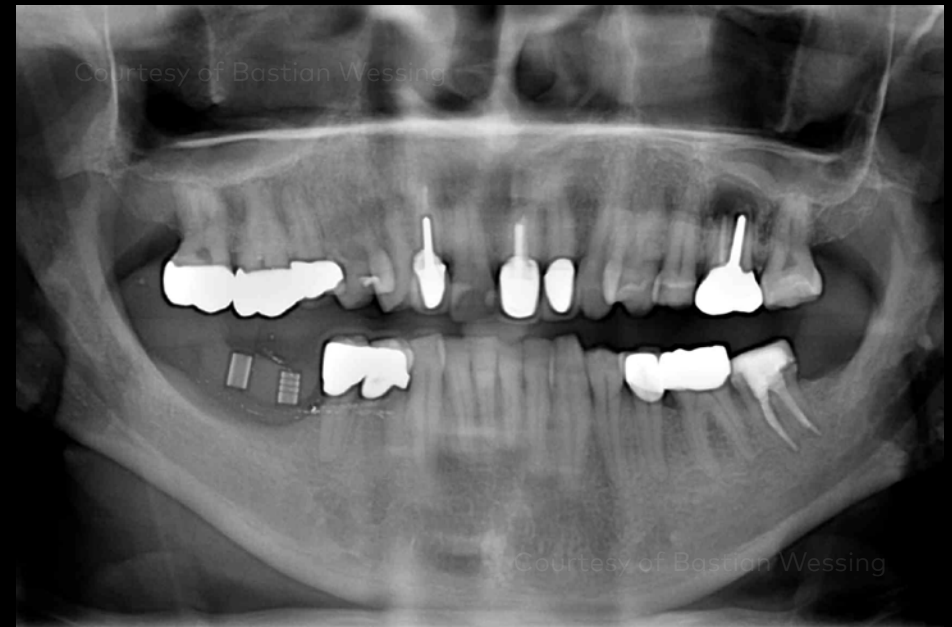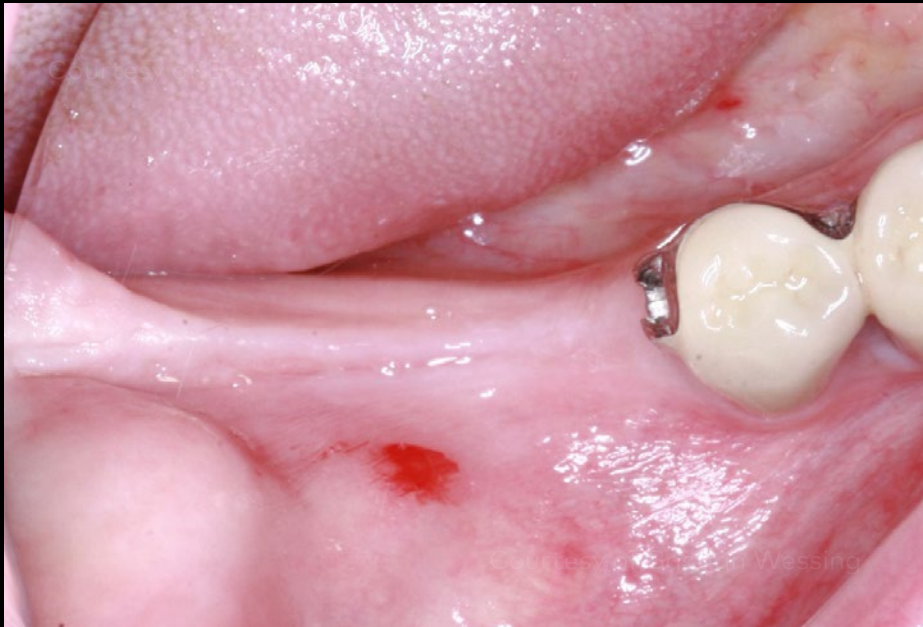"Why do I use the creos xenoprotect membrane?
Because of the improved mechanical properties...
for its effectiveness in many indications."

Initial clinical situation

Surgical procedure

Restorative procedure

Outcome



Alveolar ridge in region 46, 47 with horizontal and vertical defect.

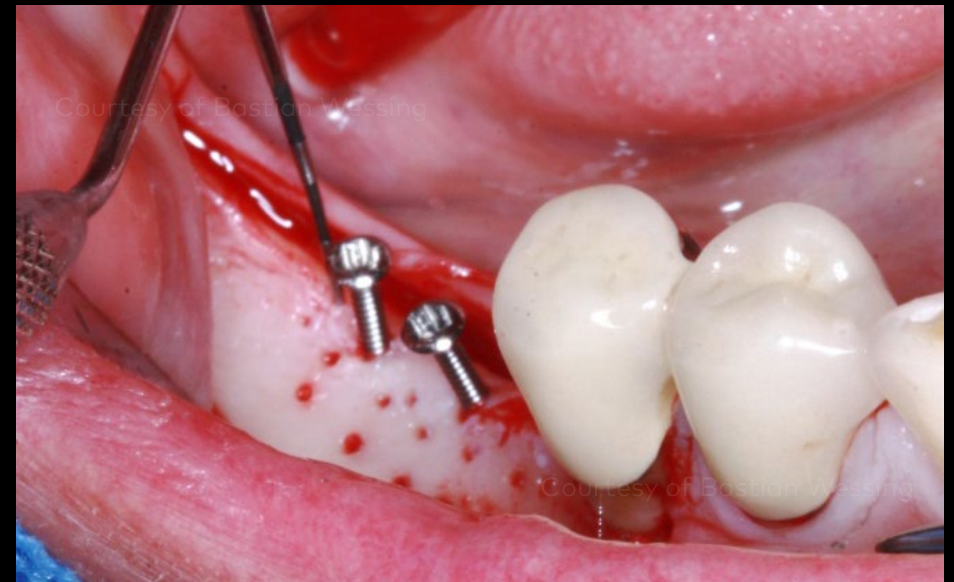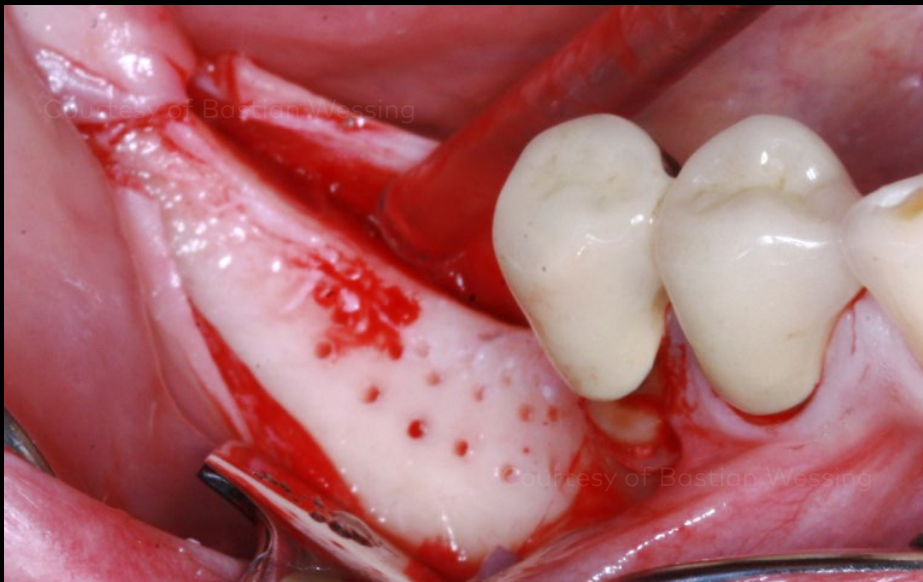
Panoramic radiograph prior to the GBR procedure. The radio-opaque objects on top of the ridge in region 46 and 47 are metallic guide sleeves for determining the implant position.

Initial clinical situation

Surgical procedure

Restorative procedure

Outcome



Bone situation after flap elevation with cortical perforations.

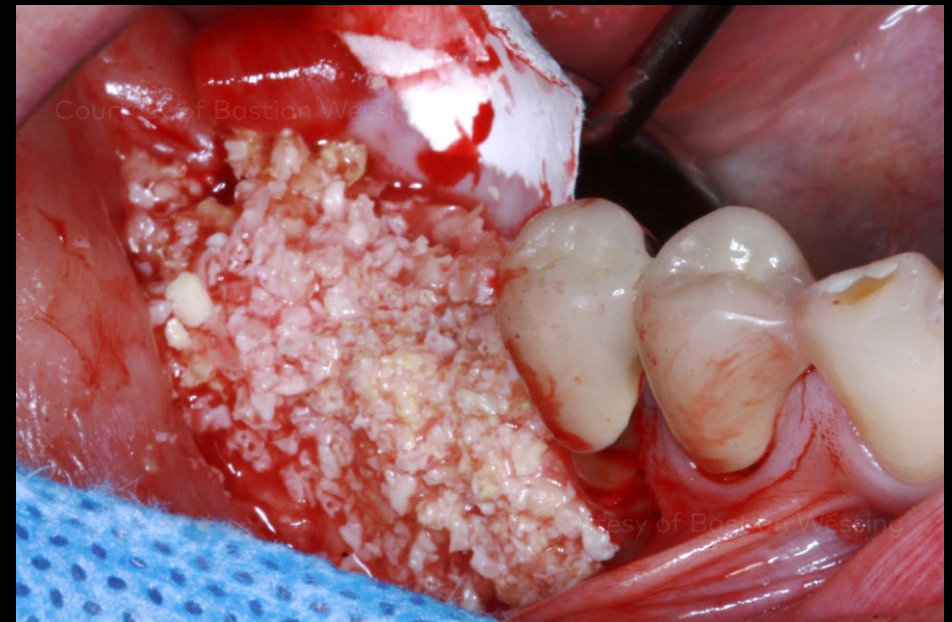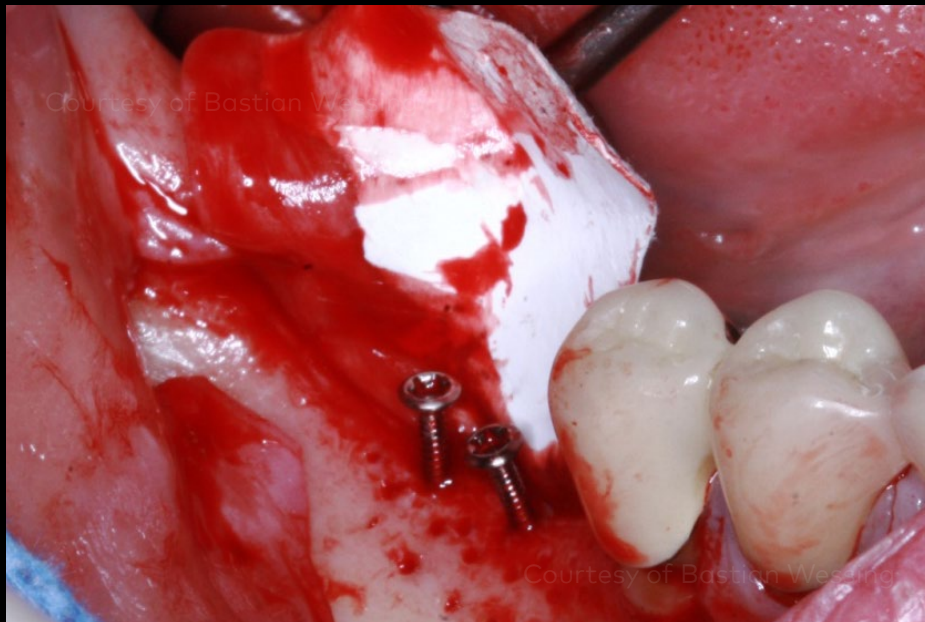
To perform the "tenting screw technique", two 10 mm long osteosynthesis screws were fixed in region 46 and 47 on top of the ridge extending 6 mm above the bone.

Initial clinical situation

Surgical procedure

Restorative procedure

Outcome



creos xenoprotect membrane fixed lingually using two titanium pins.

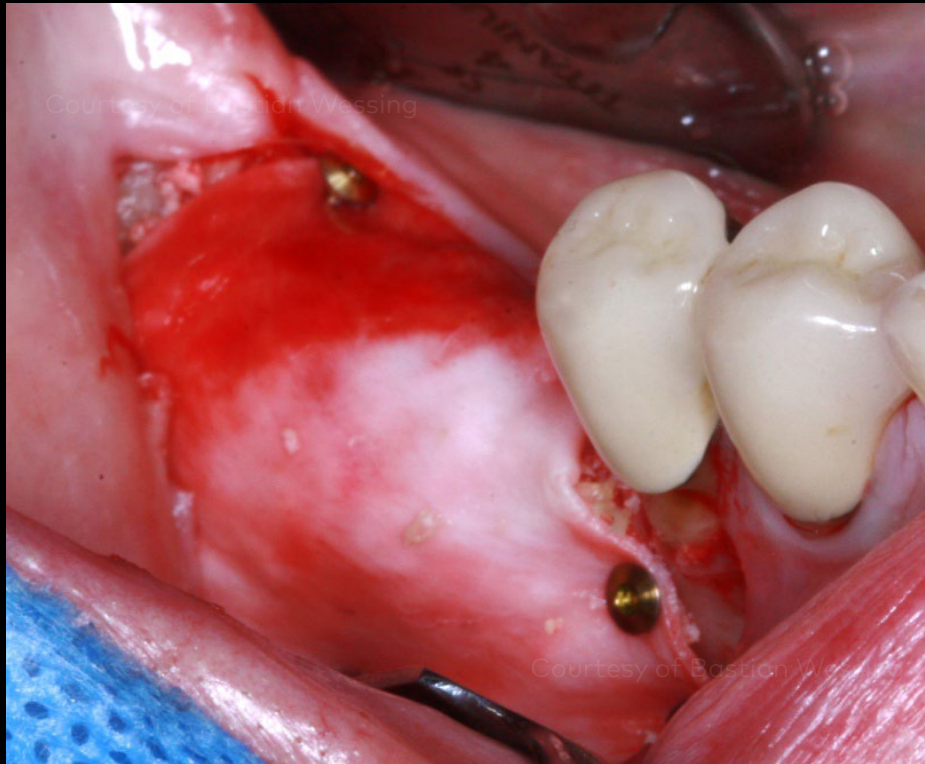Composite bone graft of about 50% autologous bone chips and 50% DBBM.

Initial clinical situation

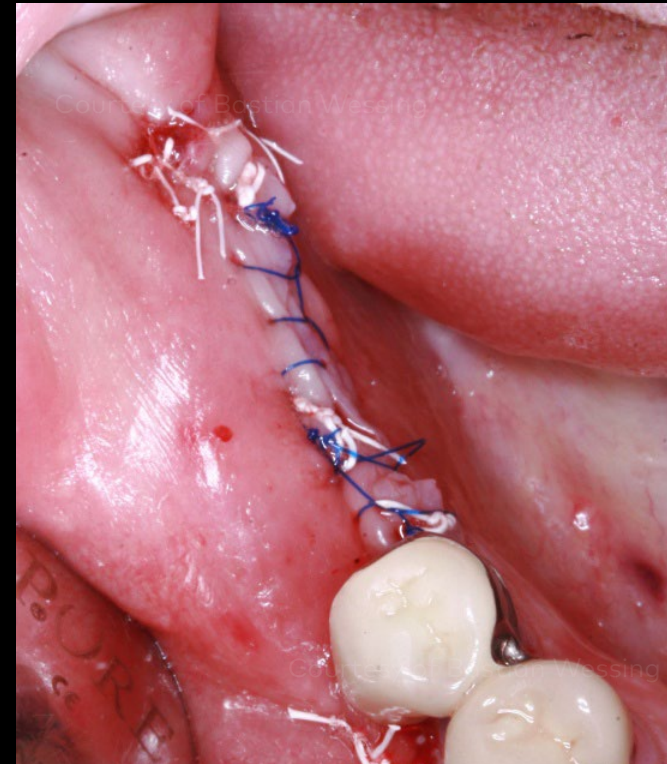
Surgical procedure

Restorative procedure

Outcome



Bone graft successfully immobilized through spanning and fixation of the creos xenoprotect membrane using three additional buccally fixed titanium pins.



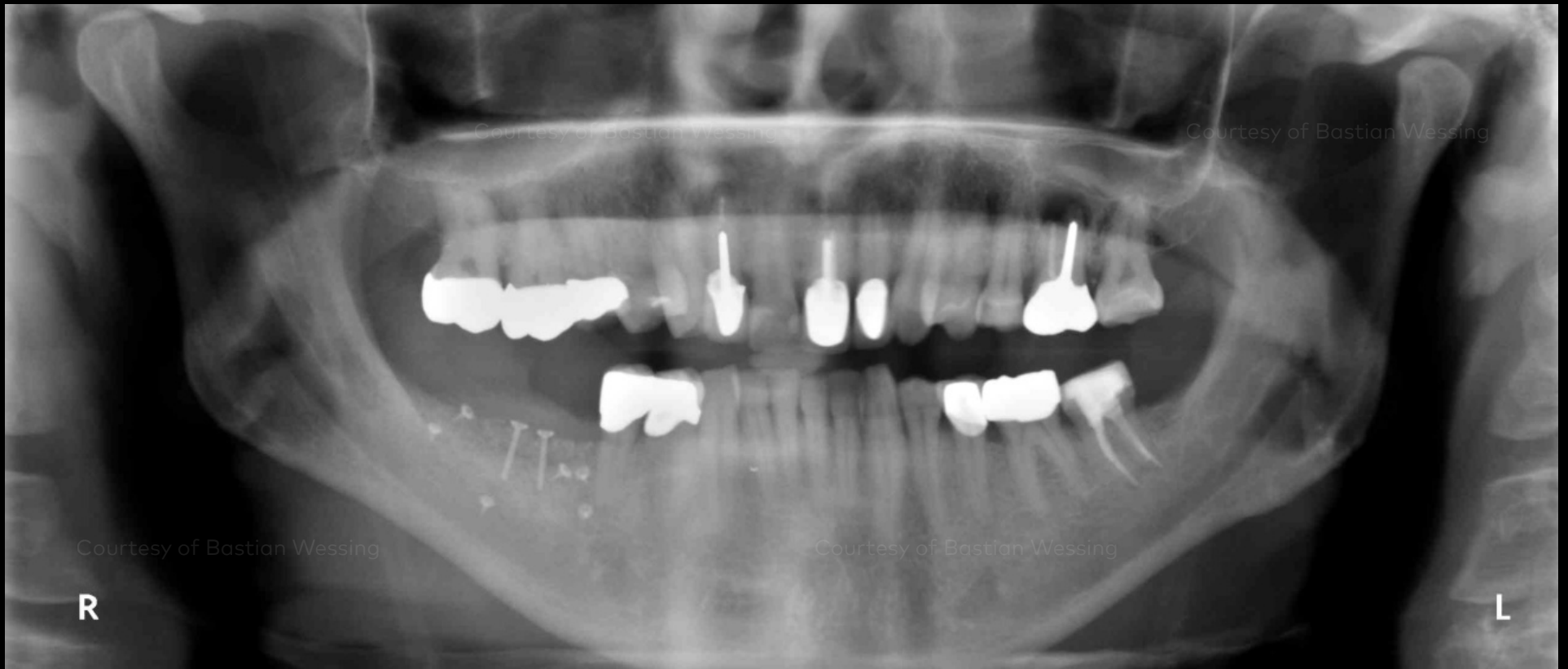Continuous sutures combined with horizontal mattress sutures for uneventful healing.

Initial clinical situation

Surgical procedure

Restorative procedure

Outcome



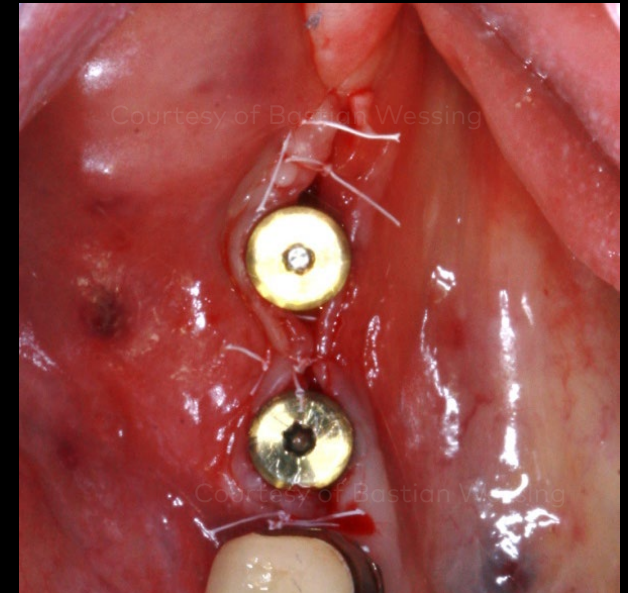
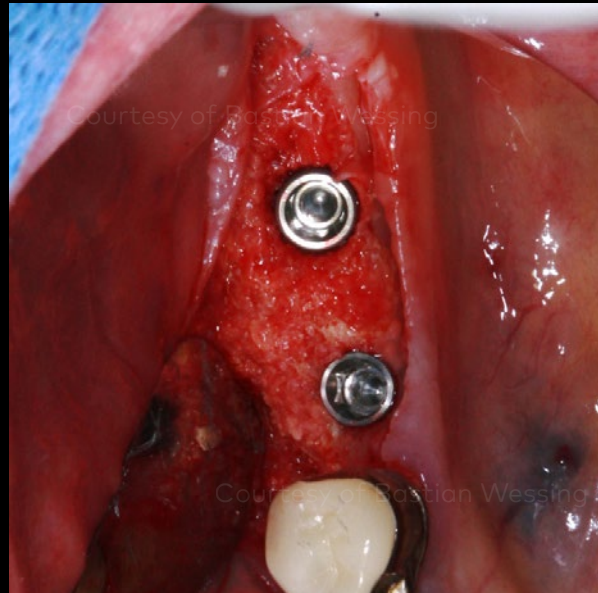
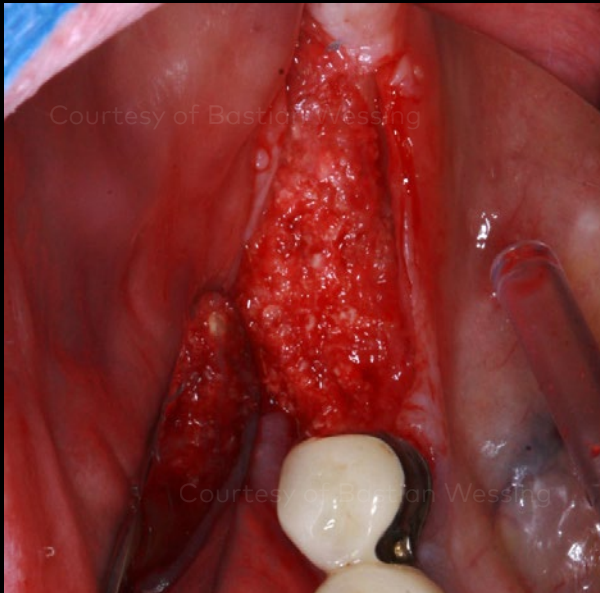
Panoramic radiograph after the GBR procedure.

Initial clinical situation

Surgical procedure

Restorative procedure

Outcome



Alveolar ridge after 6 months of healing, measuring 3 mm vertical and 8 mm horizontal bone gain.

Two NobelActive implants were placed in region 46 (4.3 mm x 11.5 mm) and 47 (5 mm x 10 mm).

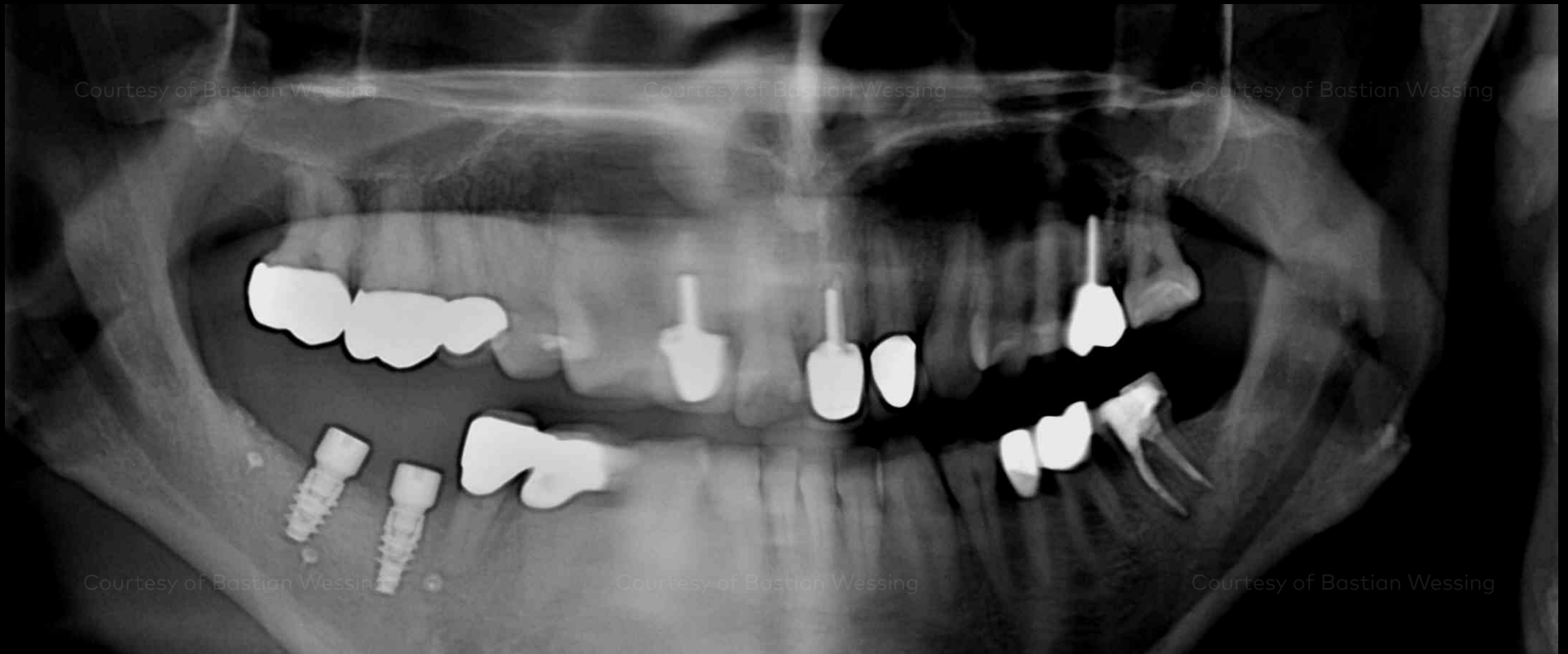One-stage procedure using two healing abutments 5 mm x 5 mm placed for transgingival healing.

Initial clinical situation

Surgical procedure

Restorative procedure

Outcome



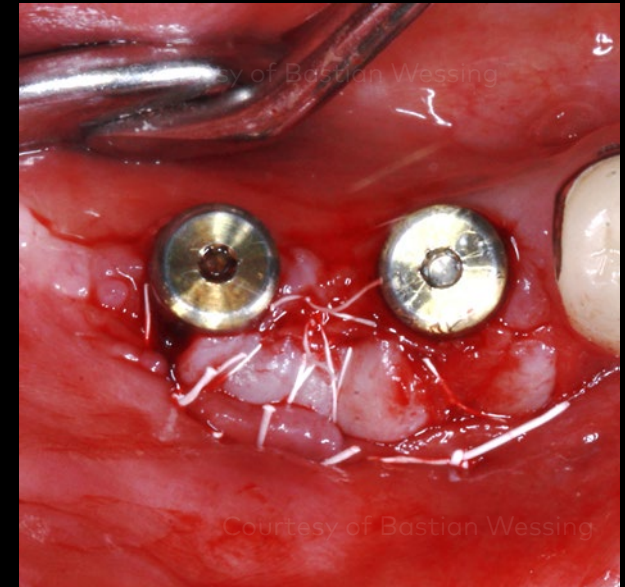
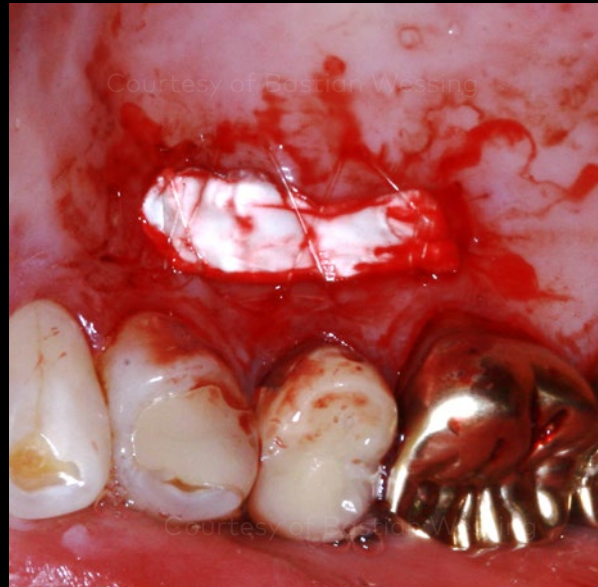
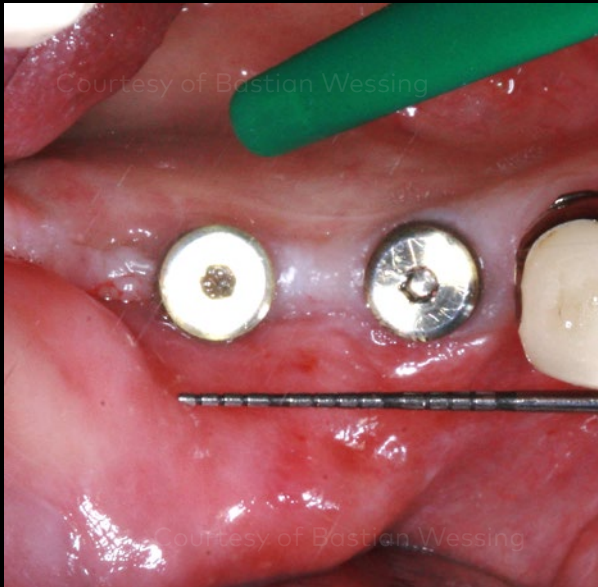
Panoramic radiograph after implant placement.

Initial clinical situation

Surgical procedure

Restorative procedure

Outcome



Situation after four-month healing time. No fixed mucosa on the buccal site requires a free gingival graft.

A free gingival graft from the palate of 15 mm x 5 mm was harvested and the donor site wound was dressed with a collagen matrix.

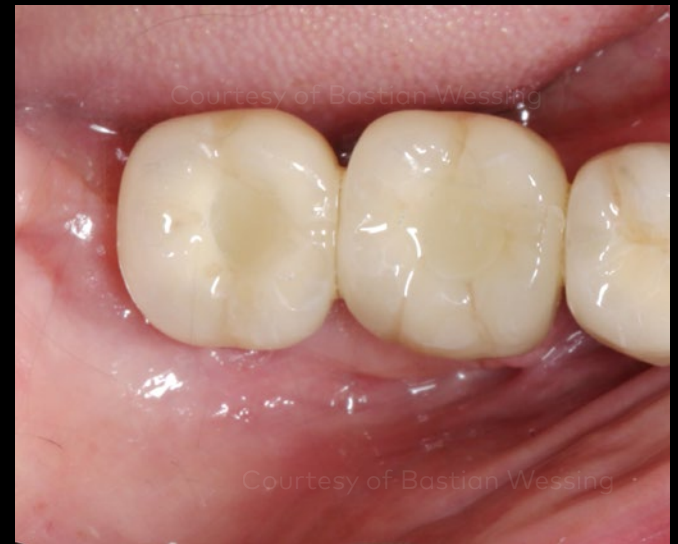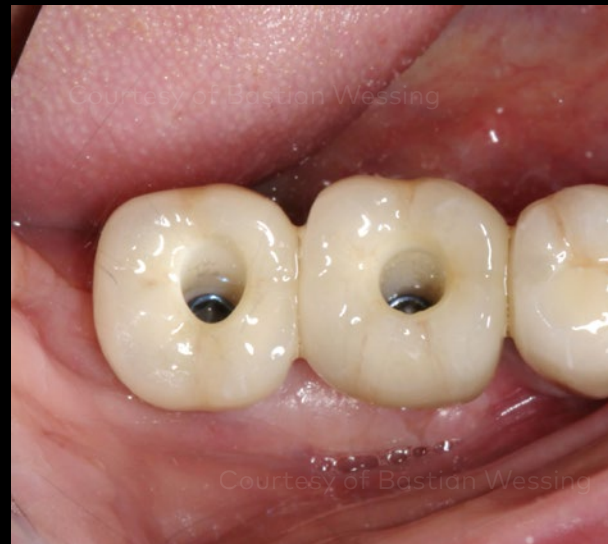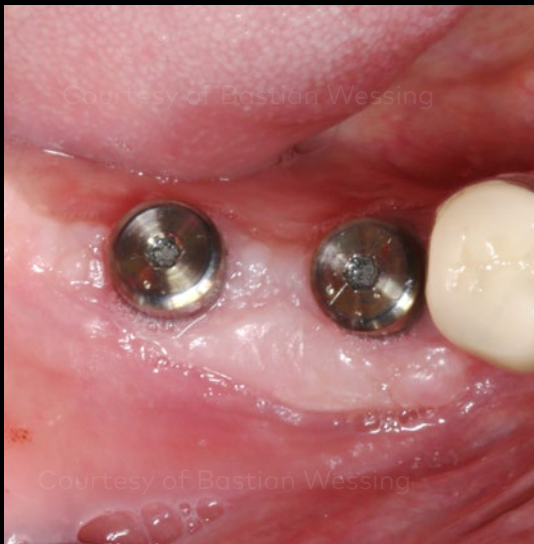A mucosal apical repositioning flap with periosteal sutures was performed and the transplant was fixed to the underground with cross sutures.

Initial clinical situation

Surgical procedure

Restorative procedure

Outcome



Soft tissue healing after 8 weeks.

Nobel Biocare Complete Posterior Solution with two veneered zirconia ASC abutments.

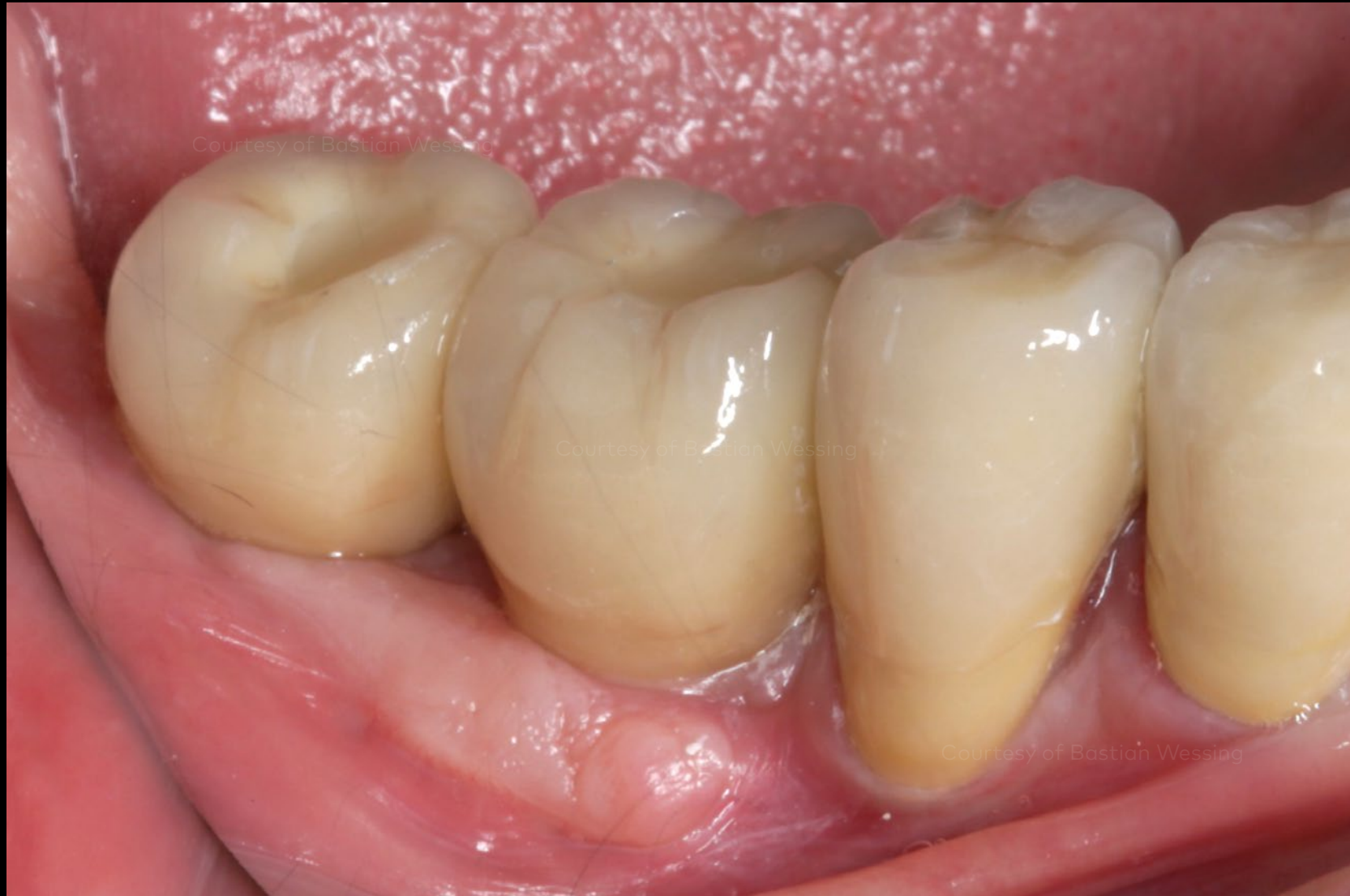Occlusal view of the full-ceramic crowns 46 and 47.

**Initial clinical
situation**

**Surgical
procedure**

**Restorative
procedure**

Outcome



Buccal view of the final full-ceramic crowns.

Case courtesy of Bastian Wessing



GMT 72422 GB 2011 © Nobel Biocare Services AG, 2020. All rights reserved. Nobel Biocare, the Nobel Biocare logotype and all other trademarks are, if nothing else is stated or is evident from the context in a certain case, trademarks of Nobel Biocare. Please refer to [nobelbiocare.com/trademarks](https://www.nobelbiocare.com/trademarks) for more information. Product images are not necessarily to scale. Disclaimer: Some products may not be regulatory cleared/released for sale in all markets. Please contact the local Nobel Biocare sales office for current product assortment and availability. For prescription use only. Caution: Federal (United States) law restricts this device to sale by or on the order of a licensed clinician, medical professional or physician. See Instructions For Use for full prescribing information, including indications, contraindications, warnings and precautions. Nobel Biocare does not take any liability for any injury or damage to any person or property arising from the use of this clinical case. This clinical case is not intended to recommend any measures, techniques, procedures or products, or give advice, and is not a substitute for medical training or your own clinical judgement as a healthcare professional. Viewers should never disregard professional medical advice or delay seeking medical treatment because of something they have seen in this clinical case. Full procedure is not shown. Certain sequences have been cut.