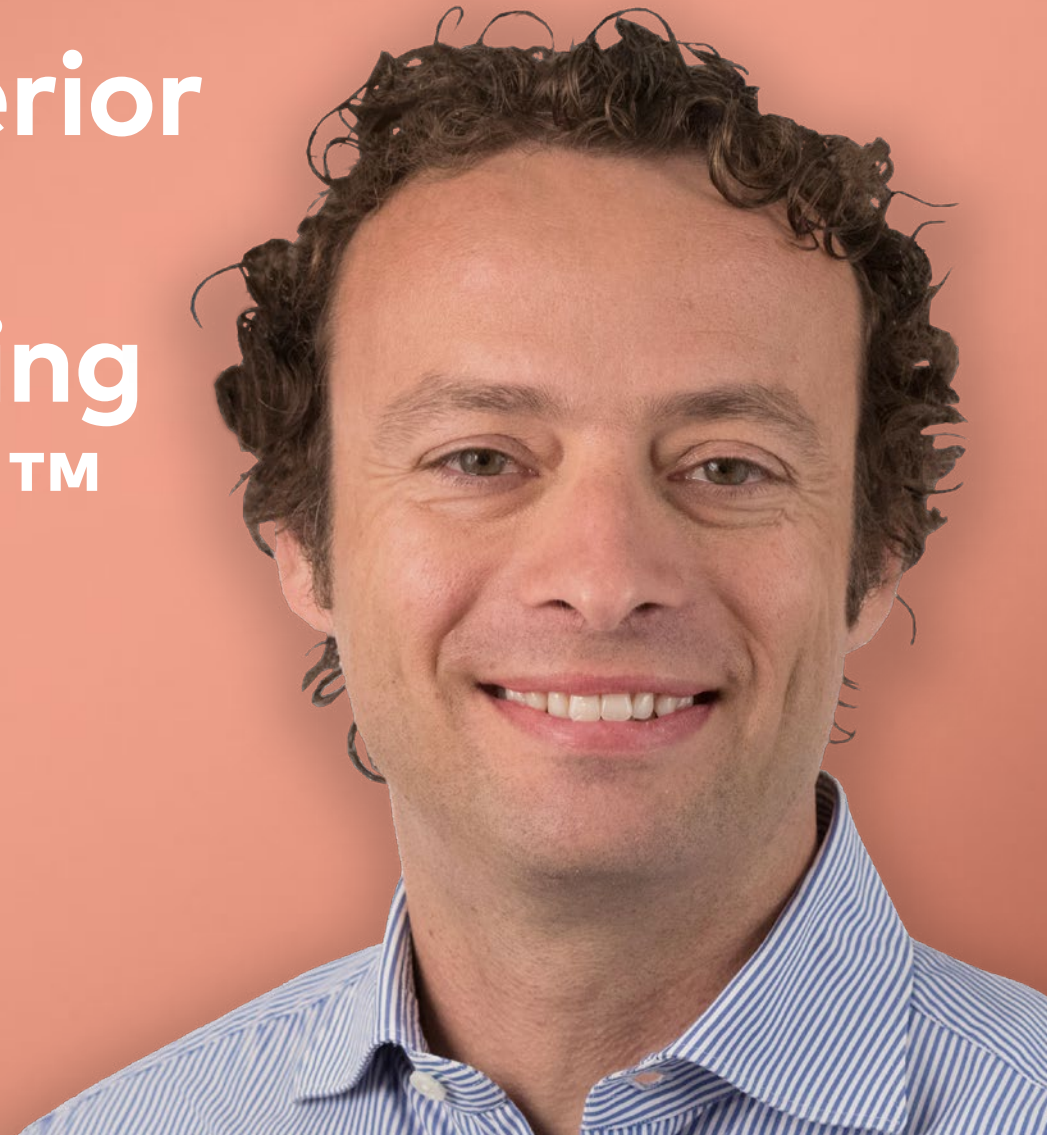

Challenging anterior multidisciplinary rehabilitation using Nobel Biocare N1™ implant system

Giacomo Fabbri
Italy





Dr. Giacomo Fabbri

Patient

Male, 44 years old

Clinical situation

Good systemic and oral health condition, light smoker with history of periodontal disease.

He requires a restorative esthetic treatment of the upper anterior teeth.

All the natural teeth in the posterior areas are healthy and they don't need any therapy. They provide a good occlusal support and function.

Surgical solution

Extraction of 12 and 21 with immediate placement of the N1 Implant, immediate loading and connective tissue graft. Orthodontic therapy finalized to correct the position of tooth 11 and extrude tooth 21.

Restorative solution

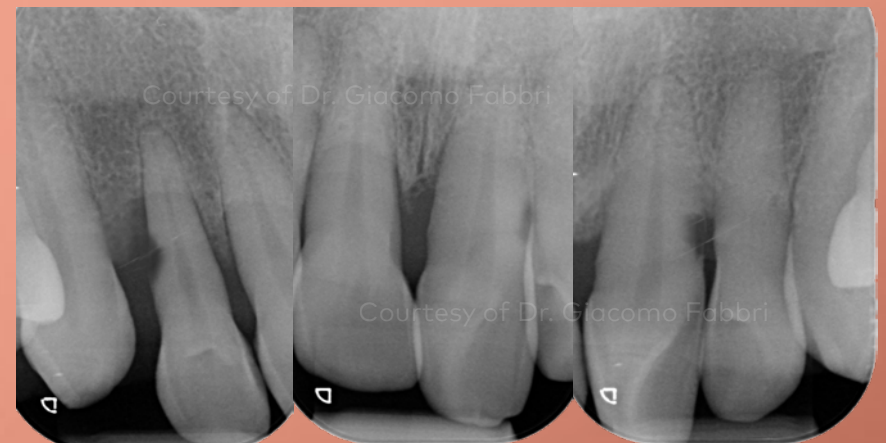Final restoration with all-ceramic restorations on teeth 11 and 12 and 2 screw-retained crowns on implants placed in regions 12 and 21.

Surgery date

20/03/2021

Total treatment time

14 months



Initial clinical situation

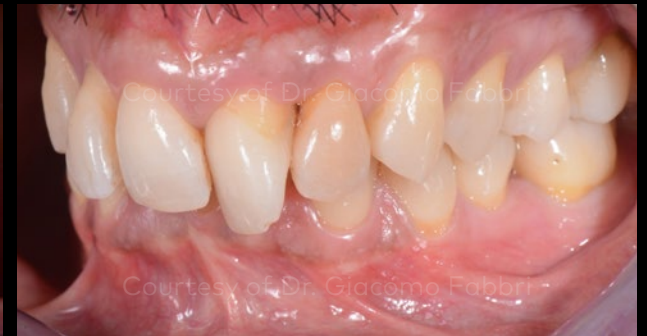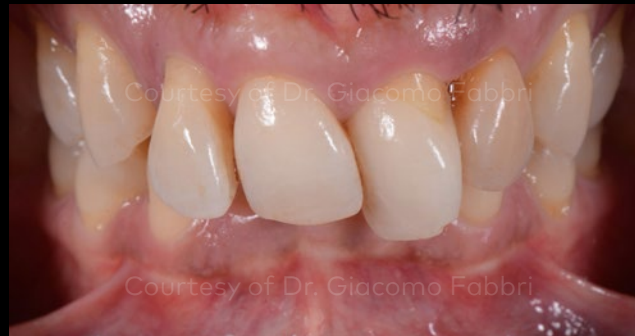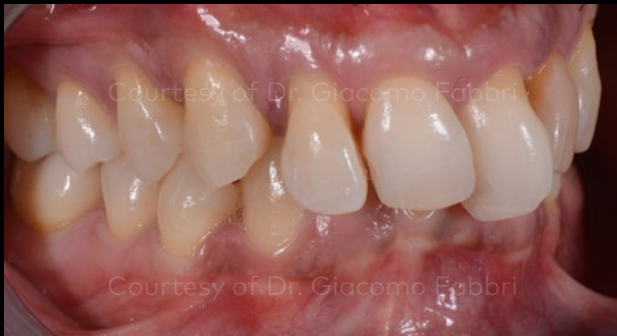Treatment planning

Surgical procedure

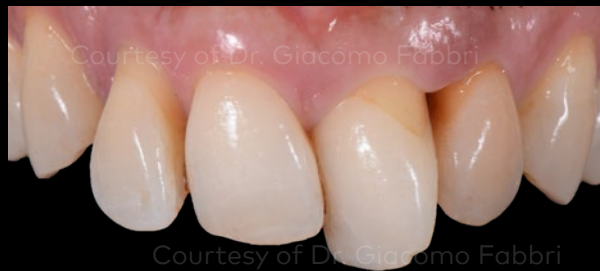Restorative procedure

Outcome

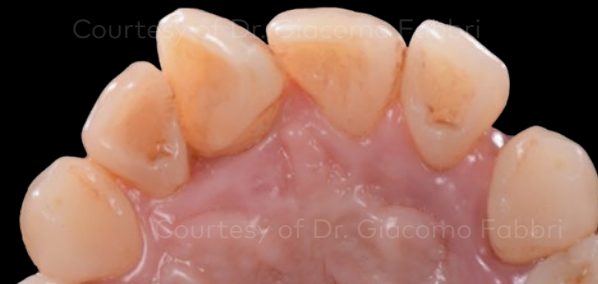Intraoral clinical situation



Intraoral condition



Anterior teeth evaluation



Anterior teeth evaluation - palatal view

Initial clinical situation

Treatment planning

Surgical procedure

Restorative procedure

Outcome

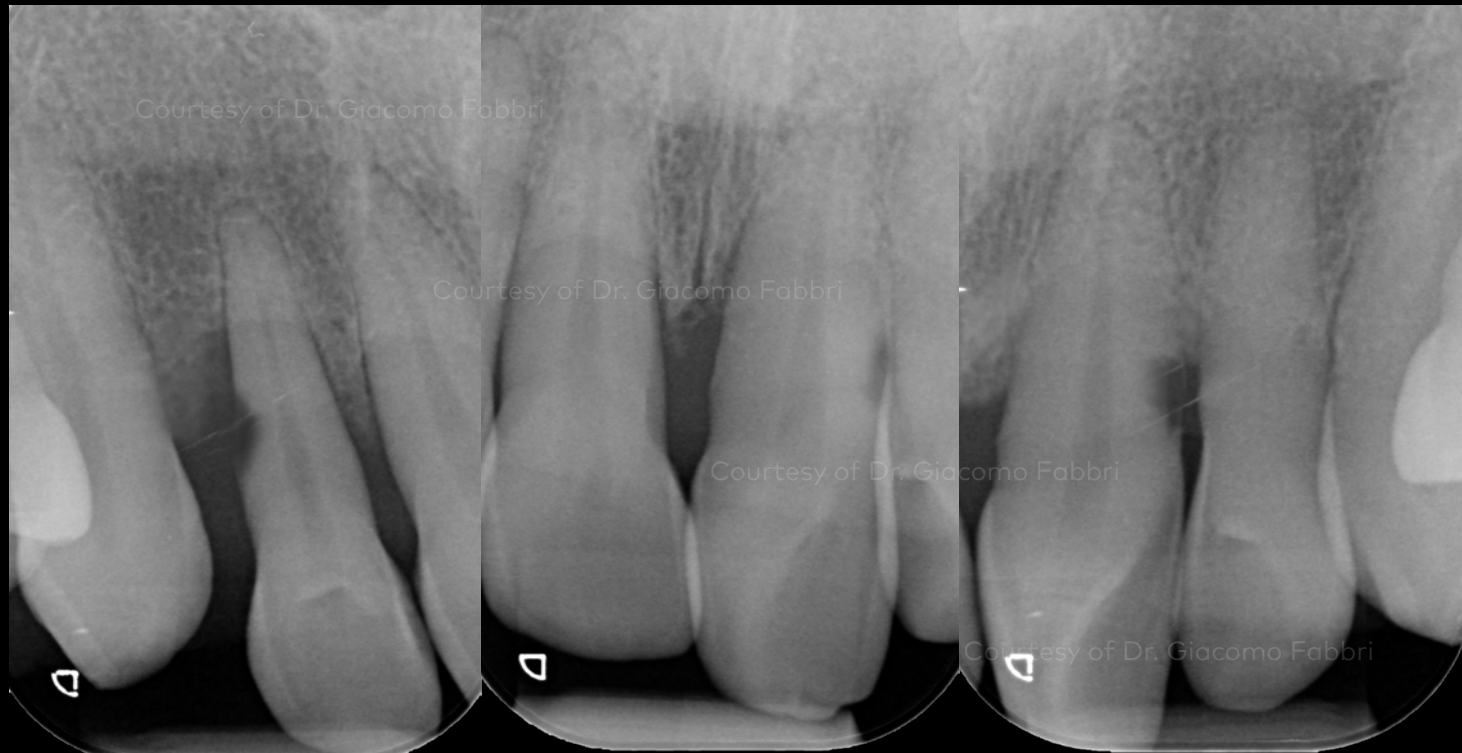Clinical evaluation

The upper incisors present unpleasant esthetics due to dental migration, there is a significant rotation of the tooth 21, absence of soft tissue on the papilla between the teeth 21 and 22. Moreover, gingival recession is present on elements 12, 21 and 22.

X-ray analysis shows a moderate loss of periodontal support on the upper incisors and the presence of severe root lesions on elements 12 and 21.

These two root lesions compromised irreversibly the maintenance of teeth 12 and 21 that will be replaced by dental implants.

An orthodontic therapy is also required in order to idealize teeth position, re-equilibrate the restorative space and favor the re-establishment of a new papilla between 21 and 22.



X-ray evaluation of the upper anterior segment

Initial clinical
situation

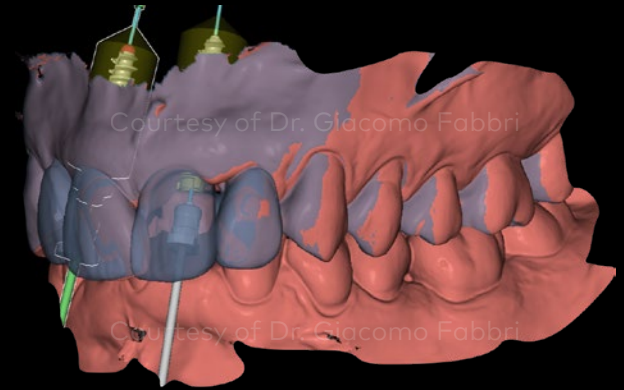
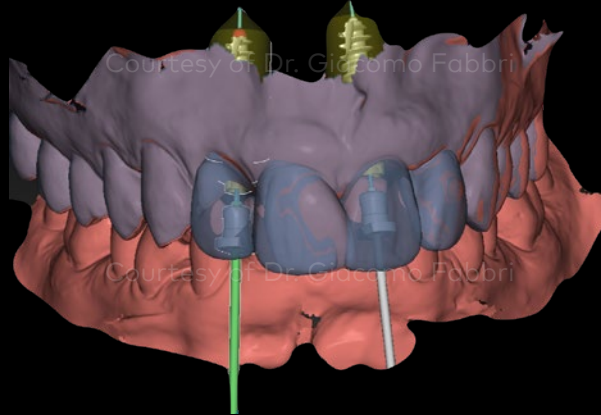
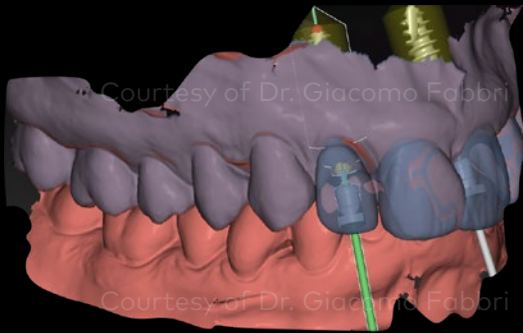
Treatment
planning

Surgical
procedure

Restorative
procedure

Outcome

Digital evaluation



In relation to the clinical and esthetic evaluation a digital wax-up was created with DTX Studio™ Implant in order to plan the implant placement and also the orthodontic therapy in relation to the final prosthetic plan. The DTX Studio Implant software enables ideal planning, including occlusal, prosthetic, bone and soft tissue evaluation.

Initial clinical situation

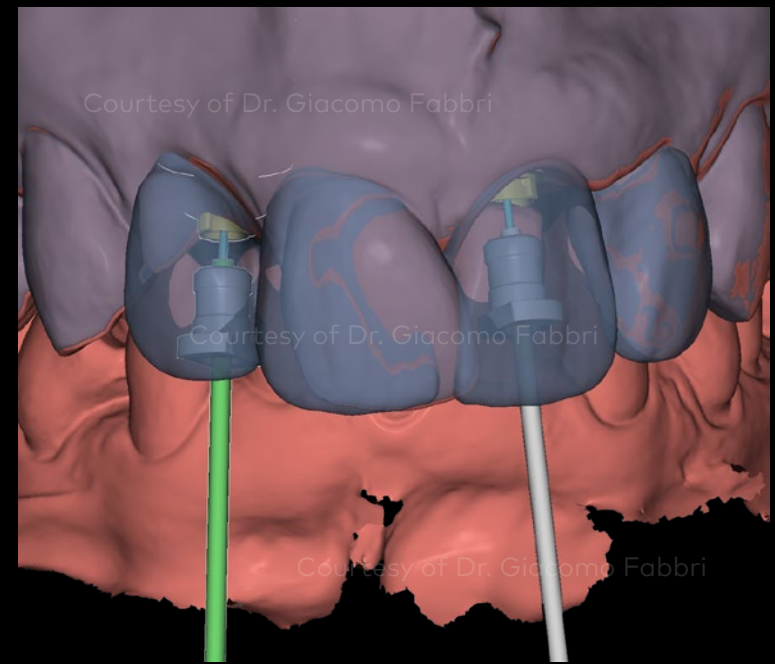
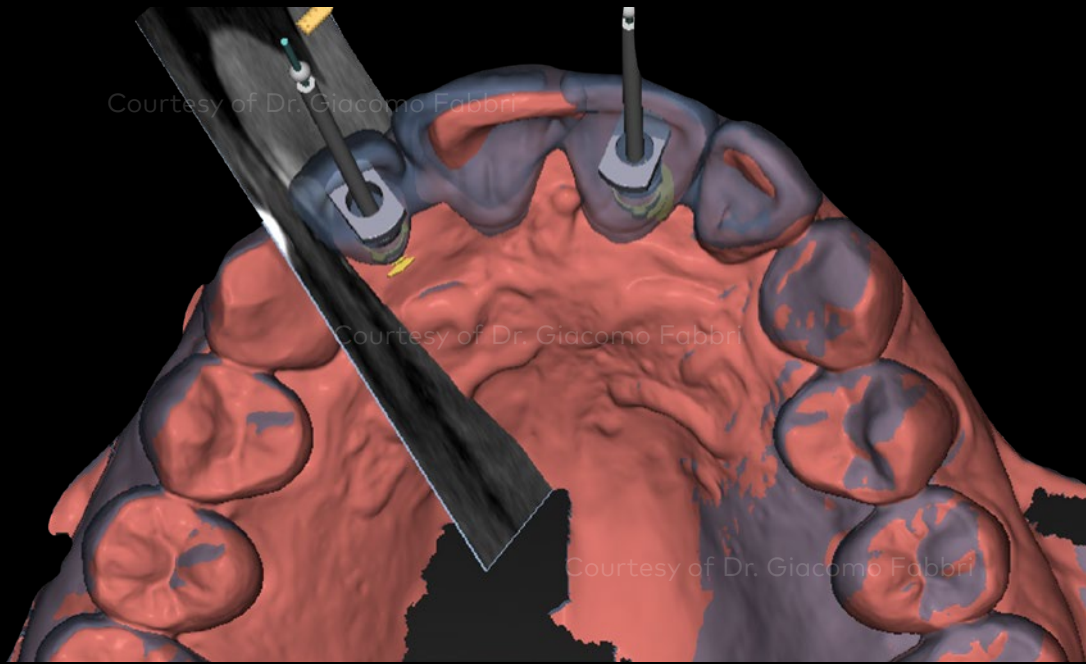
Treatment planning

Surgical procedure

Restorative procedure

Outcome

Digital evaluation



The blue contour represents the digital planning and red represents the initial condition. The implant placement is planned in relation to the final restoration.

N1 Implant RP 13 mm and NP 13 mm were selected for the positions 21 and 12 respectively. The restorative planning with DTX Studio Implant has selected to use N1 Base 2.5 mm height in order to optimize tissue integration and bone integration and will not disturb soft tissue and bone healing throughout the treatment.

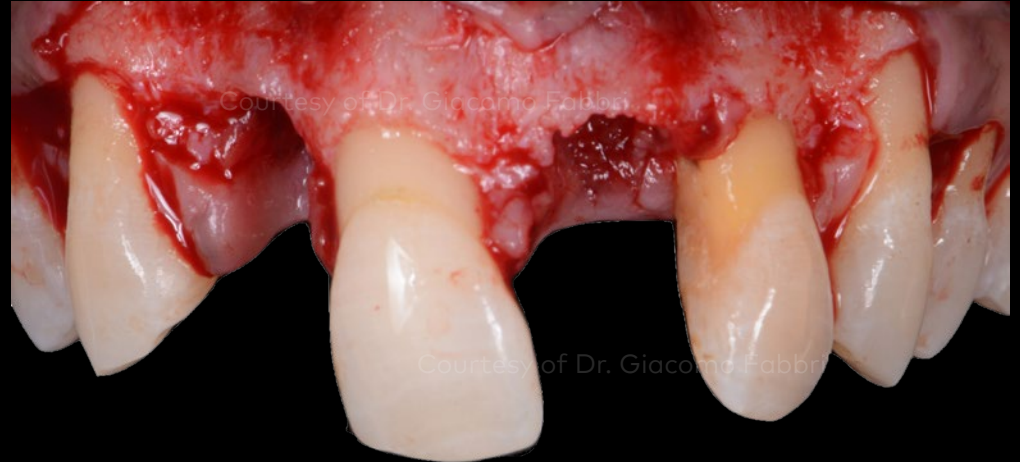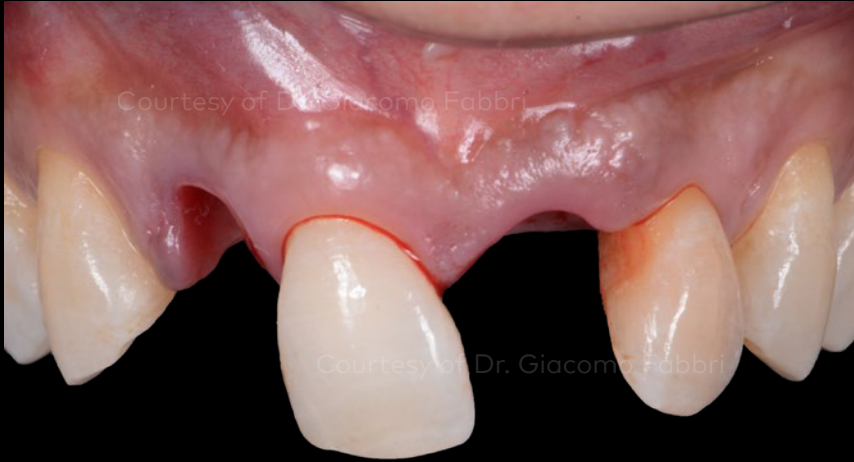Initial clinical situation

Treatment planning

Surgical procedure

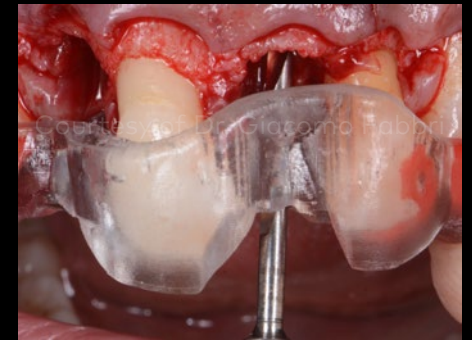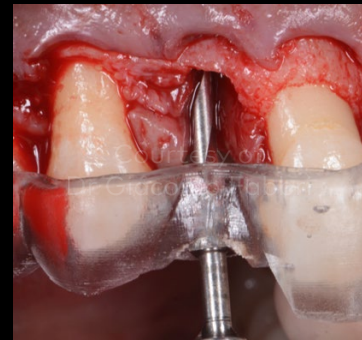
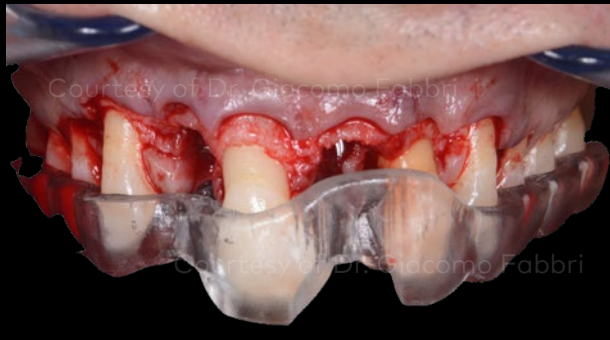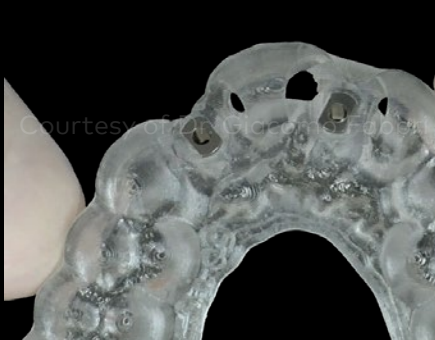Restorative procedure

Outcome



Teeth 12 and 21 are extracted

Flap was elevated according to CAF (coronally advanced flap) technique



Pilot drill guided surgery in relation to the 3D digital planning

Initial clinical situation

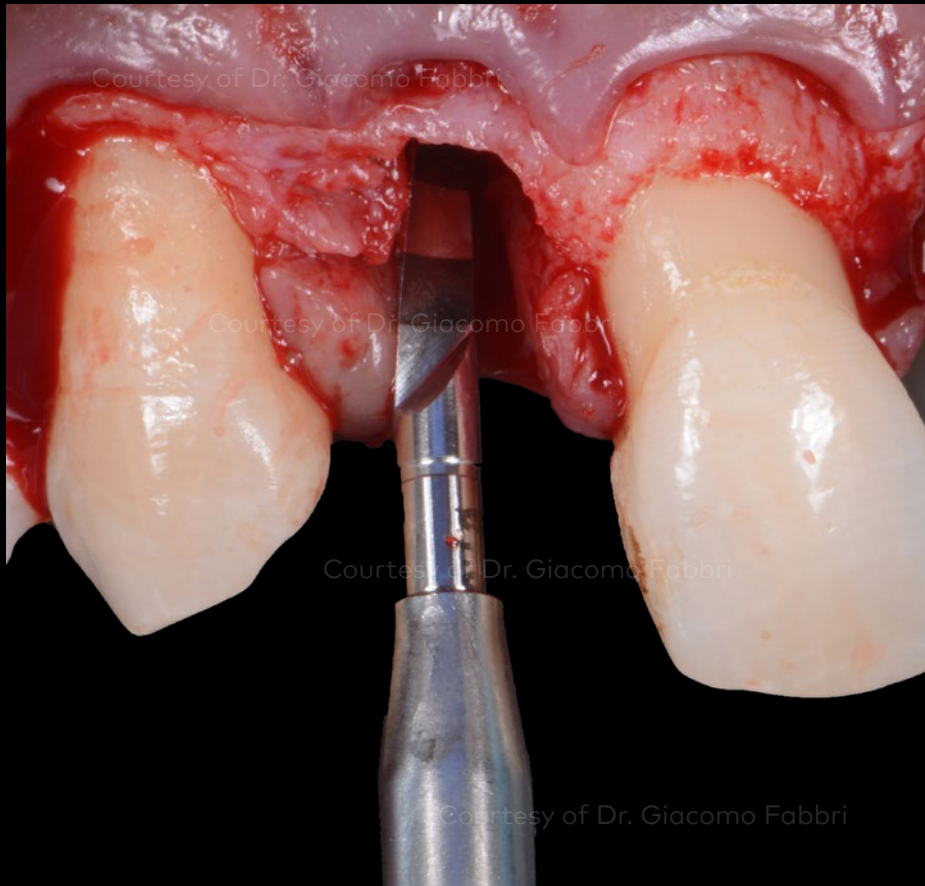
Treatment planning

Surgical procedure

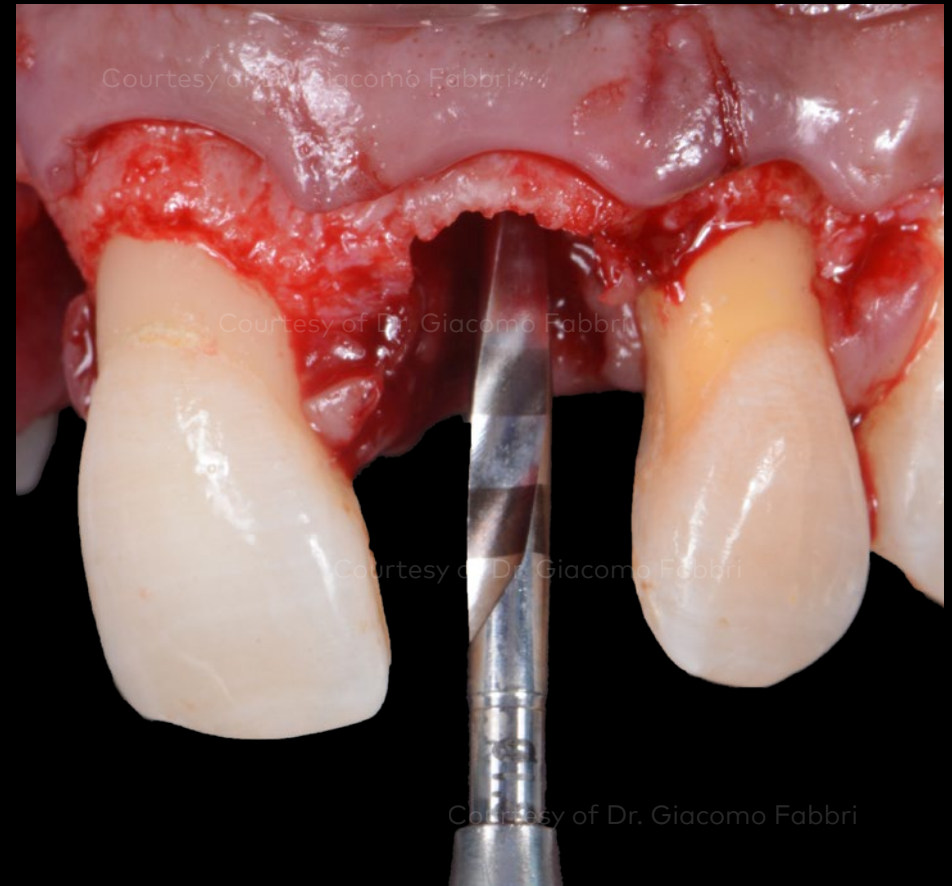
Restorative procedure

Outcome

Initial implant site preparation with OsseoDirector™ instrument



OsseoDirector in site 12



OsseoDirector in site 21

The sharp design of the OsseoDirector tip supports bone engagement and the tapered body allows changes in direction while cutting the pilot osteotomy.

Initial clinical situation

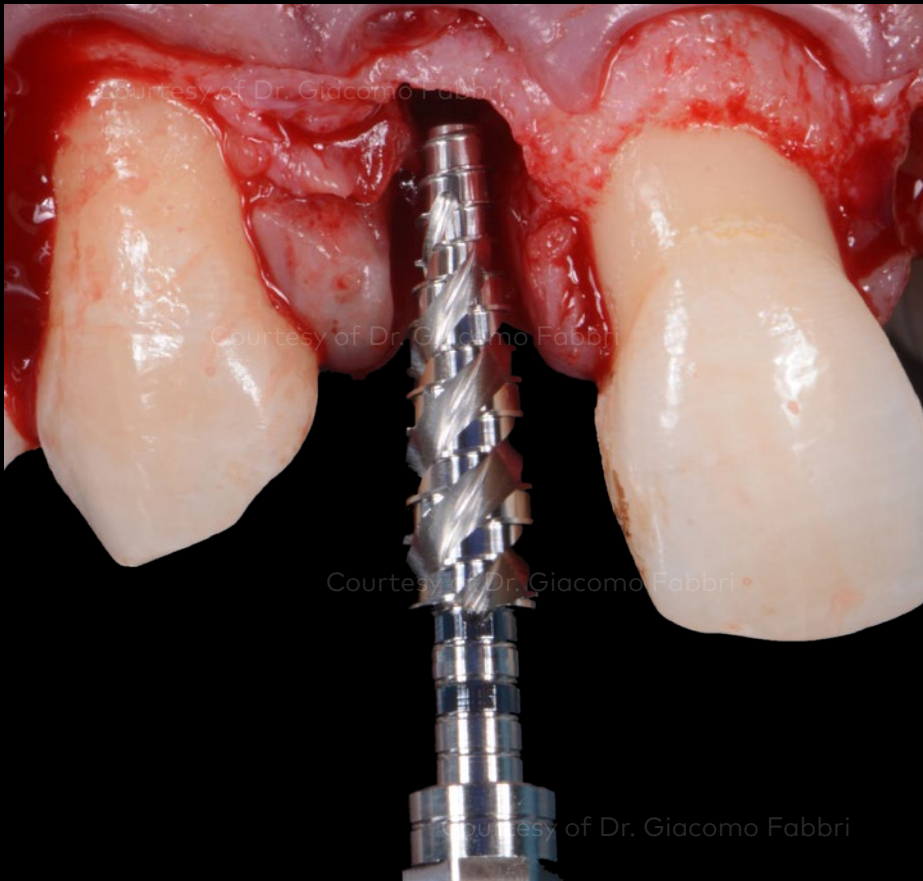
Treatment planning

Surgical procedure

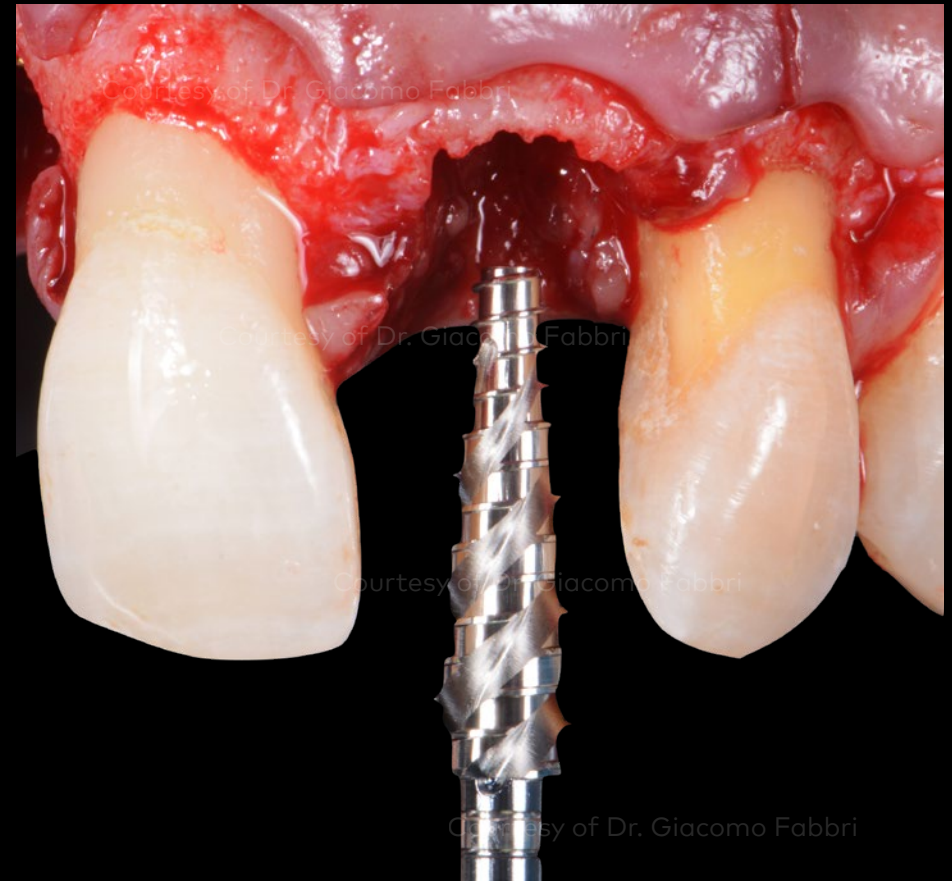Restorative procedure

Outcome

OsseoShaper™ 1 instrument to create the final osteotomy.



OsseoShaper 1 for N1 Implant RP 13 mm in site 12



OsseoShaper 1 for N1 Implant NP 13 mm in site 21

The OsseoShaper 1 creates a specific osteotomy for the co-packed N1 Implant. The torque measured during shaping guides the surgical procedure.

Initial clinical situation

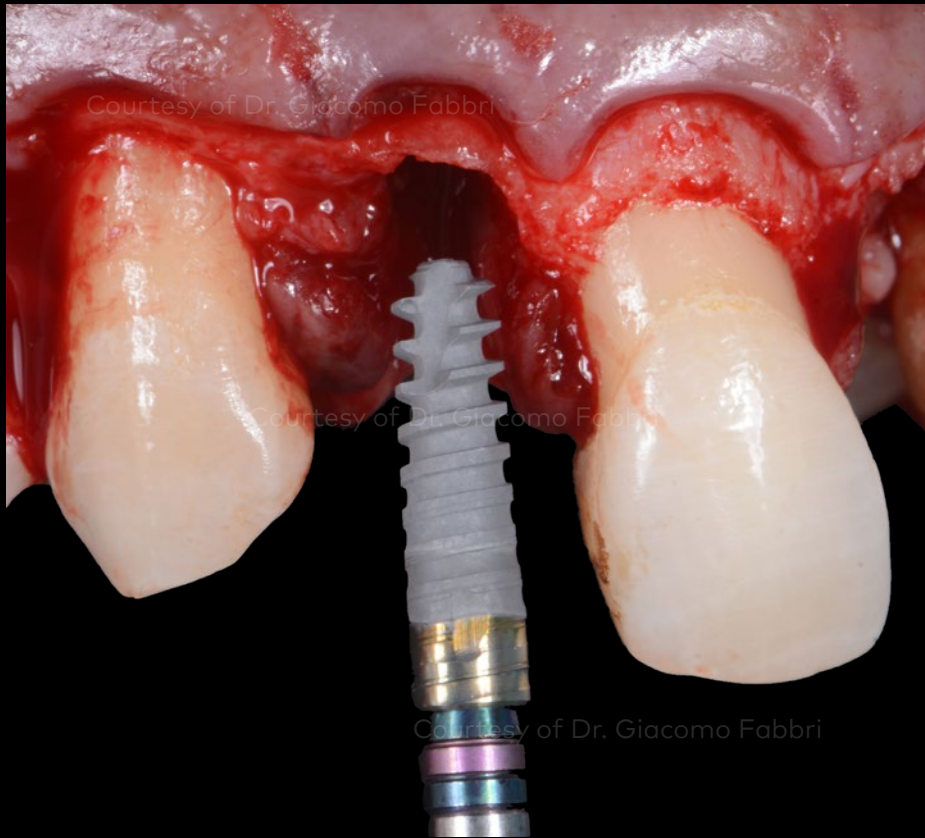Treatment planning

Surgical procedure

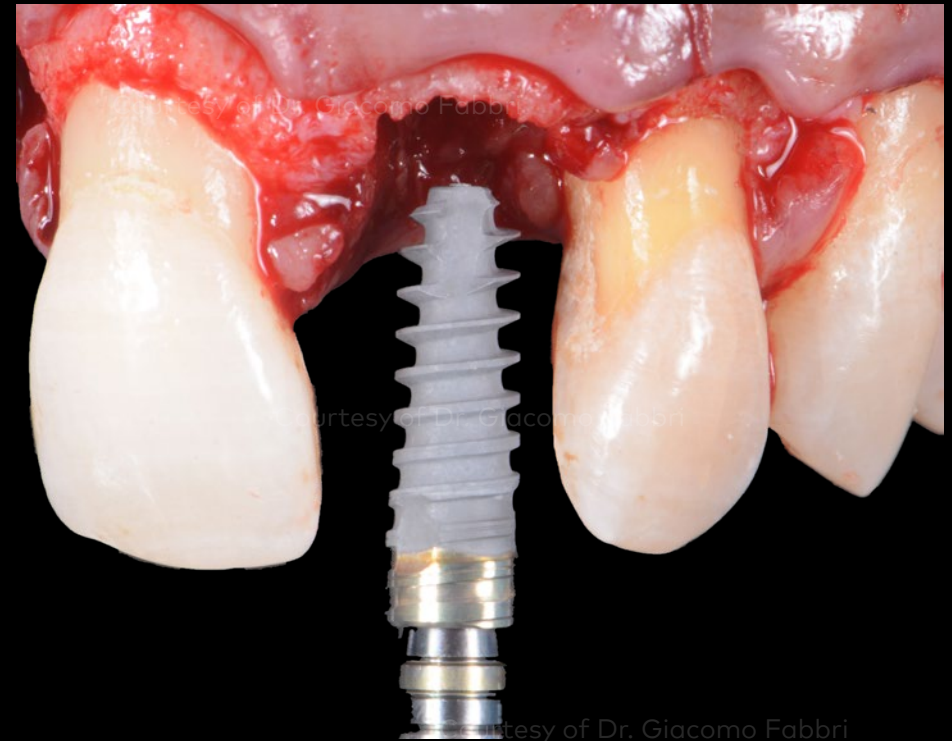
Restorative procedure

Outcome

Placement of N1 system implants



N1 Implant NP 13 mm
The implant achieved final insertion torque of 33 Ncm



N1 Implant RP 13 mm
The implant achieved final insertion torque of 56 Ncm

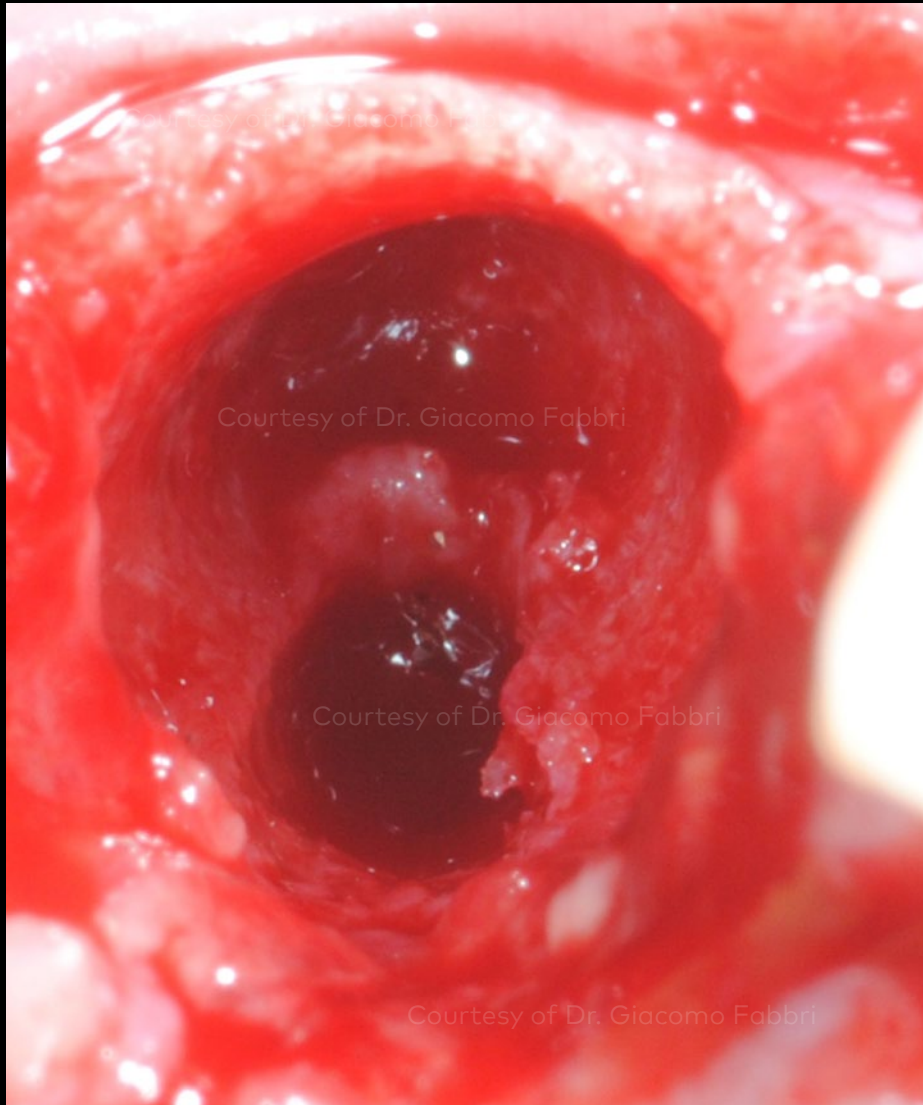
Initial clinical situation

Treatment planning


Surgical procedure

Restorative procedure

Outcome



Implant site after the use of the OsseoShaper 1 in site 21:
Residual bone particles are visible.



Implant in site:
Flat side of the tri-oval collar faces buccally

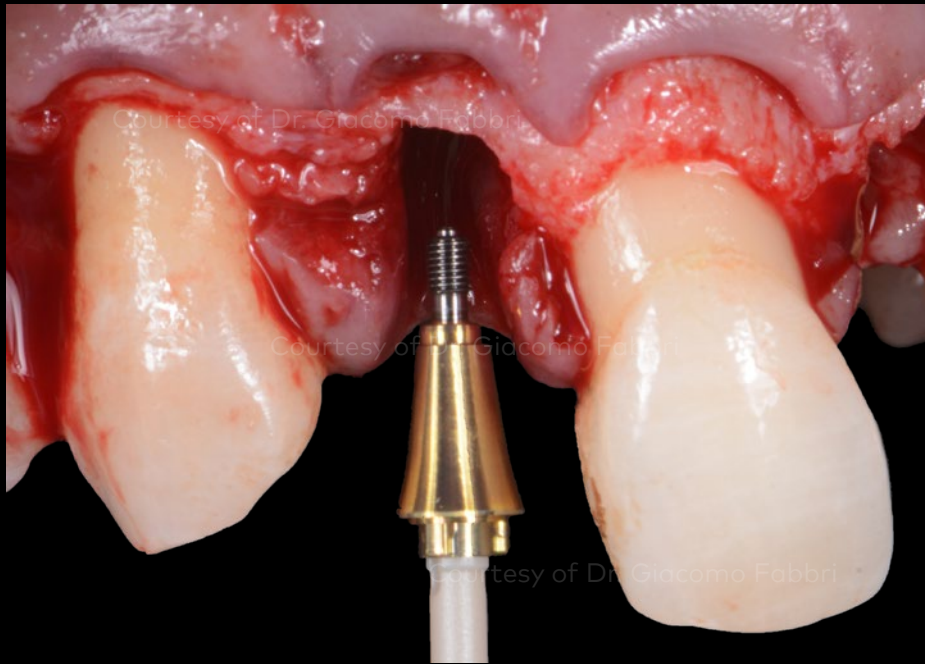
Initial clinical situation

Treatment planning

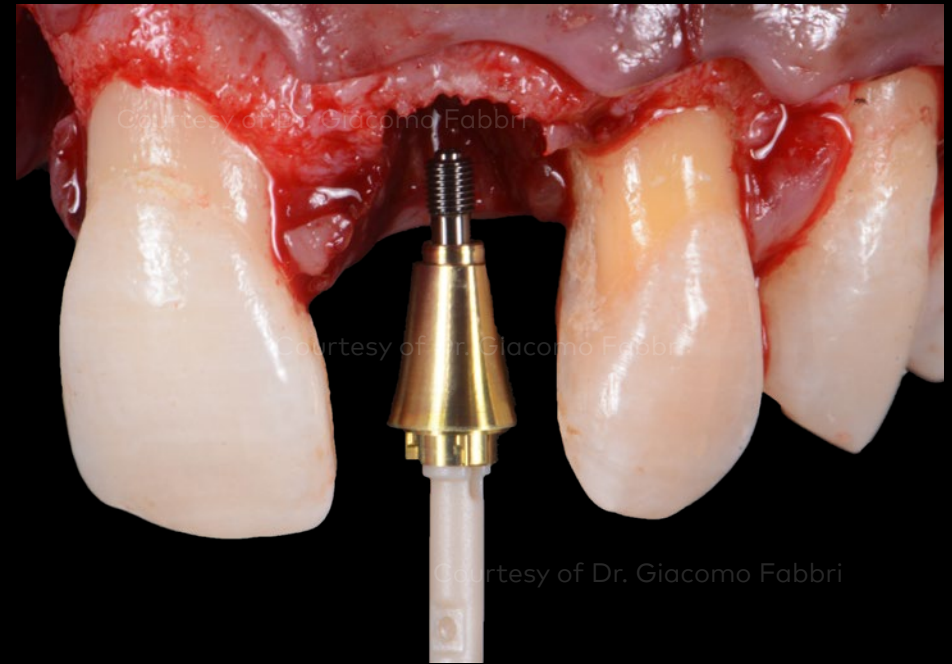Surgical procedure

Restorative procedure

Outcome



The N1 Base 2.5 mm was placed and torqued at 20 N.



The N1 Base 2.5 mm was placed and torqued at 20 N.

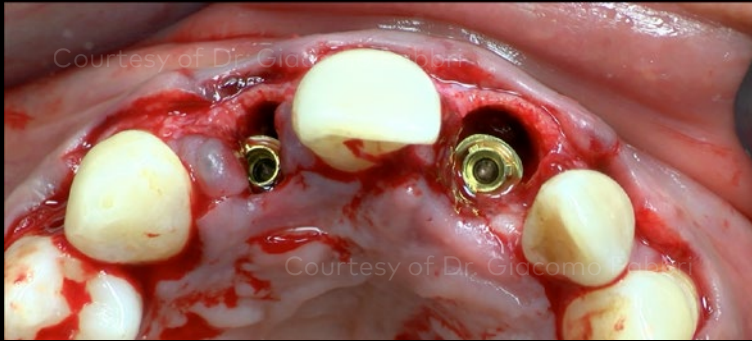
Initial clinical situation

Treatment planning

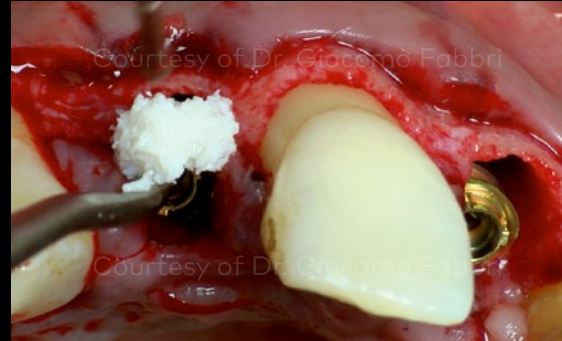Surgical procedure

Restorative procedure

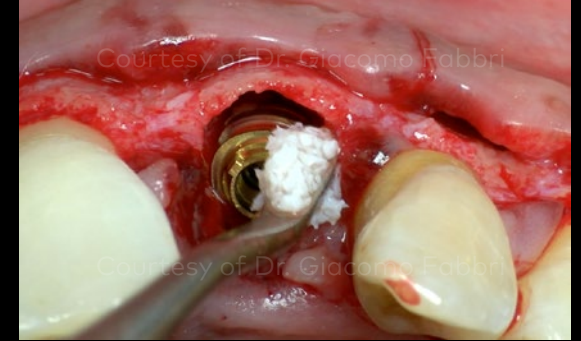
Outcome



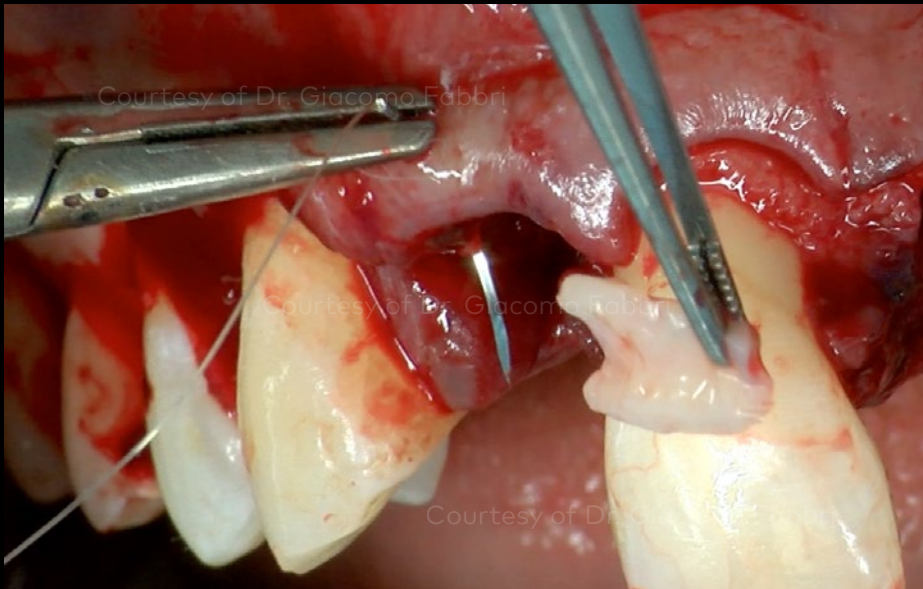
Occlusal view of the bases in situ



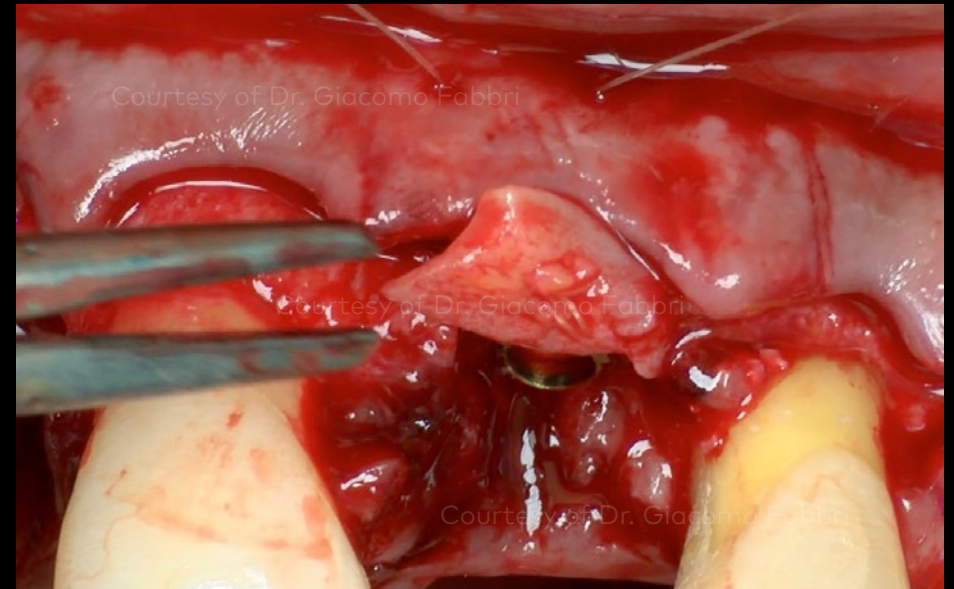
creos™ xenogain bone grafting



creos xenogain bone grafting



Soft tissue management using connective tissue graft (CTG)



Soft tissue grafting

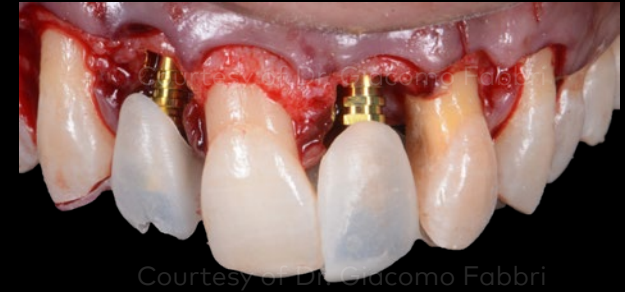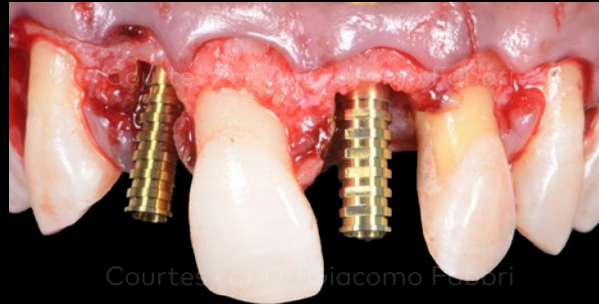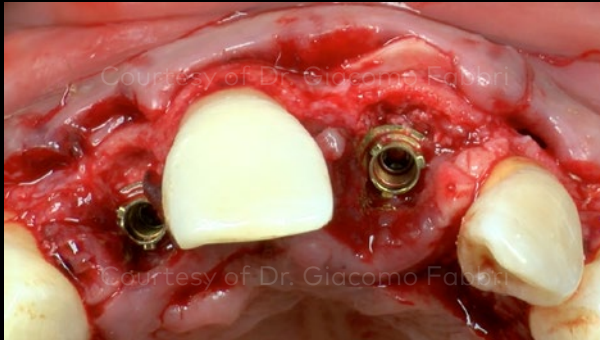
Initial clinical situation

Treatment planning

Surgical procedure

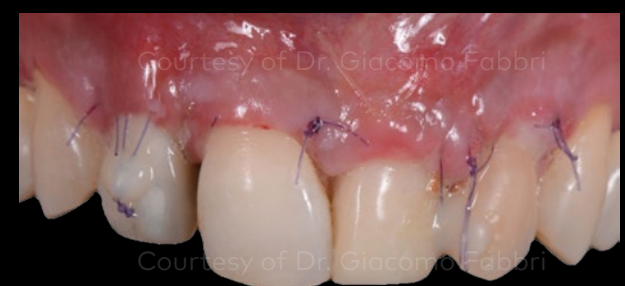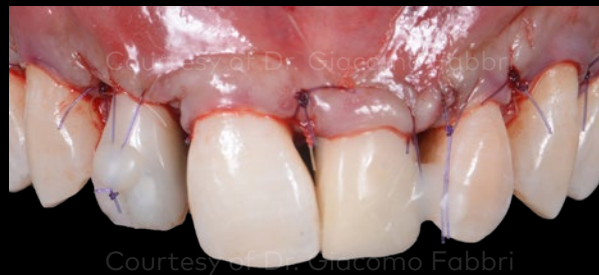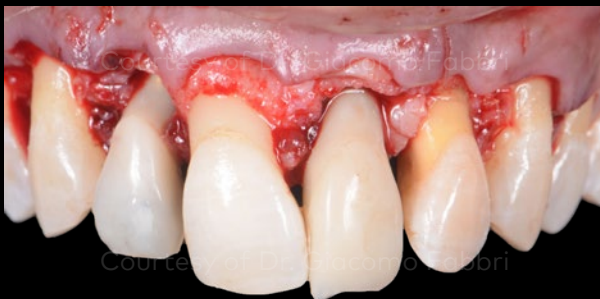Restorative procedure

Outcome



Temporary restorations at abutment level were placed.

Temporary restorations from digital workflow were placed on the temporary abutments by using flowable composite.



Screw-retained temporary abutments in situ

Suture

Healing after 10 days

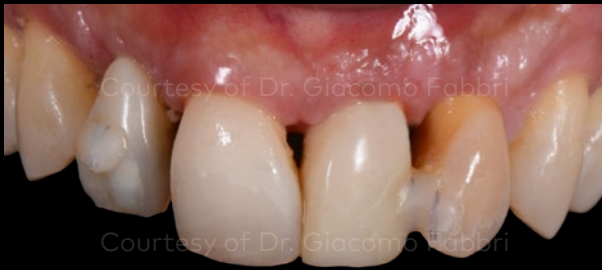Initial clinical situation

Treatment planning

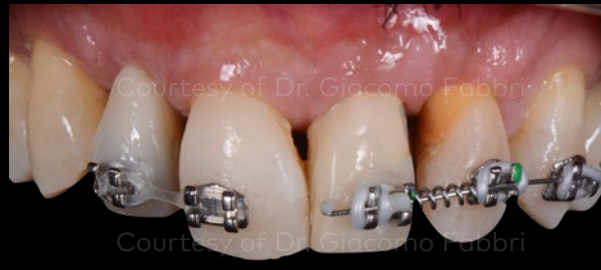Surgical procedure

Restorative procedure

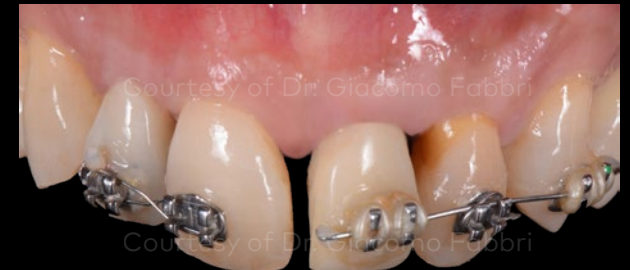Outcome



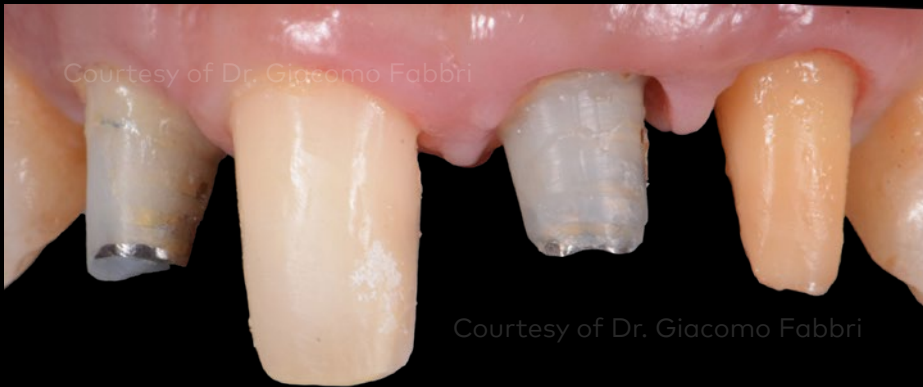Healing after 10 weeks



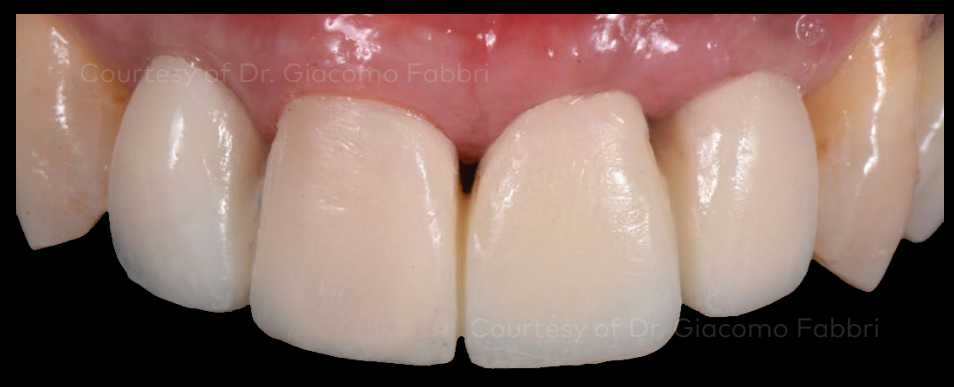After 11 weeks the orthodontic therapy is started



6 months after the orthodontic therapy



New temporary restoration:
Teeth and abutments preparation



New temporary cement base restoration in situ

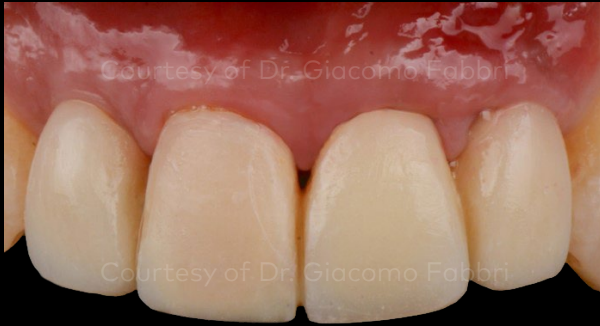Initial clinical situation

Treatment planning

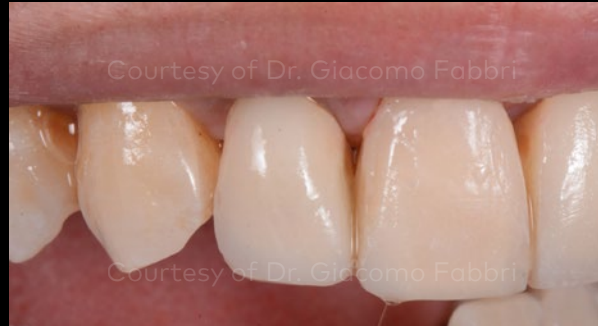Surgical procedure

Restorative procedure

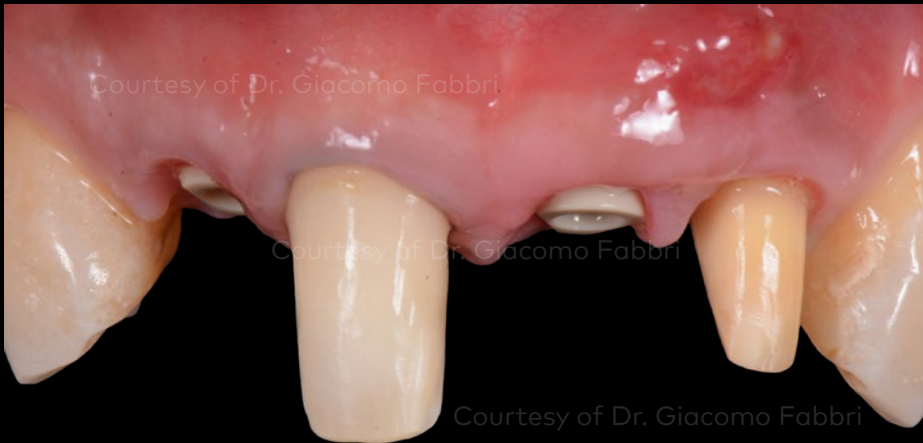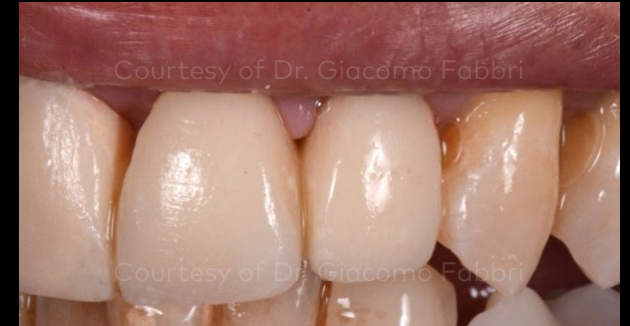Outcome



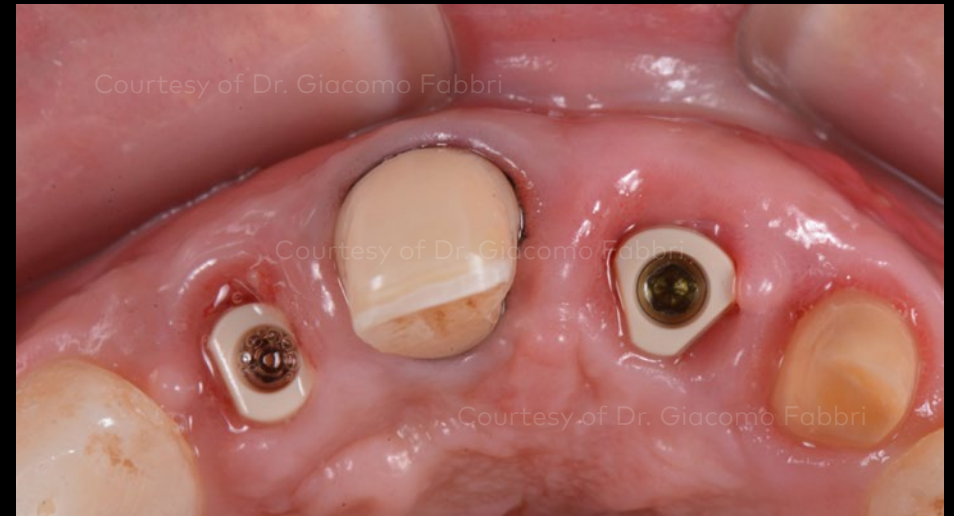Soft tissue healing 4 weeks after the soft tissue surgery, intra-oral evaluation.



Extra-oral evaluation of the soft tissue healing 4 weeks after the soft tissue surgery.



Final impression was taken 6 weeks after the soft tissue surgery using N1 Base scan abutment.



Occlusal view

Initial clinical situation

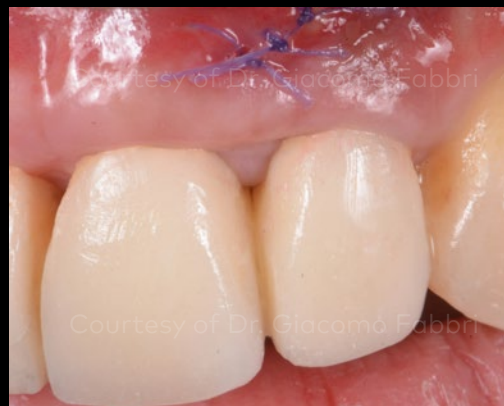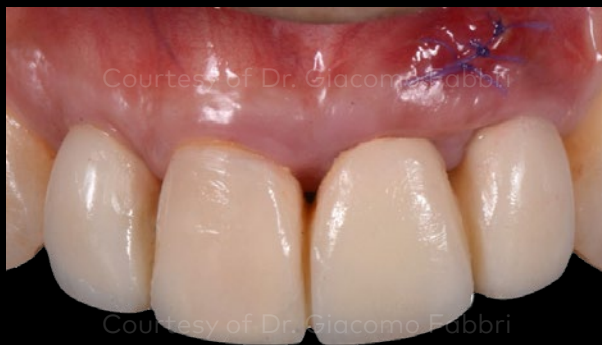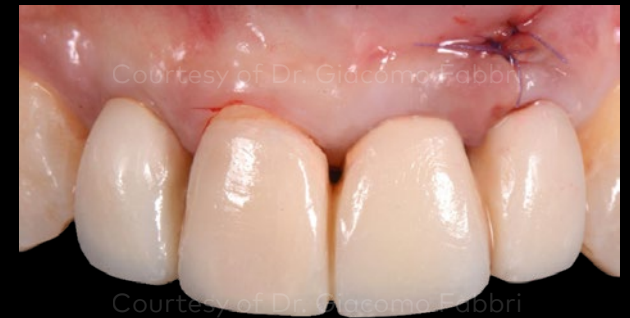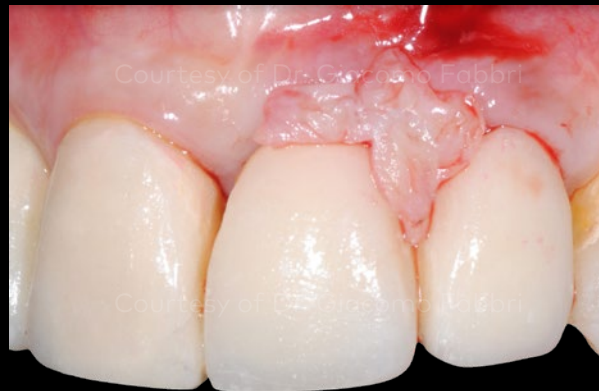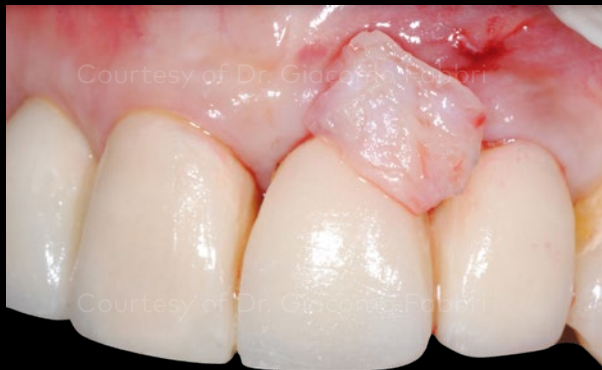Treatment planning

Surgical procedure

Restorative procedure

Outcome

Soft tissue graft to increase the papilla volume between 21 and 22. A connective tissue graft was harvested from the palate and placed in the papilla area using tunnel technique.



Soft tissue healing 2 weeks post surgery

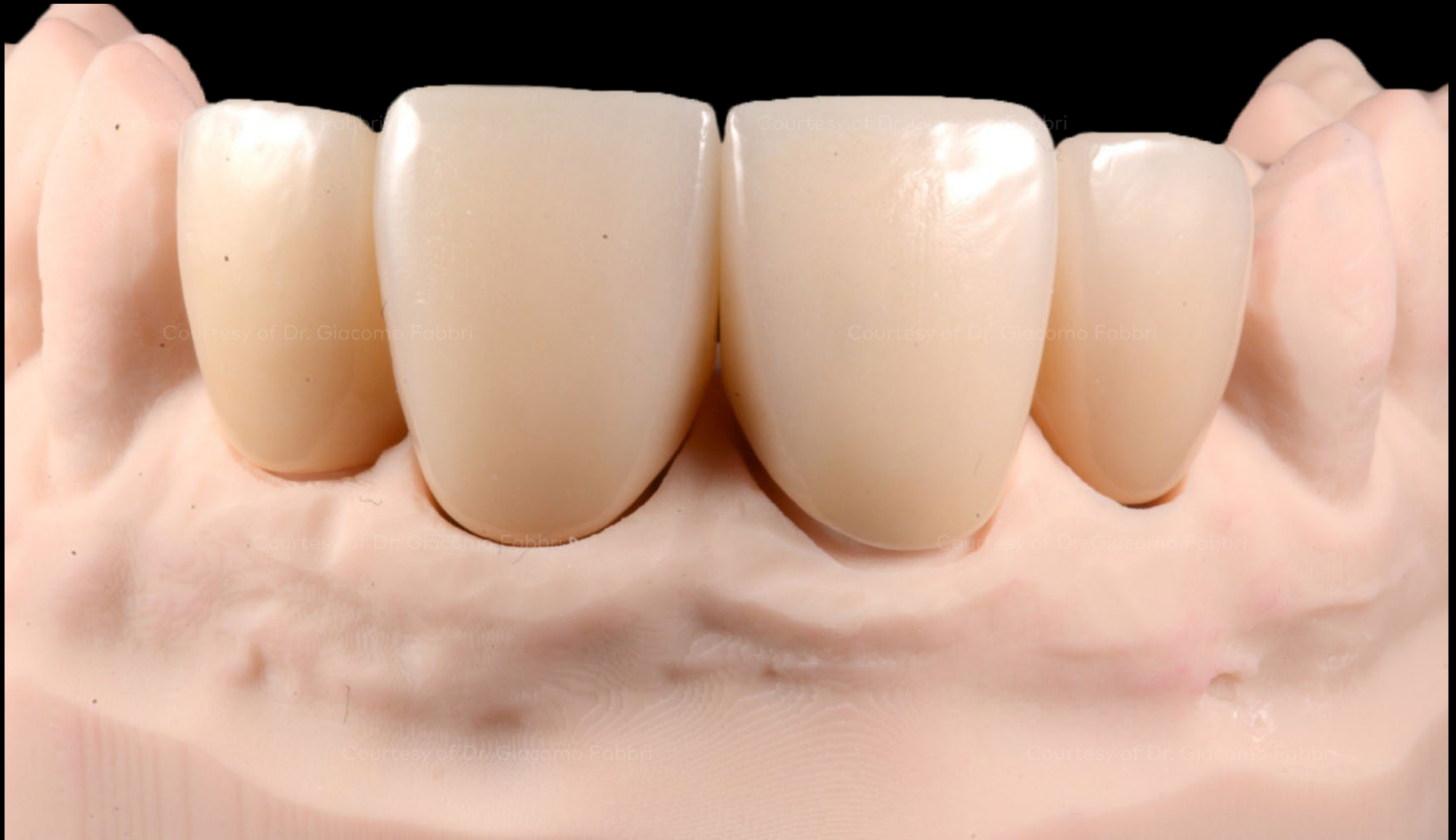Initial clinical situation

Treatment planning

Surgical procedure

Restorative procedure

Outcome



Final Zirconia NobelProcera® restoration placed on the 3D printed model

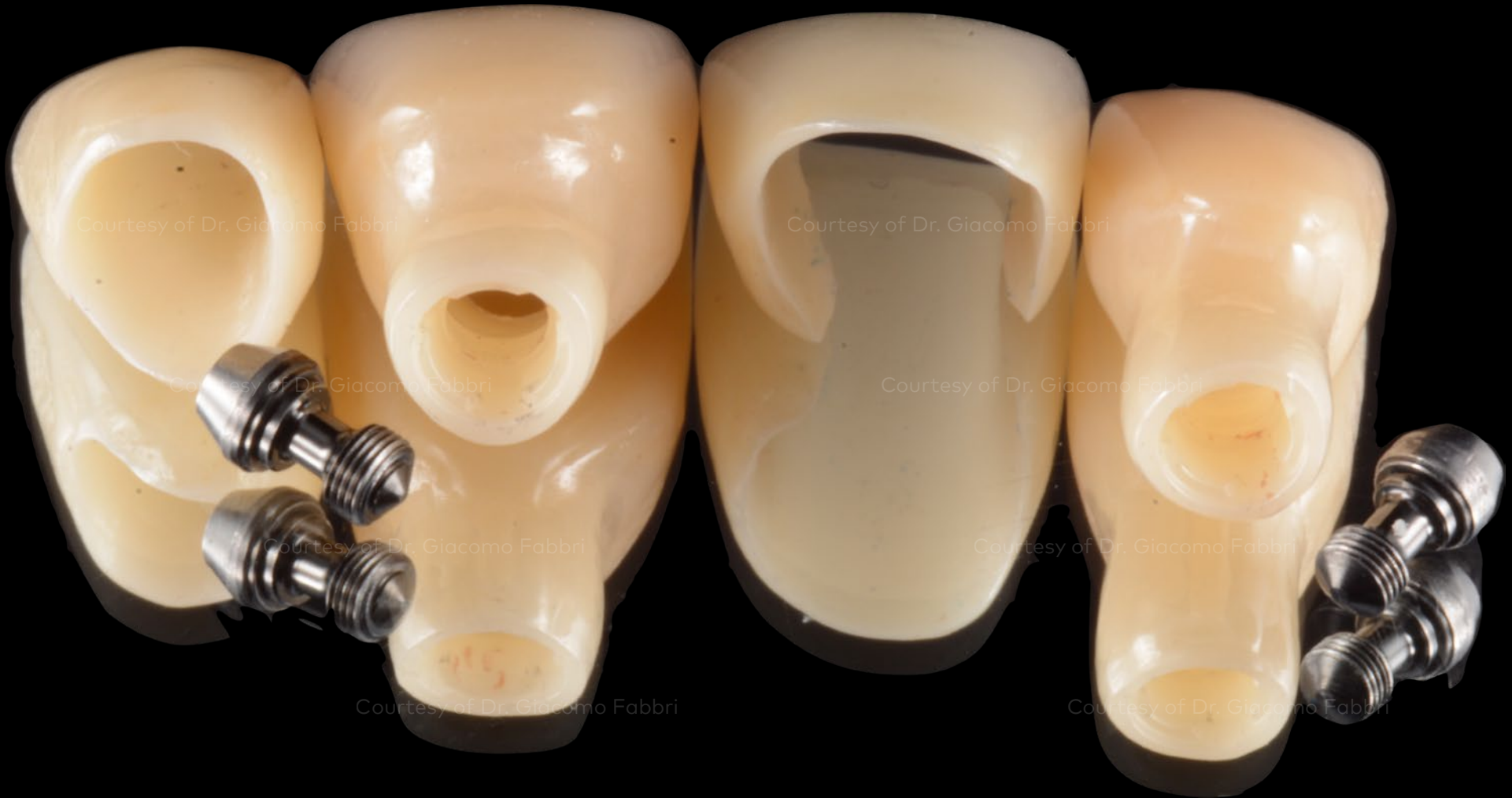Initial clinical situation

Treatment planning

Surgical procedure

Restorative procedure

Outcome



Final Zirconia NobelProcera restoration: Bonded teeth supported zirconia restoration for 22 and 11 and screw-retained Zi restoration placed at the base level on N1 Implant RP at 21, and N1 system implant NP at 12.

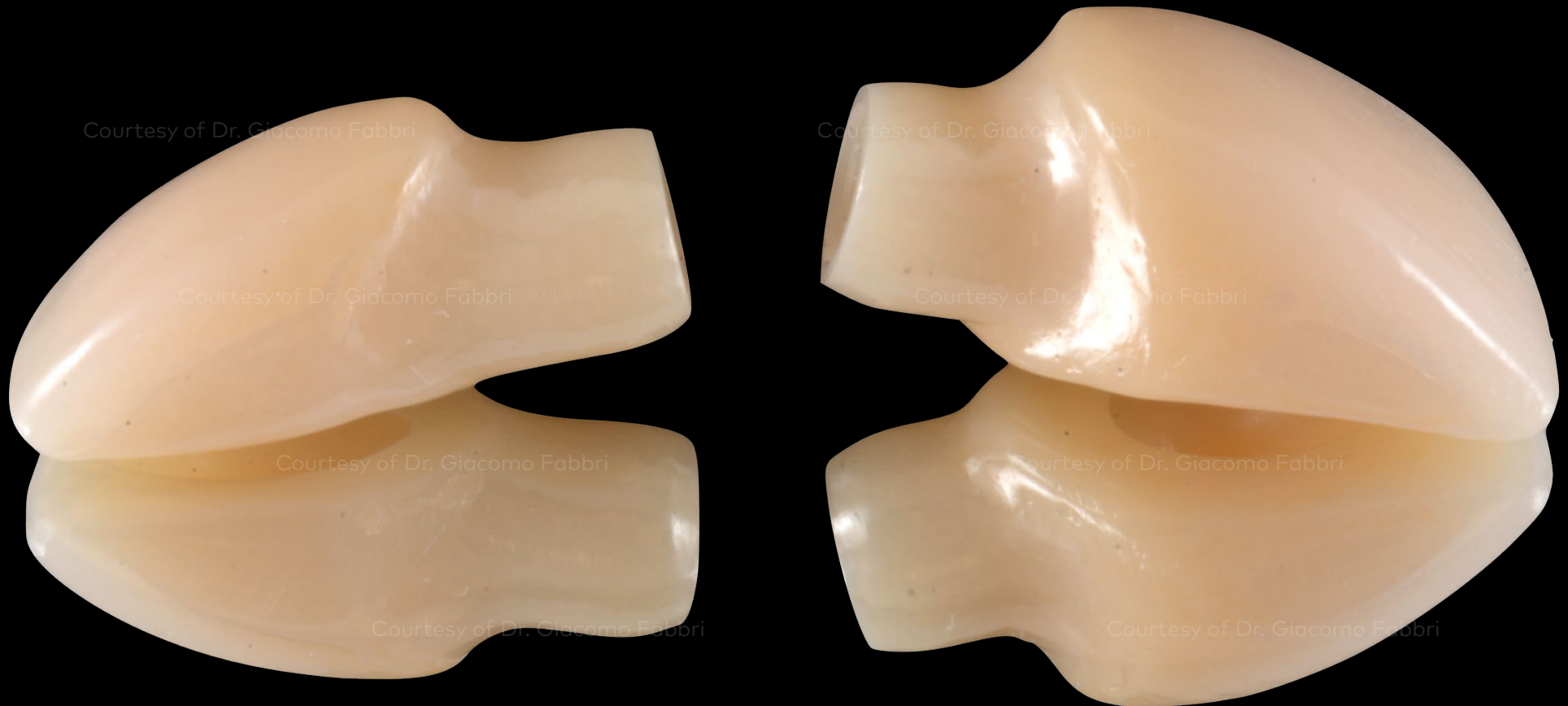Initial clinical situation

Treatment planning

Surgical procedure

Restorative procedure

Outcome



Screw-retained zirconia restorations: Detailed view of the morphology and surface refinement used in the sub-lingual portions.

Initial clinical situation

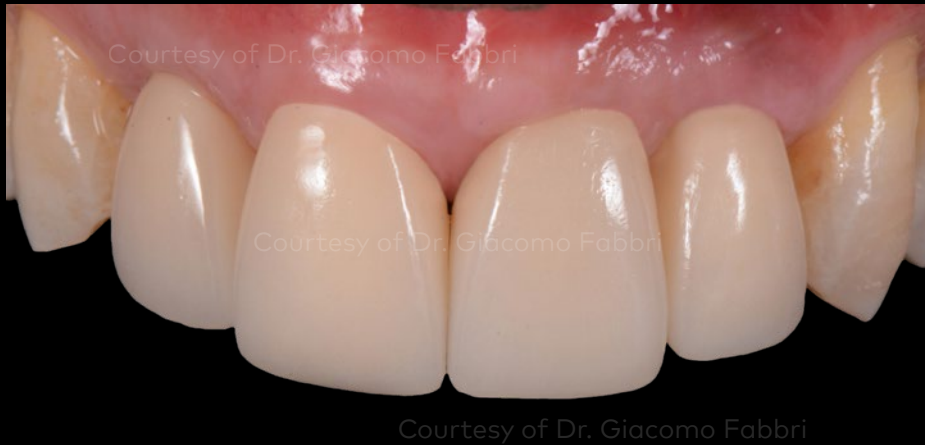Treatment planning

Surgical procedure

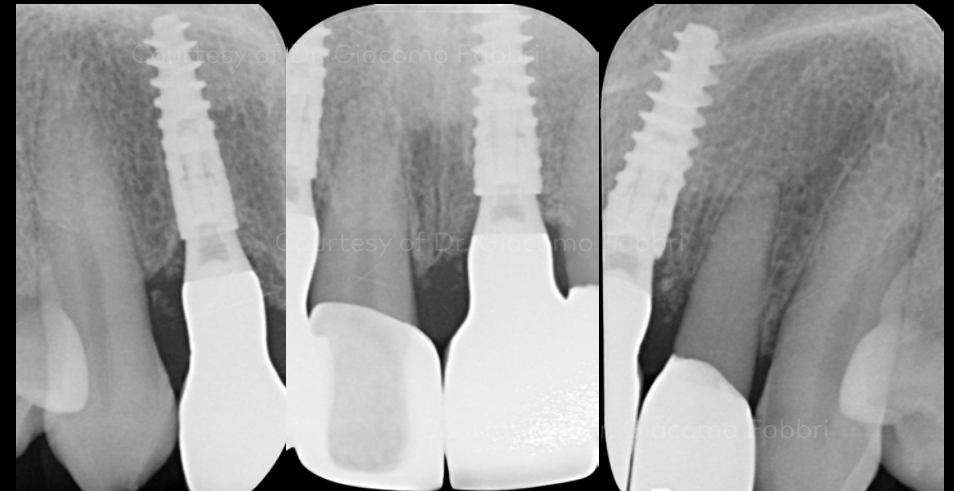
Restorative procedure

Outcome

Try-in of the final restorations before the cut-back and the layering procedures.



Soft tissue evaluation:
The fully-integrated 3D multidisciplinary approach allows us to achieve an excellent pink esthetic with an ideal soft tissue contour and dental proportion.



X-ray evaluation:
X-rays show excellent integration of the restoration and excellent bone stability 1 year after implant placement.

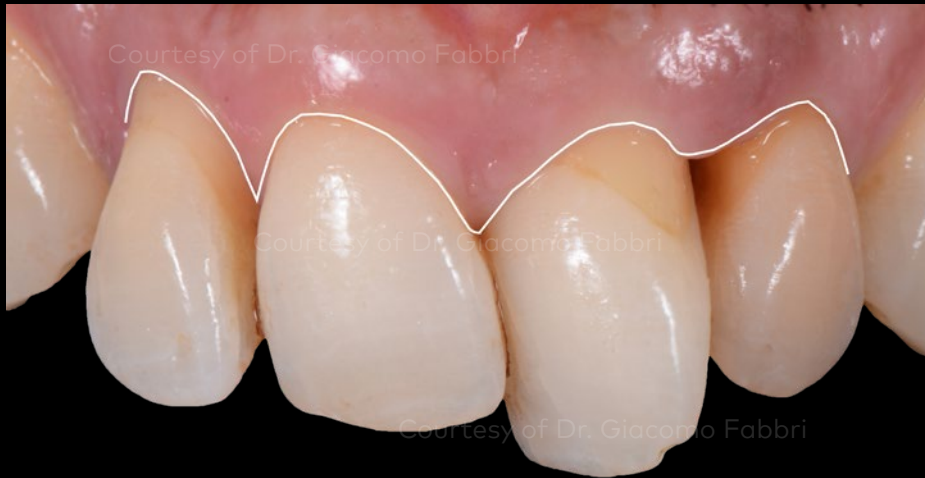Initial clinical situation

Treatment planning

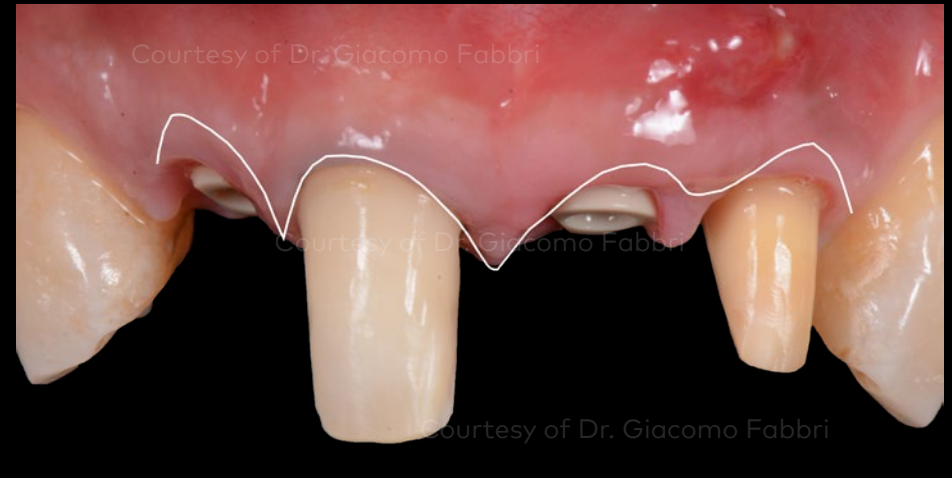Surgical procedure

Restorative procedure

Outcome



Baseline



Final impression

The white line represents the soft tissue outlines before and during the treatment.

The comparison of the soft tissue outline before and after the therapy shows the improvement in soft tissue morphology, particularly at papilla level between 21 and 22.

Initial clinical situation

Treatment planning

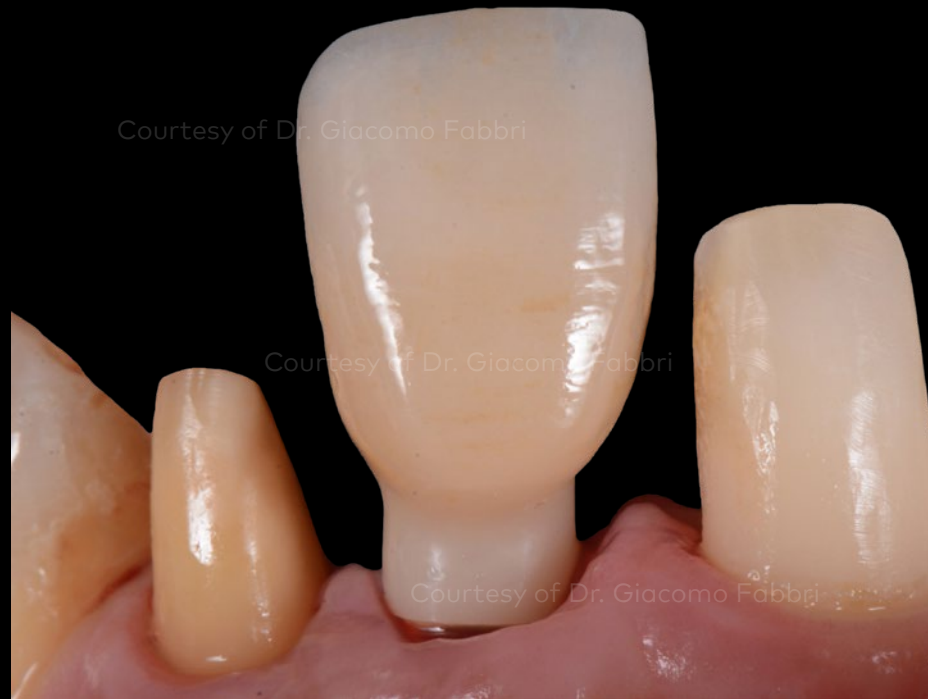Surgical procedure

Restorative procedure

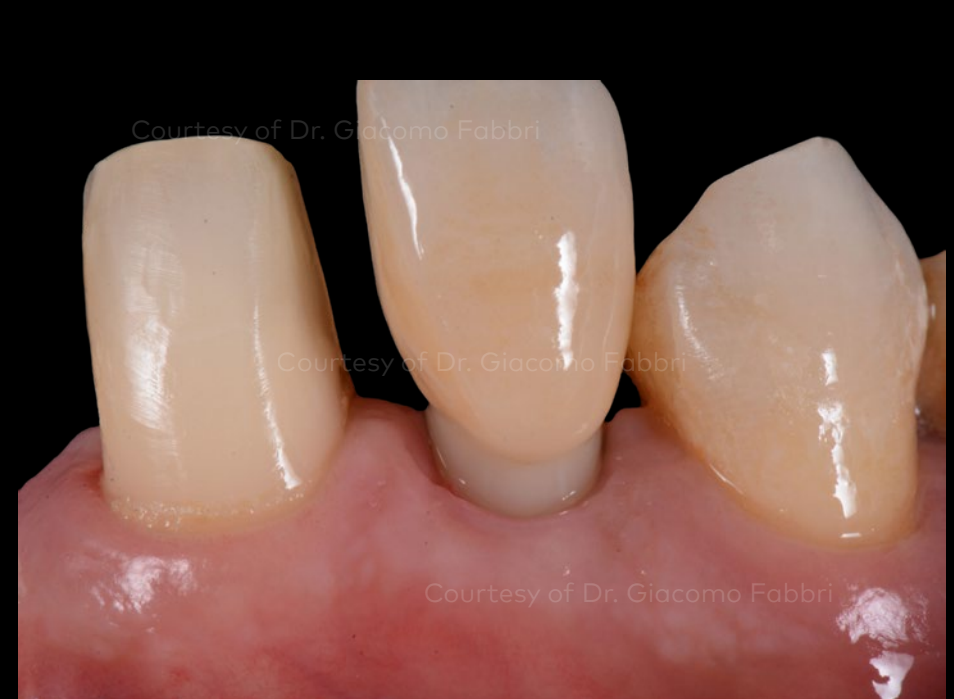Outcome

Delivery of the final restorations: 1 year after implant placement

21



12



NobelProcera full zirconia screw-retained crowns placed at base level

Initial clinical situation

Treatment planning

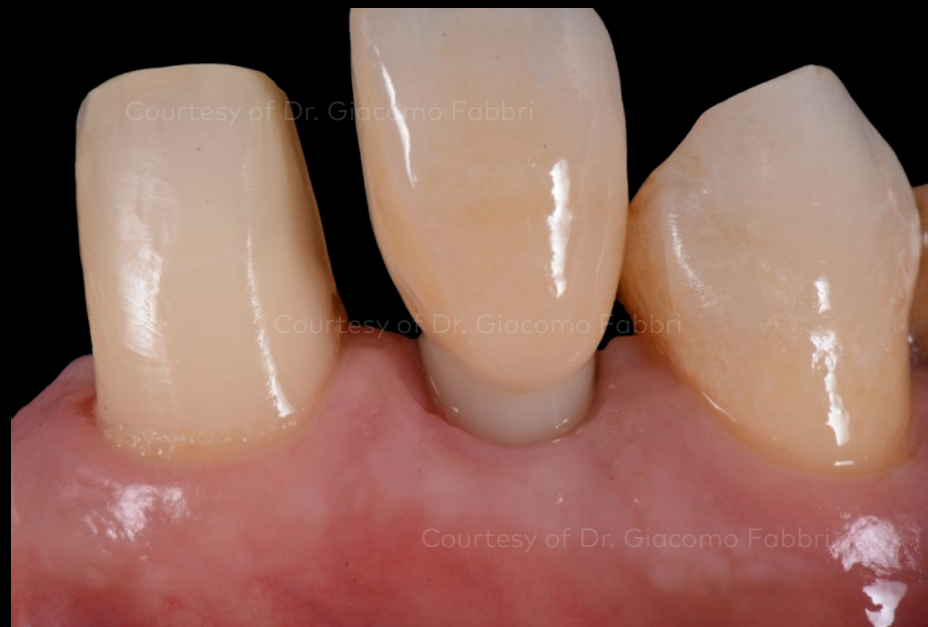Surgical procedure

Restorative procedure

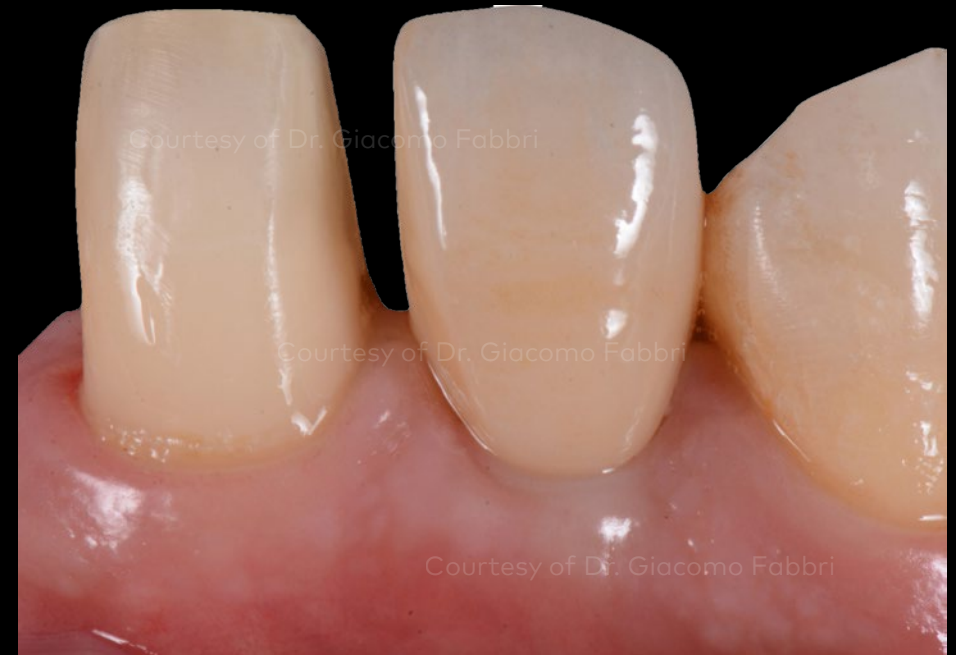Outcome

Delivery of the final restorations: 1 year after implant placement

12



12



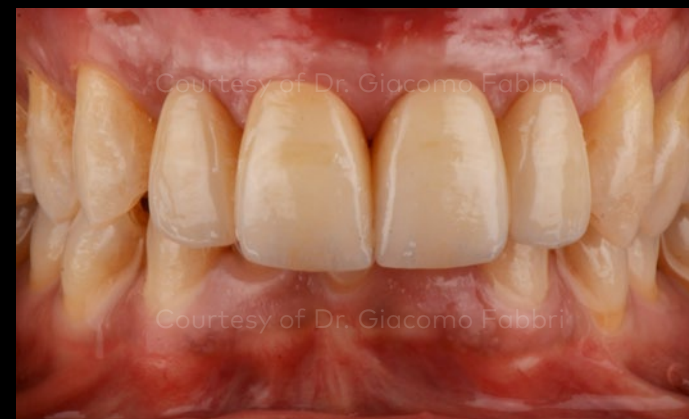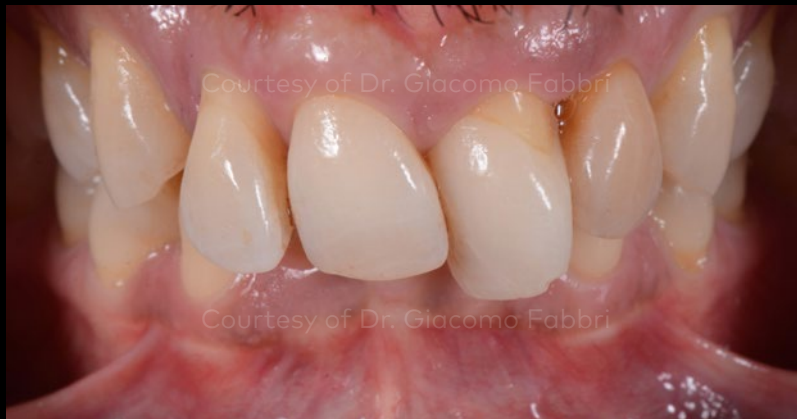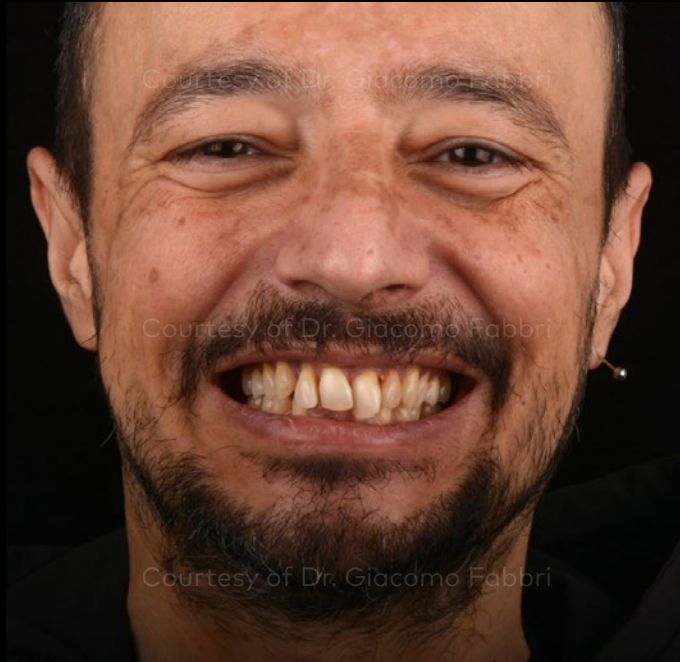Initial clinical situation

Treatment planning

Surgical procedure

Restorative procedure

Outcome



Before the therapy

After the therapy

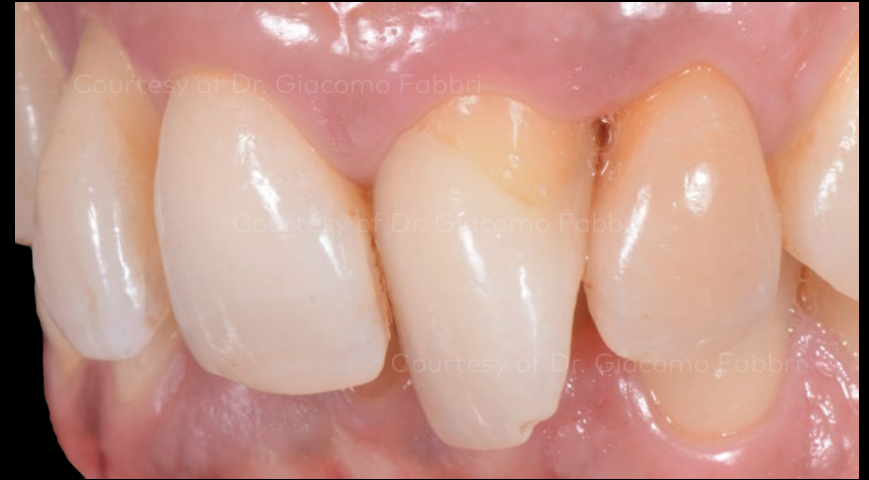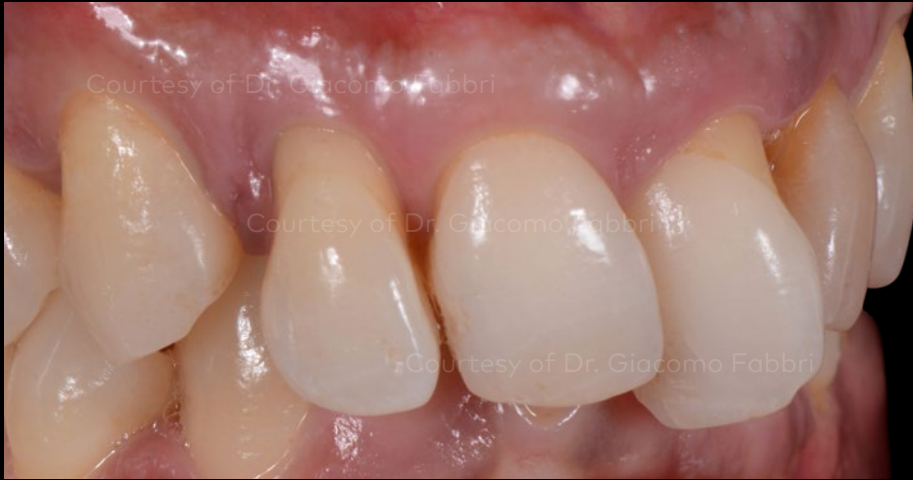Initial clinical situation

Treatment planning

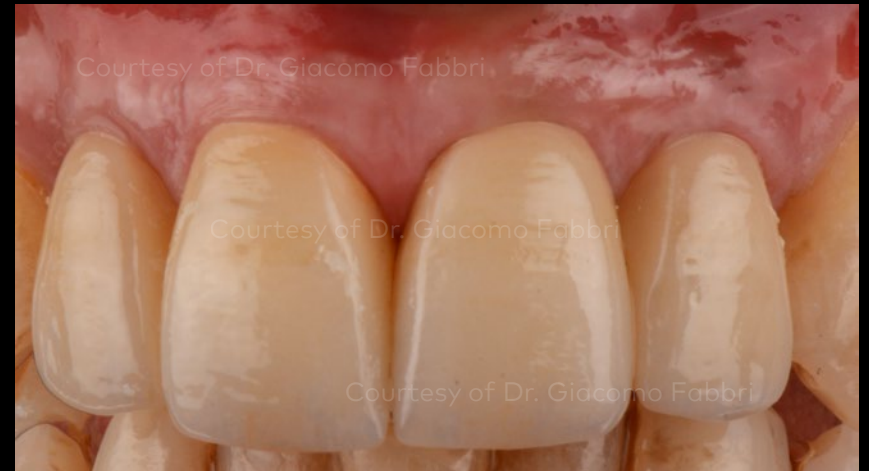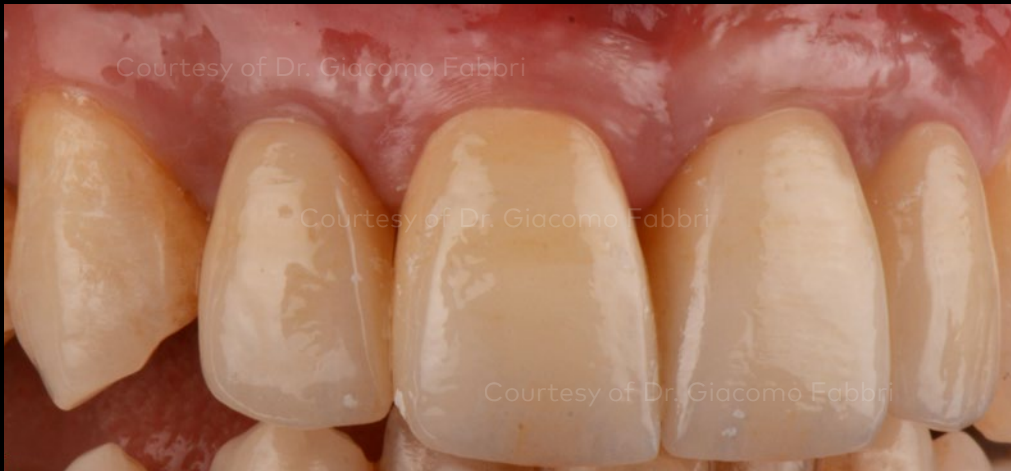Surgical procedure

Restorative procedure

Outcome



Baseline



3-month follow-up

Initial clinical situation

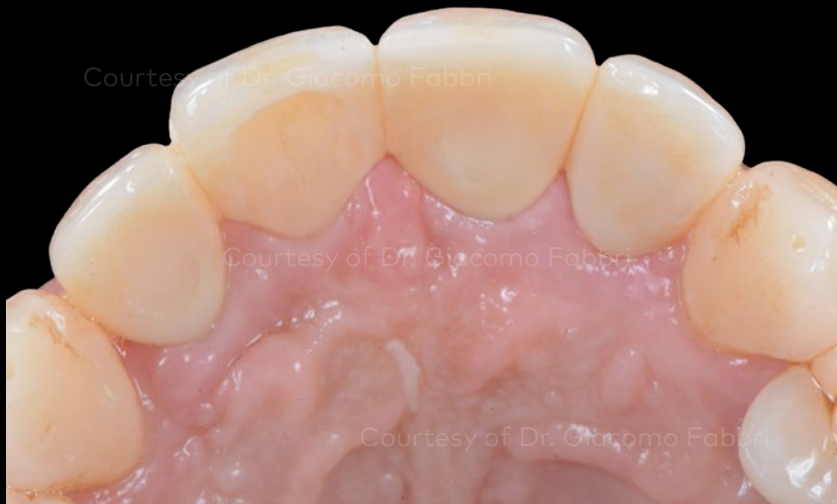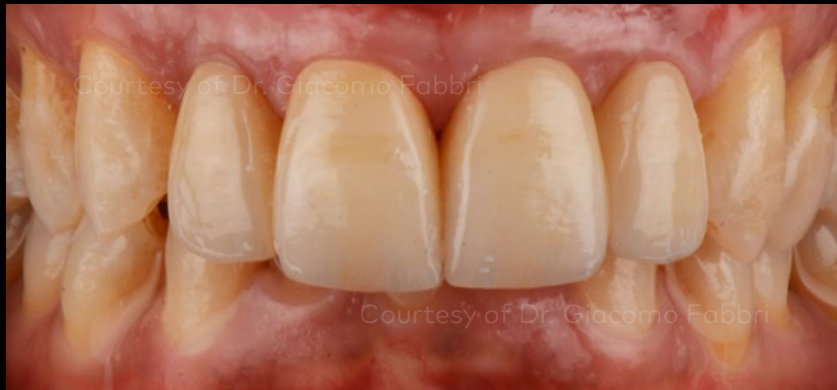Treatment planning

Surgical procedure

Restorative procedure

Outcome

Final restorations: 1 year after implant placement



Initial clinical
situation

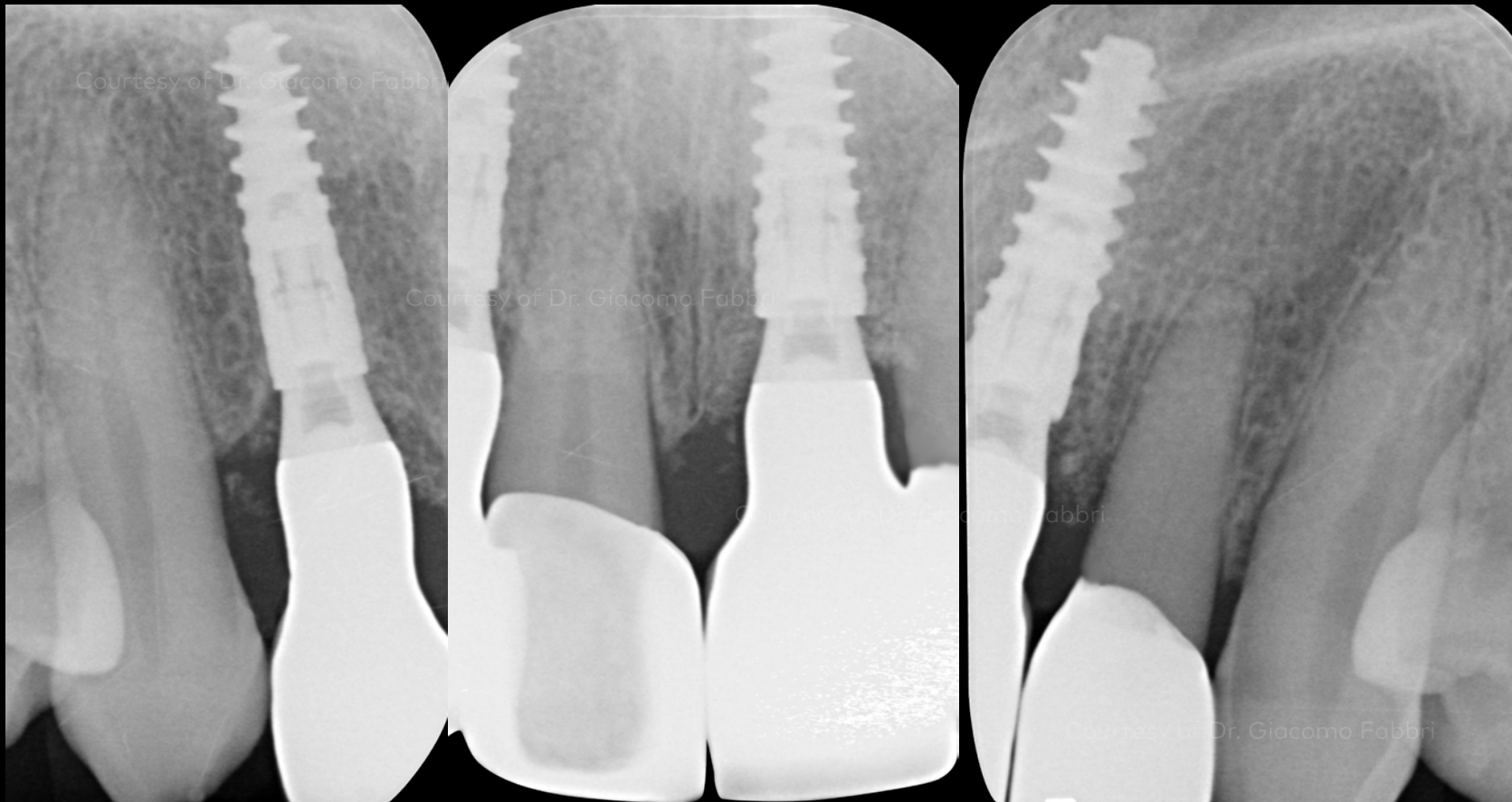
Treatment
planning

Surgical
procedure

Restorative
procedure

Outcome

Final restorations: 1 year after implant placement



X-ray evaluation:
X-rays show excellent integration of the restoration and an excellent bone stability.

Case courtesy of Dr. Giacomo Fabbri



GMT 80994 GB 2210 © Nobel Biocare Services AG, 2022. All rights reserved. Nobel Biocare, the Nobel Biocare logotype and all other trademarks are, if nothing else is stated or is evident from the context in a certain case, trademarks of Nobel Biocare. Please refer to nobelbiocare.com/trademarks for more information. Product images are not necessarily to scale. Disclaimer: Some products may not be regulatory cleared/released for sale in all markets. Please contact the local Nobel Biocare sales office for current product assortment and availability. For prescription use only. Caution: Federal (United States) law restricts this device to sale by or on the order of a licensed clinician, medical professional or physician. See Instructions For Use for full prescribing information, including indications, contraindications, warnings and precautions. Nobel Biocare does not take any liability for any injury or damage to any person or property arising from the use of this clinical case. This clinical case is not intended to recommend any measures, techniques, procedures or products, or give advice, and is not a substitute for medical training or your own clinical judgement as a healthcare professional. Viewers should never disregard professional medical advice or delay seeking medical treatment because of something they have seen in this clinical case. Full procedure is not shown. Certain sequences have been cut.