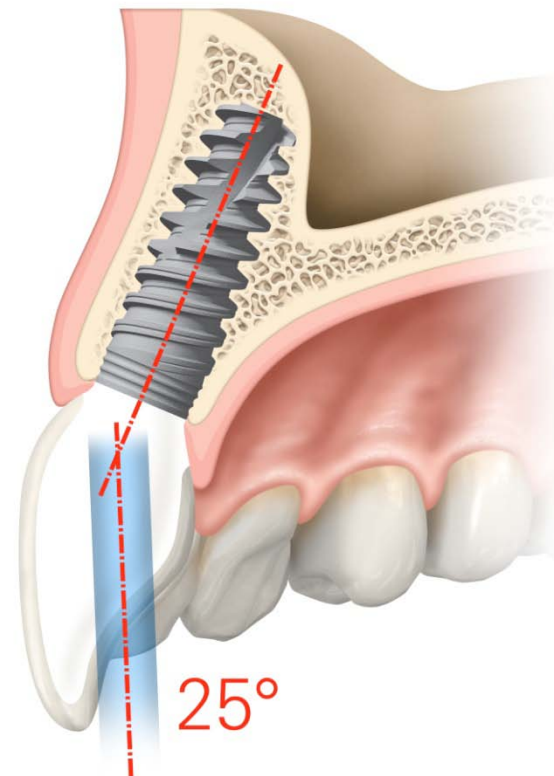


Clinical Case

NobelProcera ASC

May, 2014



NobelProcera® ASC Abutment



Dr. Marwan Daas

Associate Professor- Paris V,
PhD in Biomechanics
Private practice in Paris
France



Dr. Karim Dada

DDS
Former resident of University Paris V
Private practice in Perio & Implant, Paris
France



M. Jean Marc Etienne, Oral Design
CDT, Master Ceramist
France

Anterior restorations

Female patient
29 years old

Implant:

Replace Conical Connection 3.5
x13mm

Restoration:

NobelProcera ASC Abutment
veneered with porcelain

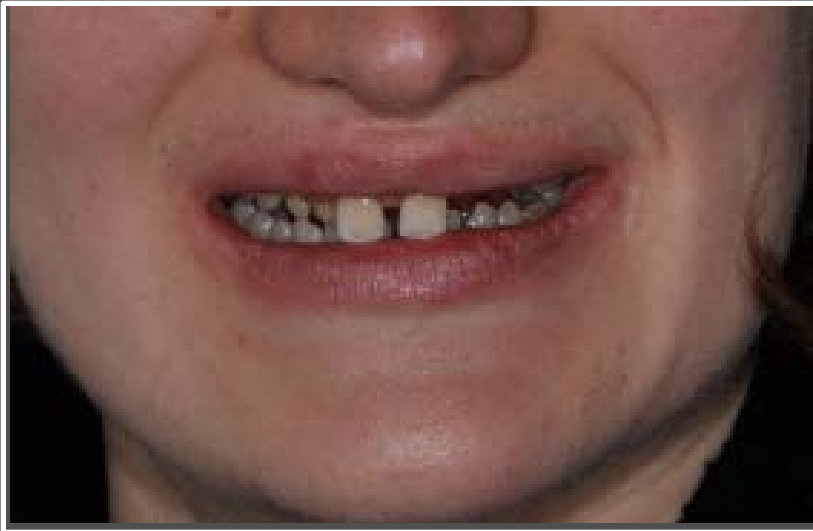Total treatment time:

24 months

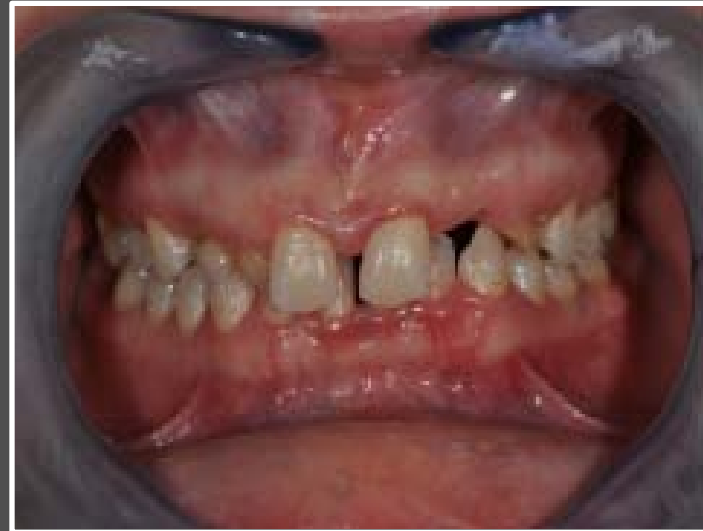“The ability to implement CAD/CAM screw-retained zirconia restorations in more cases represents a real treatment evolution!”

NobelProcera[®] ASC Abutment

Initial clinical situation



Courtesy of Dr. Daas, Dr. Dada and M.Etienne

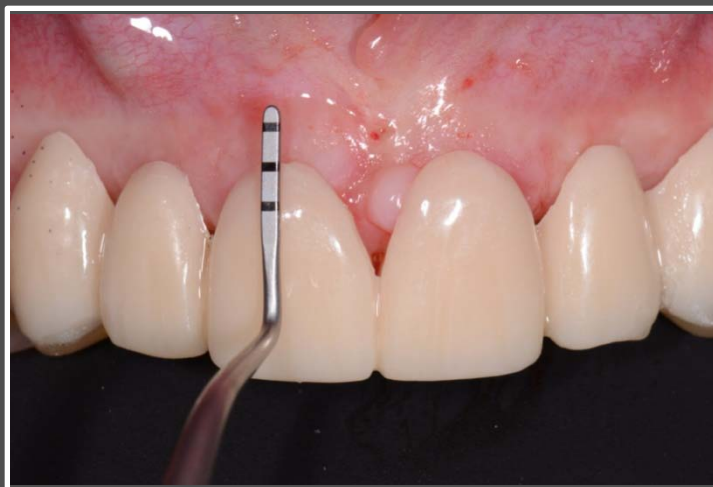

Courtesy of Dr. Daas, Dr. Dada and M.Etienne

A young female patient presenting ectodermal dysplasia X-linked with multiple congenitally absent teeth leading to typical occlusal disorders. These agenesis are associated with severe alveolar bone atrophy.

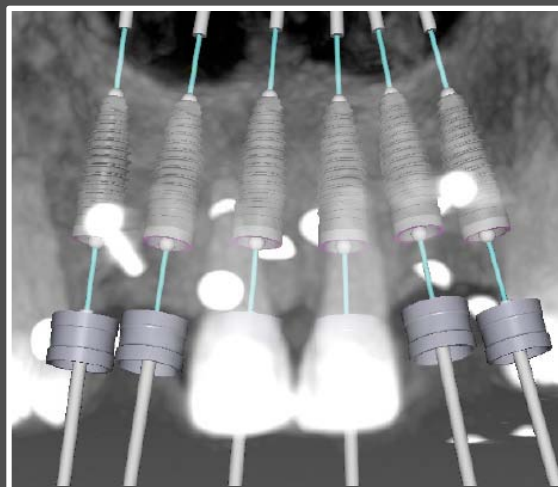
NobelProcera[®] ASC Abutment

Initial clinical situation



Courtesy of Dr. Daas, Dr. Dada and M.Etienne

A mock-up of the future clinical objective is set up, validated and used as a guidance for the required soft tissue management: a crown lengthening procedure is planned to move tissue apically by 8 mm.

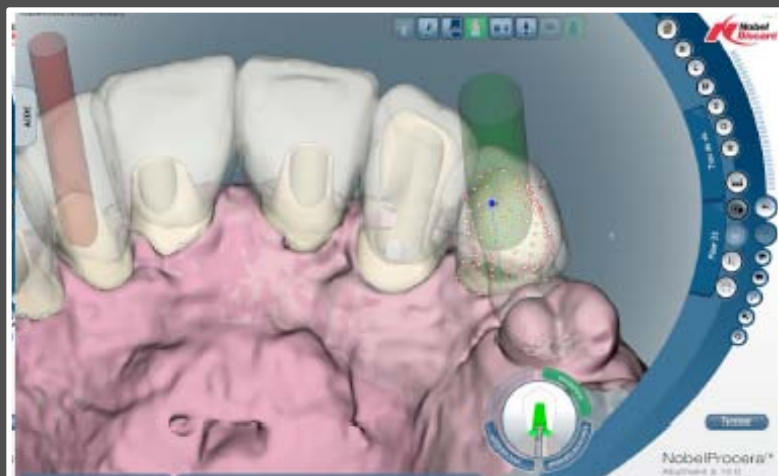


Courtesy of Dr. Daas, Dr. Dada and M.Etienne

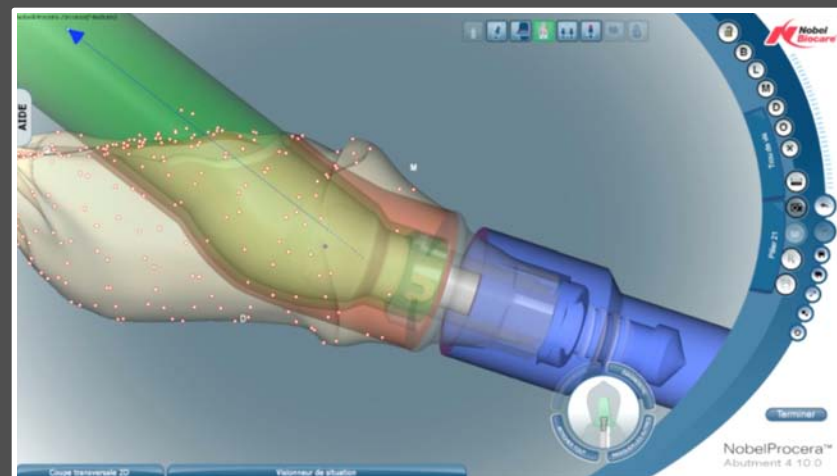
Successfully with the use of NobelClinician software and guided surgery this challenging cases, where bone was limited, six NobelReplace NP implants were planned and ideally placed.

NobelProcera[®] ASC Abutment

Digital design of final restoration



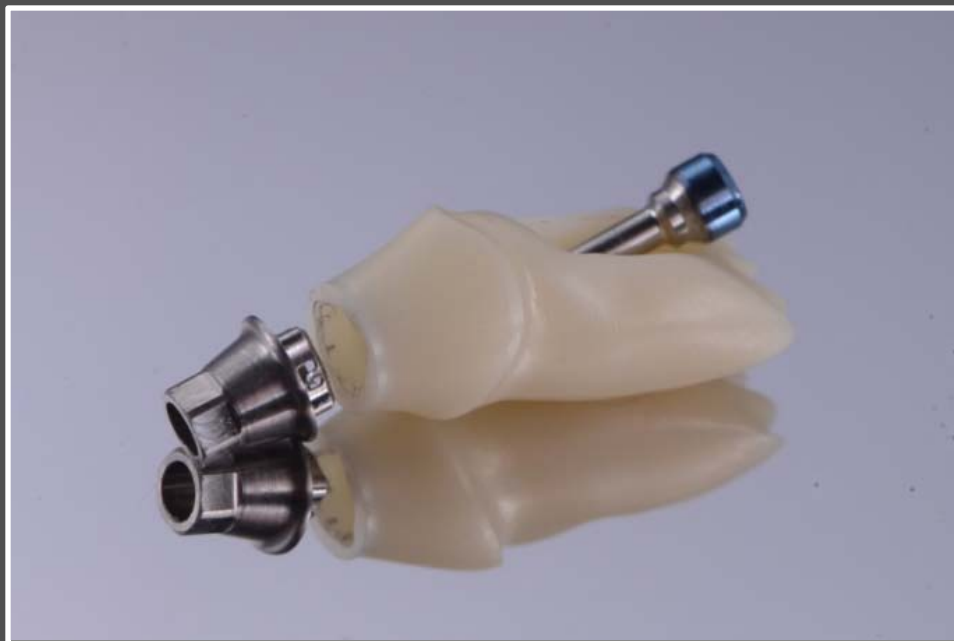The prosthetic success of this challenging clinical case was achieved due to the new restorative flexibility which the NobelProcera ASC abutment brings - enabling a labially positioned screw access hole to be rotated and placed palatally. And confidently, due to the intelligence of the NobelProcera CAD software the required material thickness of the abutment is dynamically ensured.



Close view of the virtual screw access channel and visualization of the ASC tool in order to optimize the prosthetic outcome.

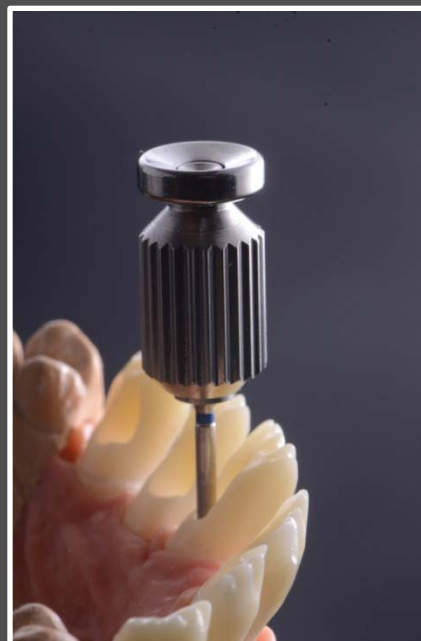NobelProcera® ASC Abutment

Final restorations



Courtesy of Dr. Daas, Dr. Dada and M.Etienne

The NobelProcera ASC concept is completely cement free, due to an intelligently designed mechanically retained adapter.

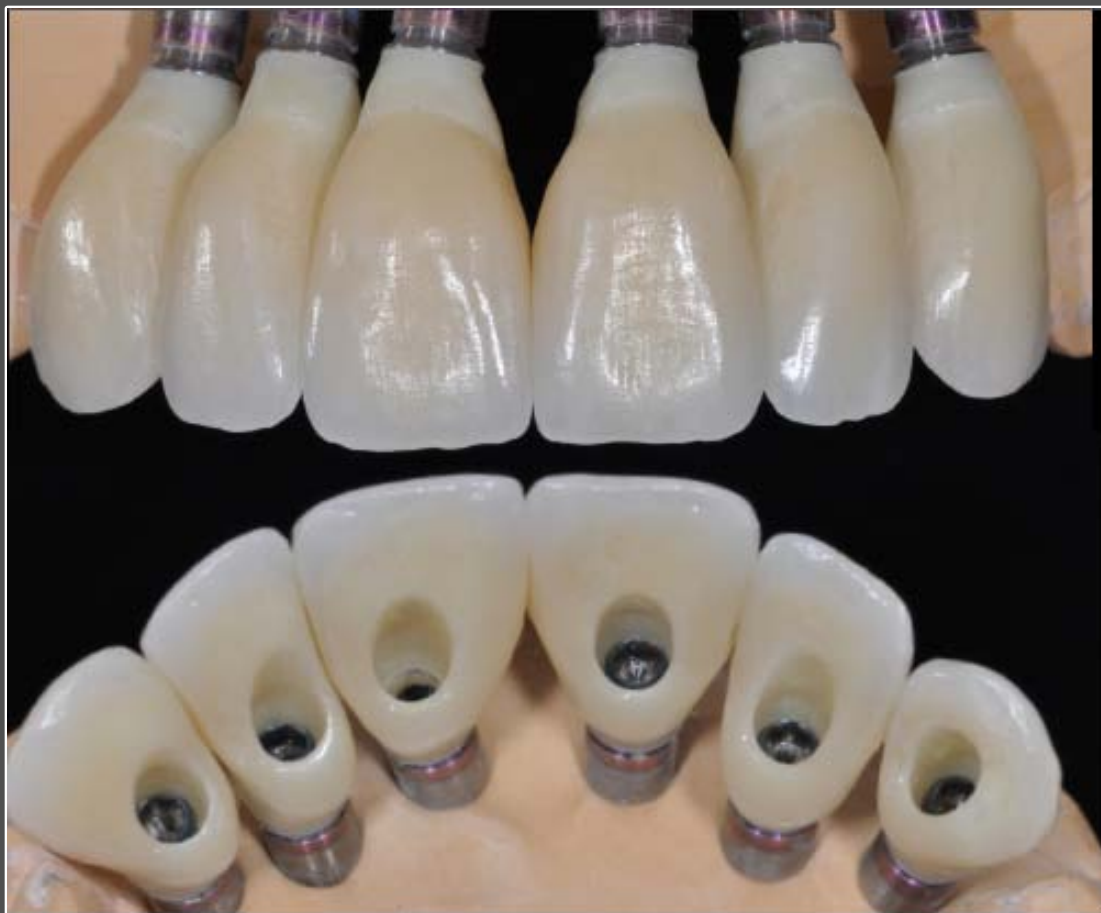

Courtesy of Dr. Daas, Dr. Dada and M.Etienne

The true restorative flexibility of ASC abutment can be seen in this image - as the Omnigrip screw drivers seats in the restoration and the screw channel axis tilts palatally.

NobelProcera[®] ASC Abutment

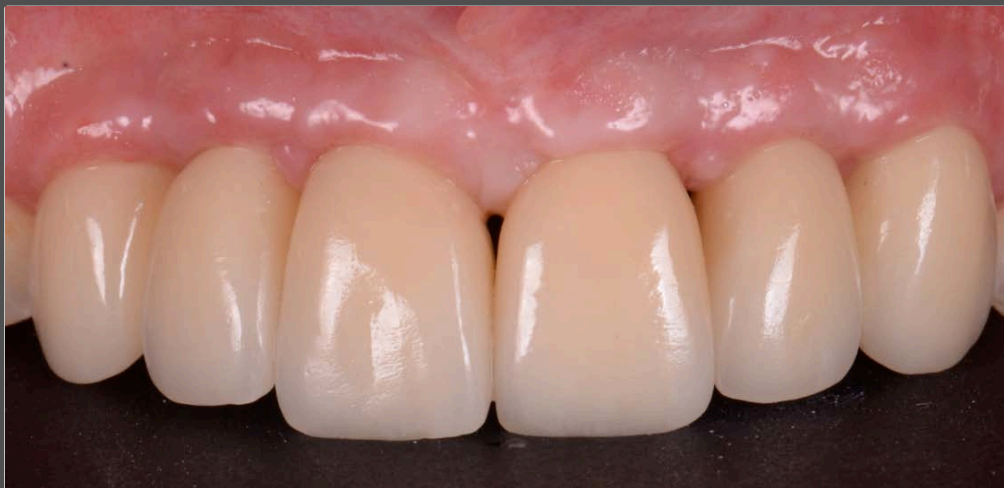Final restorations



Labial and occlusal view of the six finalized NobelProcera ASC Conical Connection Abutments.

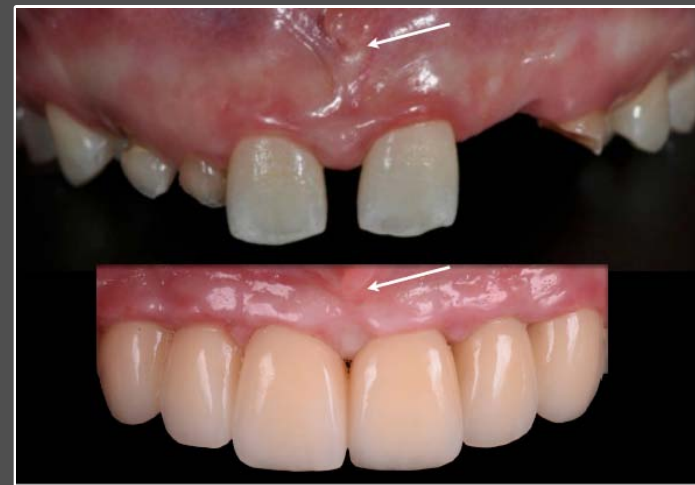NobelProcera[®] ASC Abutment

Final outcome



Courtesy of Dr. Daas, Dr. Dada and M.Etienne

Two days after placement, esthetic and biological integration of the all-ceramic screw-retained restorations.

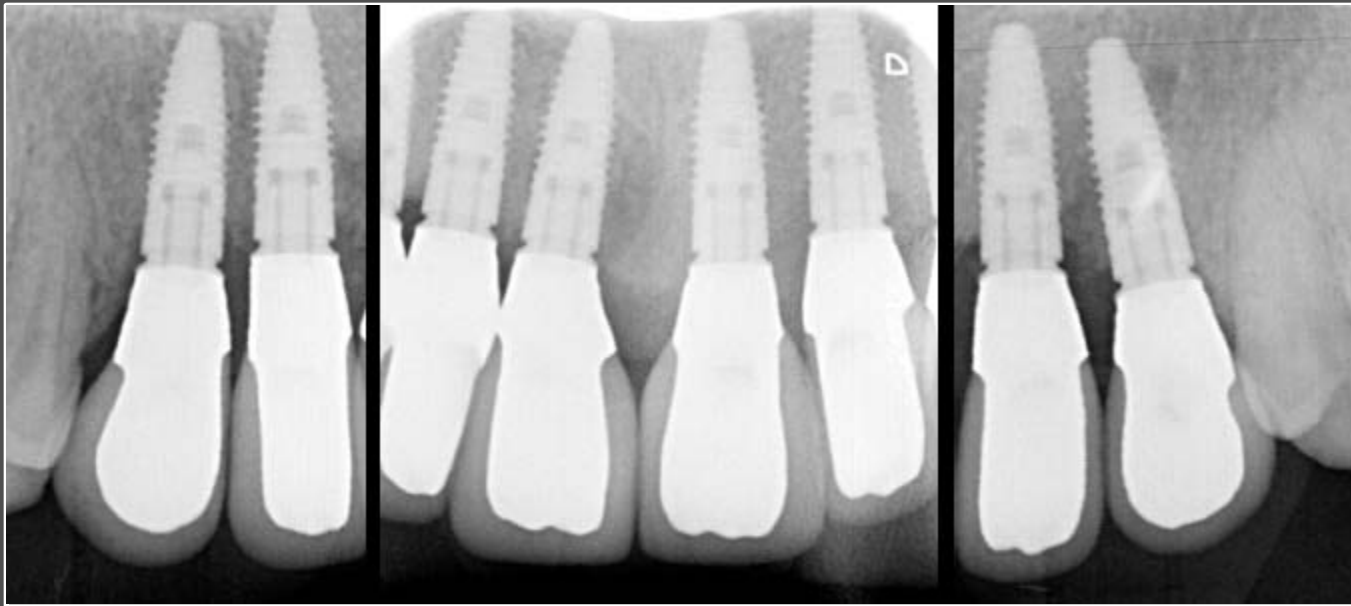


Courtesy of Dr. Daas, Dr. Dada and M.Etienne

Clinical view before and after treatment illustrating the important transformation that have been planned and achieved.

NobelProcera[®] ASC Abutment

Final outcome

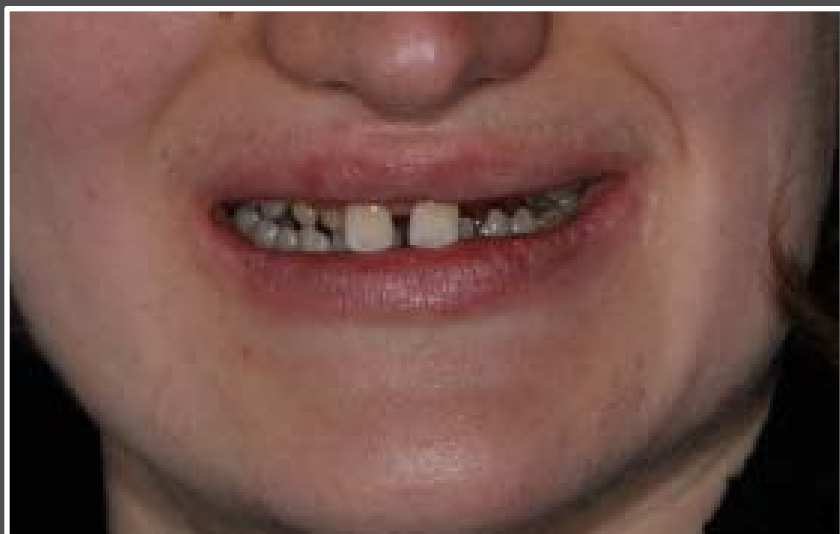

Courtesy of Dr. Daas, Dr. Dada and M.Etienne

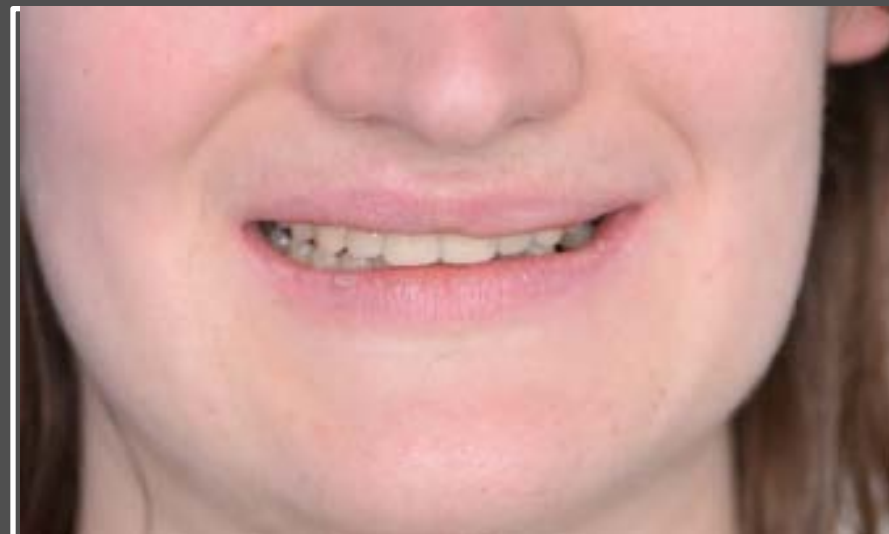On the day of ASC restoration placement, post-operative X-rays show the excellent fit of these screw-retained restorations and the optimal emergence profiles in this complex situation in relation to implant distribution.

NobelProcera® ASC Abutment

Final situation



Courtesy of Dr. Daas, Dr. Dada and M.Etienne



Courtesy of Dr. Daas, Dr. Dada and M.Etienne

Final view showing the major changes in clinical and esthetic aspects after treatment.