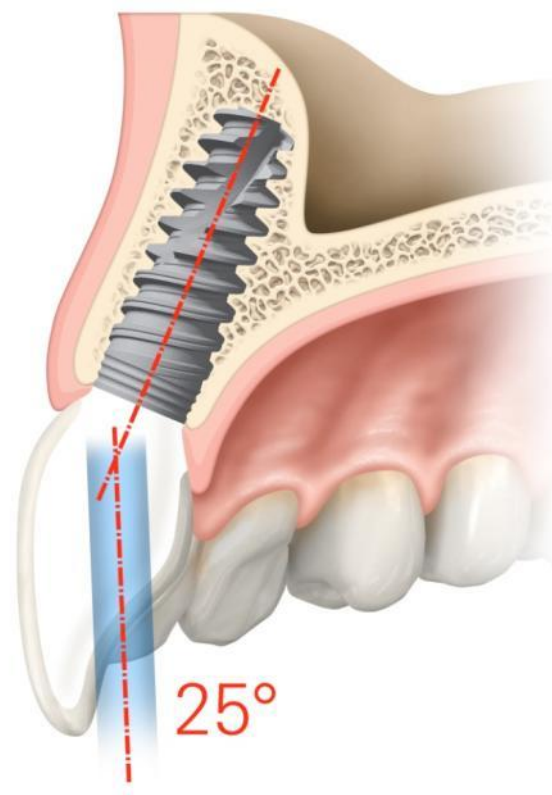


Clinical case

NobelProcera[®] ASC

May, 2014



NobelProcera® ASC Abutment



Dr. Juan Zufía DDS
Spain



Sr. Santiago Dalmau
Dental technician
Spain

Anterior restoration

Female patient, 29 years old

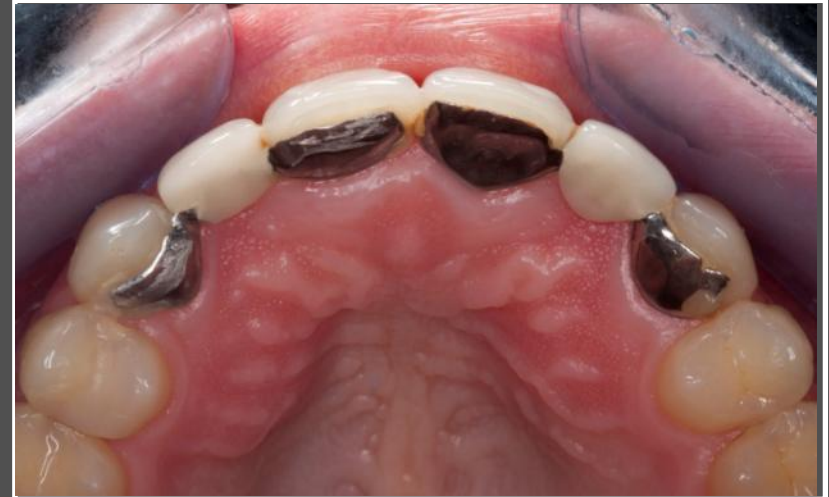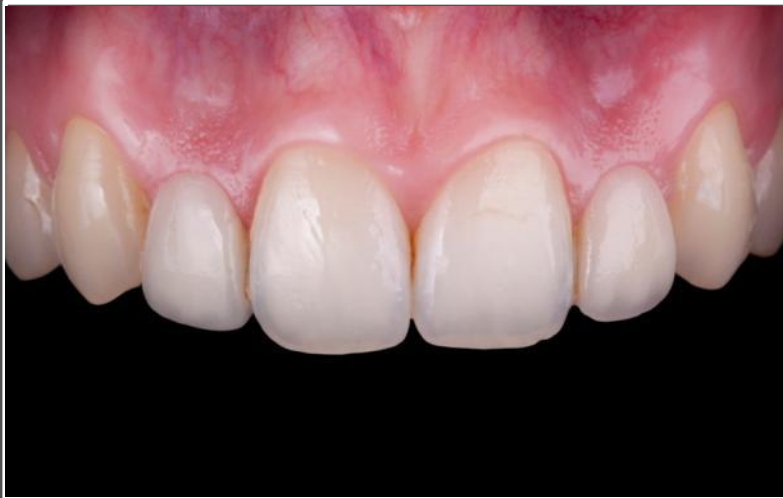Implant:

NobelActive NP 13mm

Restoration:

Two NobelProcera ASC Abutments directly veneered (screw-retained crowns).

NobelProcera[®] ASC Abutment

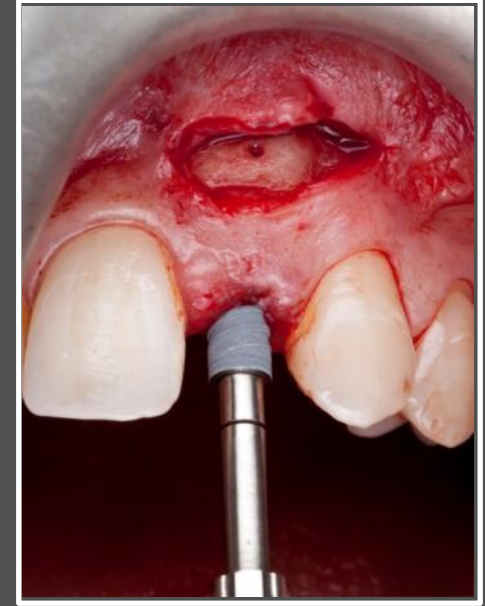
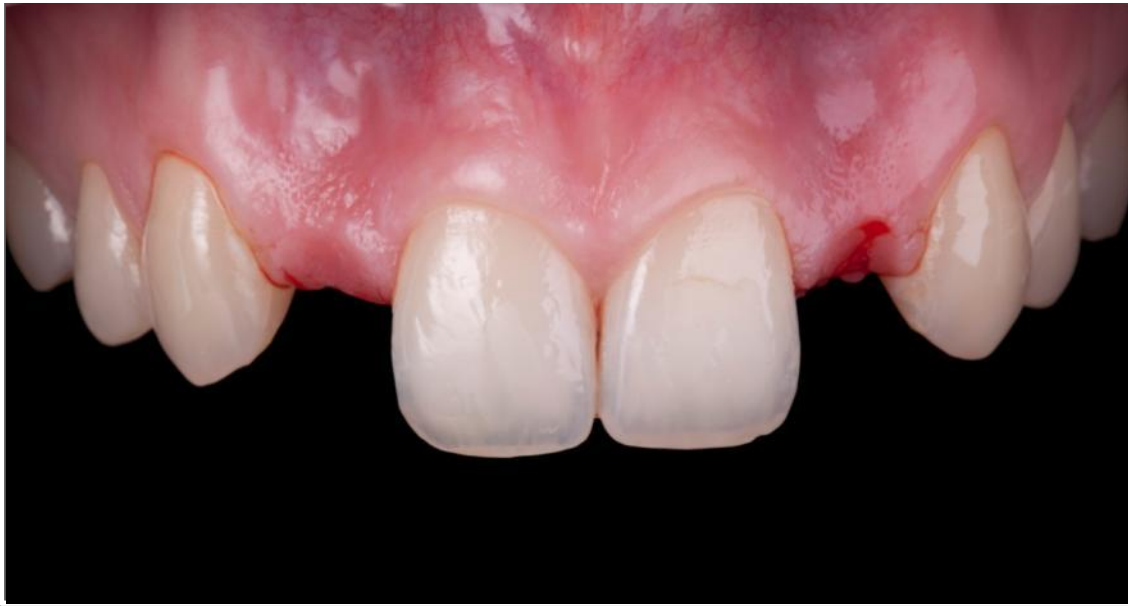

Initial situation, diagnosis

Agenesis of both lateral superior incisors. Maryland porcelain bridges with continuous descementations. The patient has a thin biotype with long papillae, as well as good oral health and hygiene.

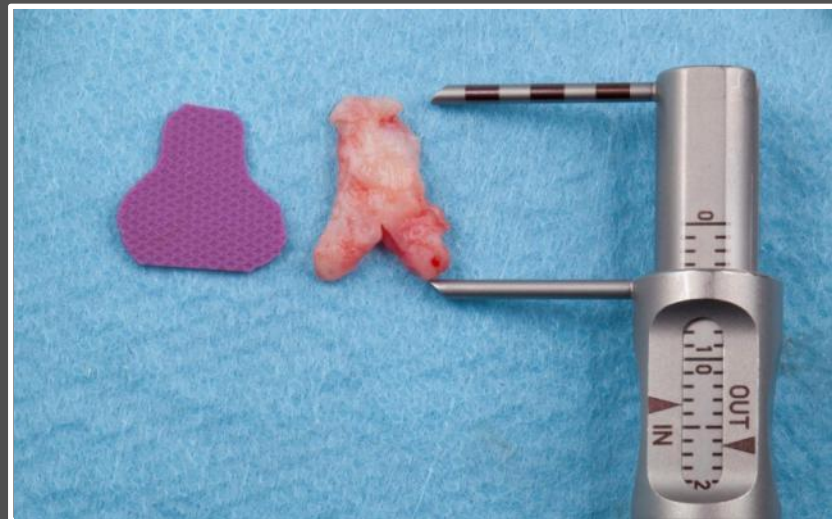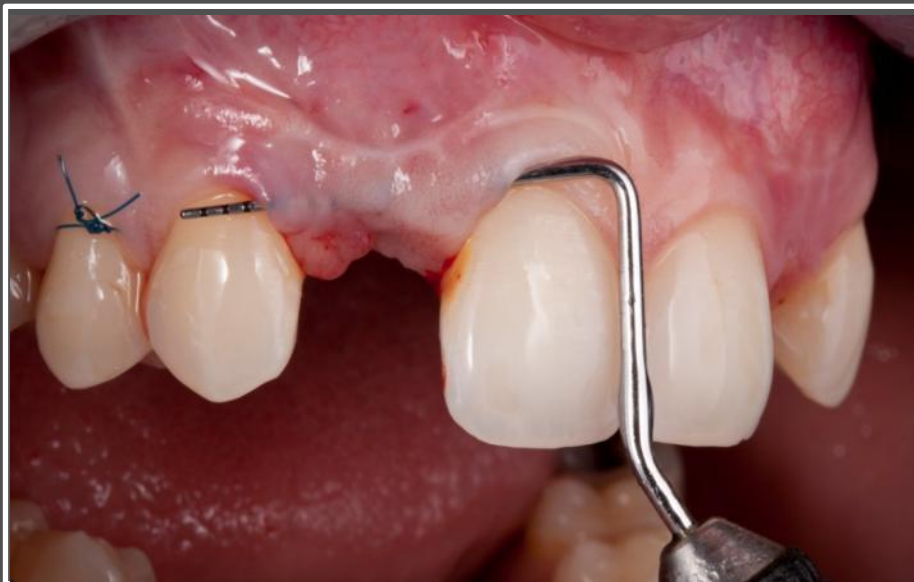2-3 mm of bone width in both areas of the ridge. There is not enough bone to place implants and there are sunken areas in the gingiva.

NobelProcera® ASC Abutment



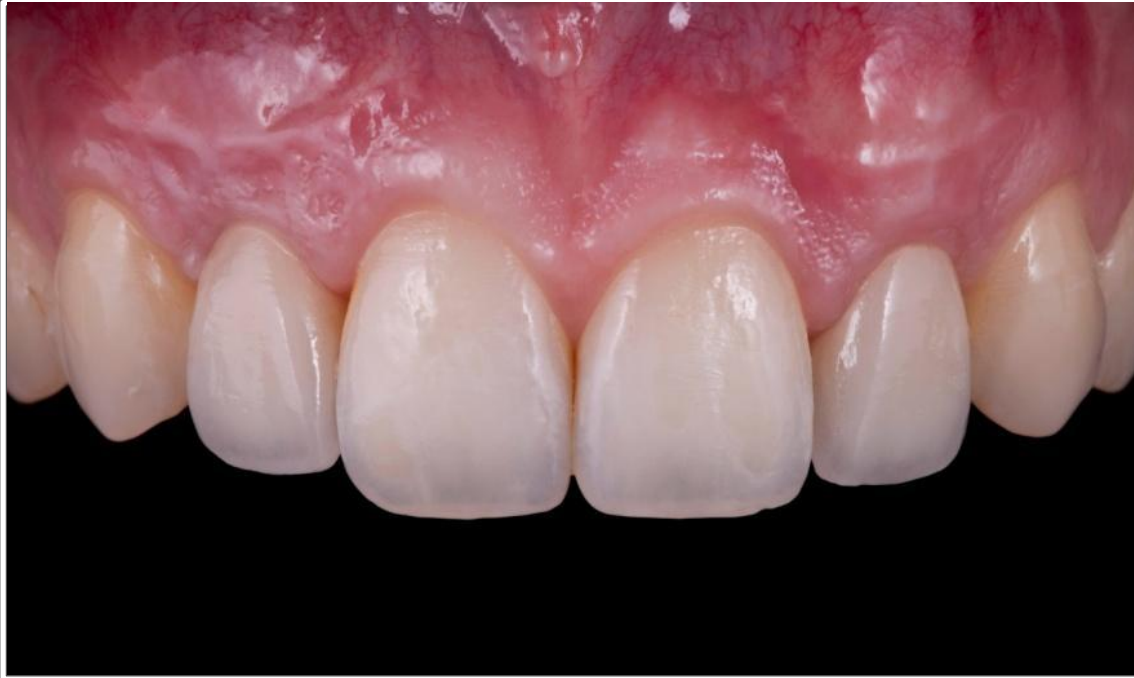Removal of the Maryland Bridge (left image). A connective tissue graft was performed to change the biotype from thin to thick . This was followed by three months of healing. Then a guided bone regeneration with two blocks from the mandible ramus was completed, followed by eight months of healing. Two NobelActive NP implants were placed (right image).

NobelProcera® ASC Abutment



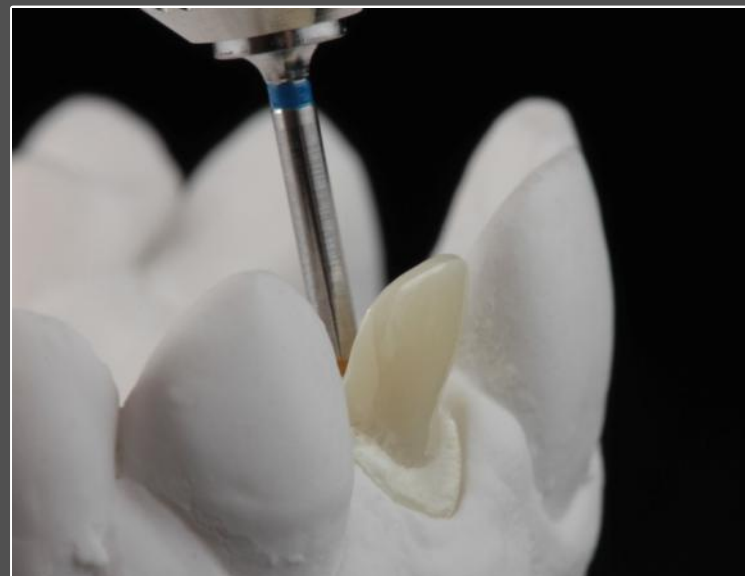
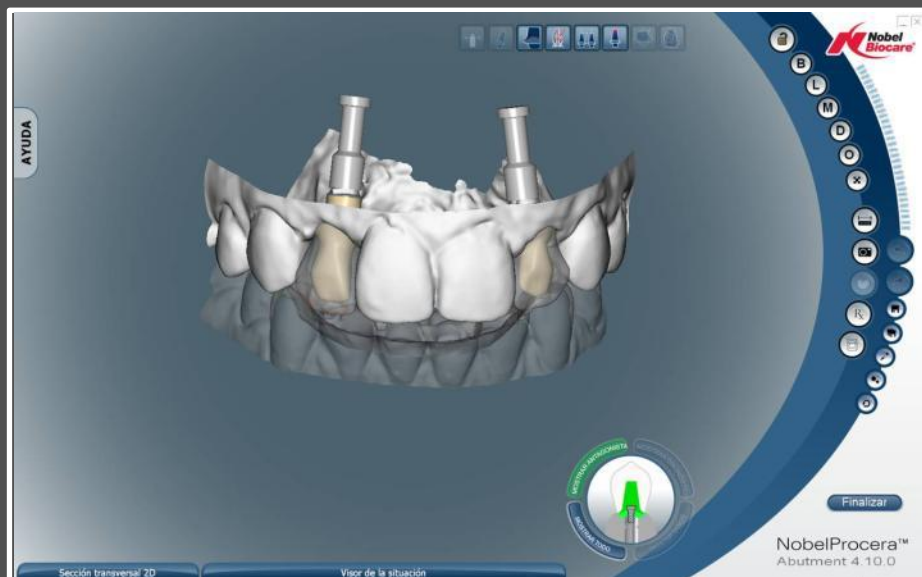A second connective tissue graft was performed to improve the height of the soft tissue.

NobelProcera[®] ASC Abutment



Fixed provisional restorations were placed to shape the emergence profile.

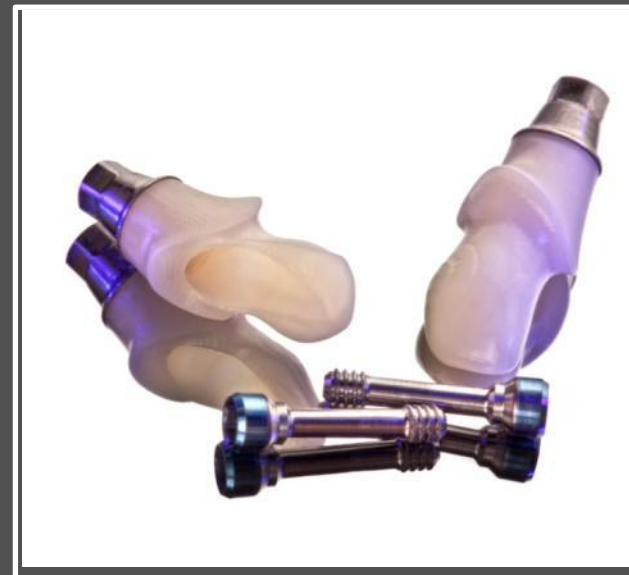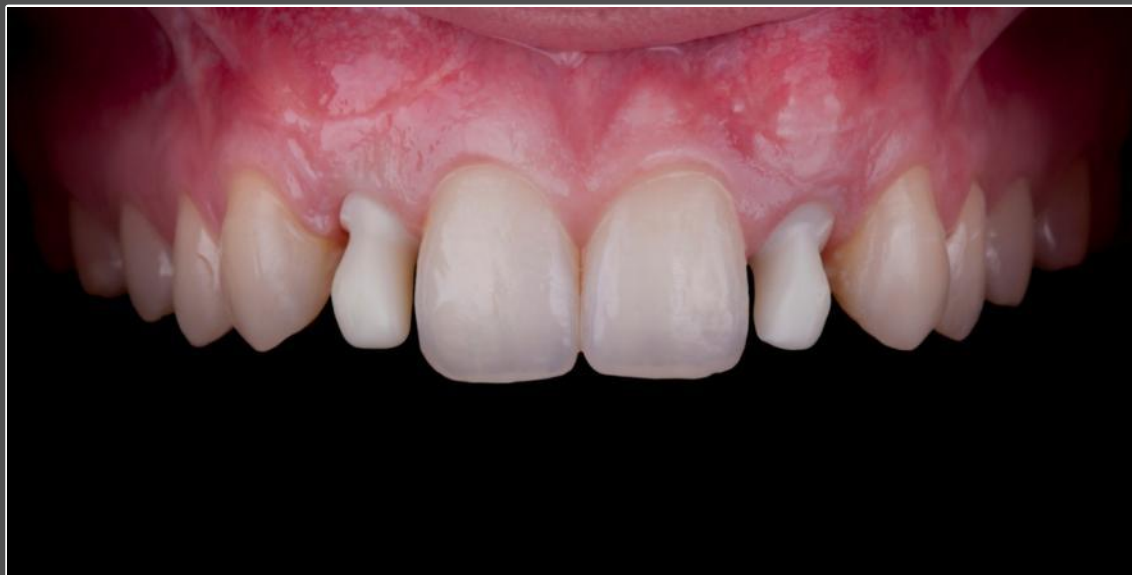NobelProcera[®] ASC Abutment



Final CAD/CAM restorations

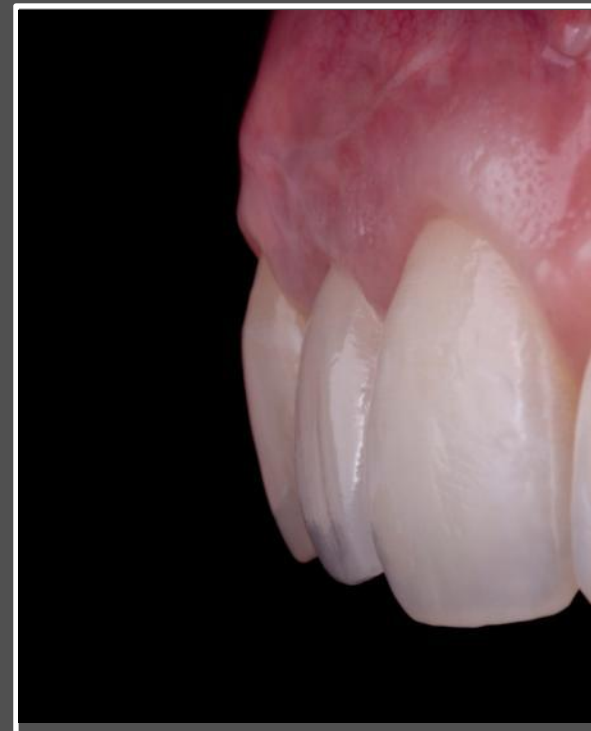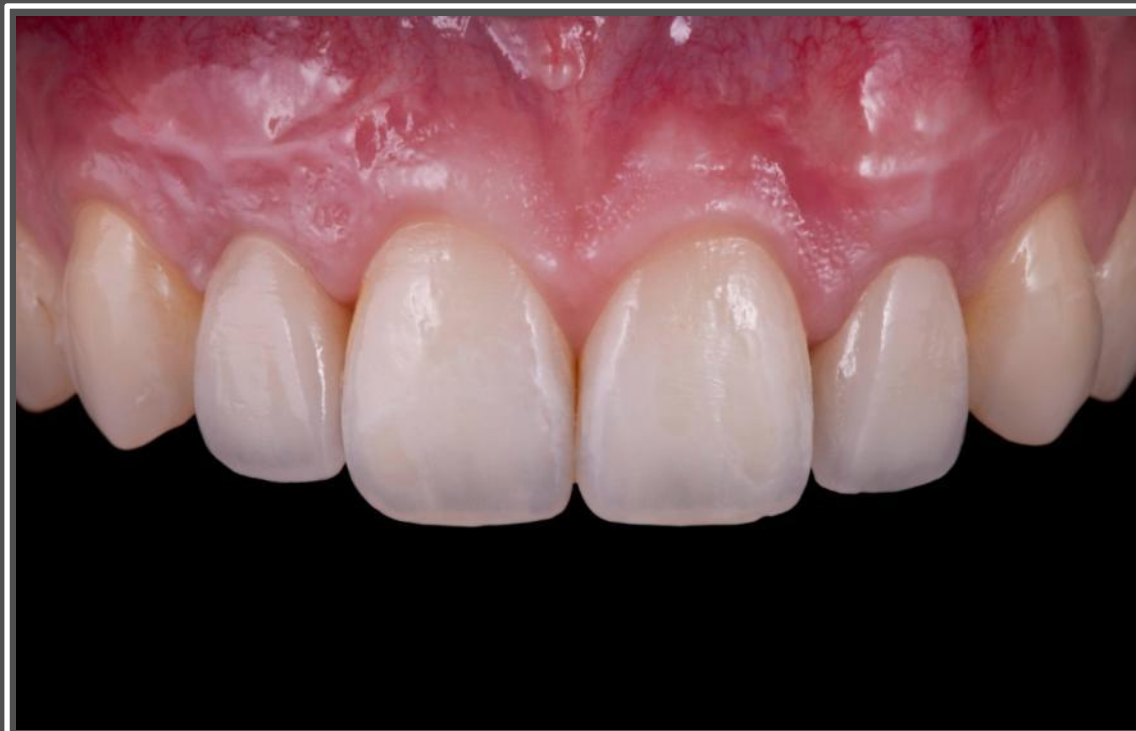Abutments were designed from a diagnostic tooth set-up to create the ideal anatomical shape for optimal veneering. The new restorative flexibility which the NobelProcera ASC abutment enables a labially positioned screw access hole to be rotated and placed palatally to improve esthetics.

NobelProcera® ASC Abutment



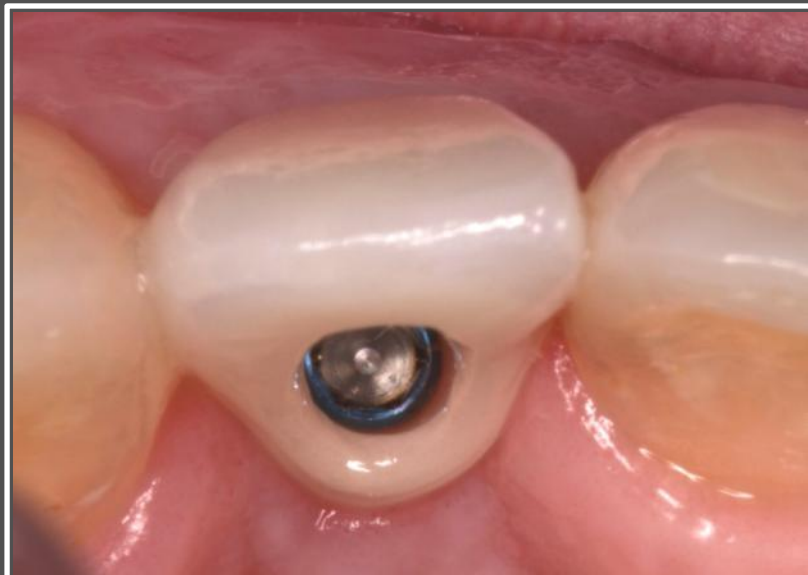Try-in of the two NobelProcera ASC Abutments. The new Omingrip Screwdriver with pick-up function securely holds the screw.

NobelProcera[®] ASC Abutment



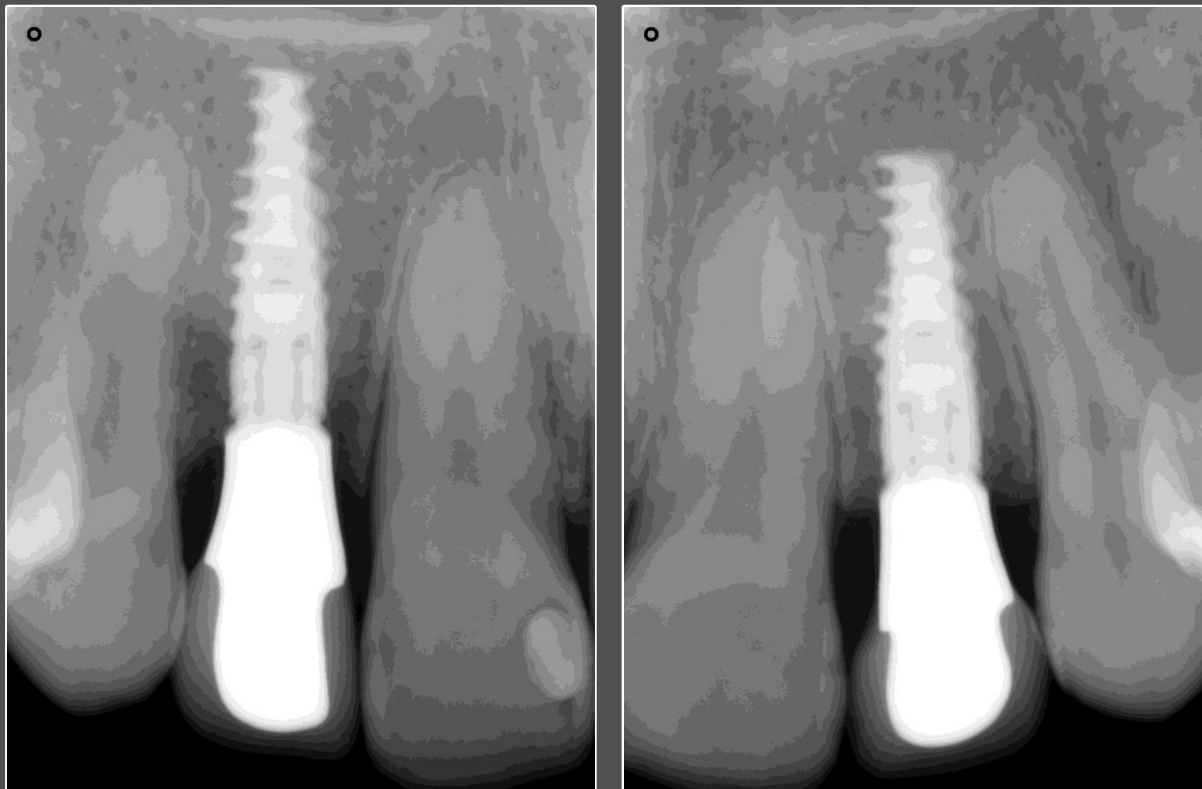
Final outcome facial and lateral view

NobelProcera® ASC Abutment



Final outcome occlusal view and patient smile.

NobelProcera® ASC Abutment



On the day of ASC restoration placement, post-operative X-rays show the excellent fit of these screw-retained restorations

Case courtesy of Dr. Juan Zufia and Sr. Santiago Dalmau

GMT 35252 Nobel Biocare, the Nobel Biocare logotype and all other trademarks used in the this document are, if nothing else is stated or is evident from the context in certain case, trademarks of Nobel Biocare. Product images are not necessarily to scale.

Disclaimer: Some products may not be regulatory cleared/released for sale in all markets.