

Ridge augmentation



Dan Holtzclaw, DDS, MS.
Austin, Texas, USA

“The use of blended bone allograft containing a 70:30 ratio of mineralized to demineralized cortical bone particulate can be successfully utilized to facilitate the placement of dental implants with as little as 12 to 14 weeks of healing”

Patient information:

42-year-old female, medical history unremarkable, no history of tobacco use and only social consumption of alcohol, complaint of inability to adequately chew food due to missing teeth in the posterior right mandible

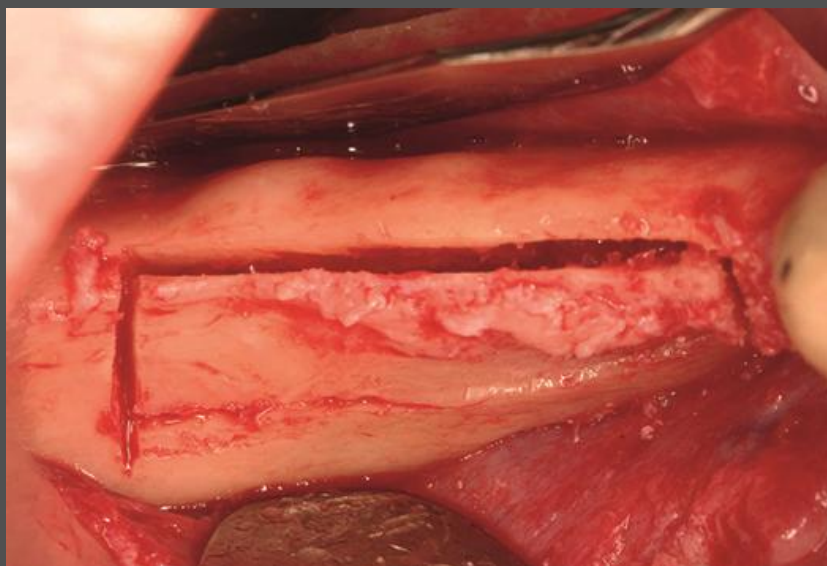
Indication:

No site preservation of the mandibular right second premolar, first molar, and second molar after extraction. Bone regeneration prior to implant placement is needed.

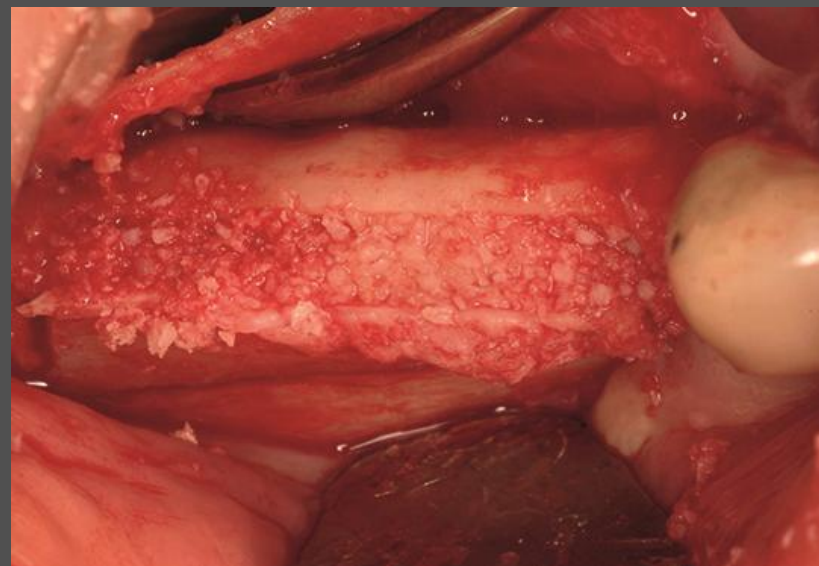
Solution:

Piezoelectric ridge splitting procedure followed by bone grafting with creos allo.gain 70/30 mineralized/ demineralized bone particulate, and covered with a barrier membrane. After 3 months of healing, two NobelSpeedy Replace implants are placed.

Ridge augmentation

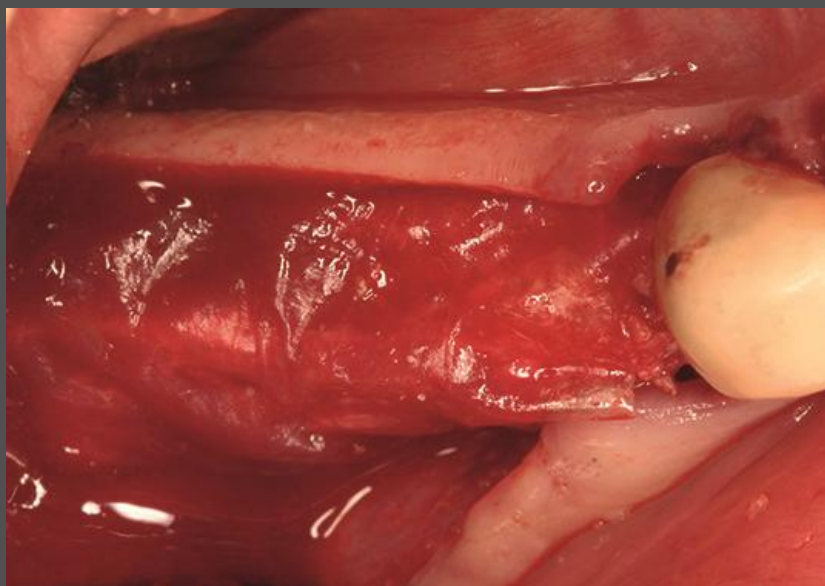


Piezoelectric corticotomies to facilitate mandibular ridge splitting procedure.

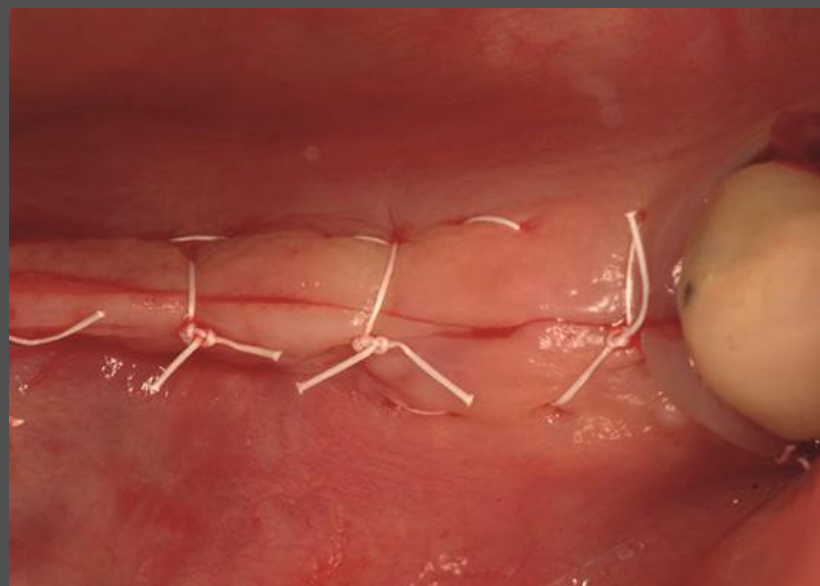


Placement of creos allo.gain 70/30 mineralized/ demineralized bone particulate into split ridge.

Ridge augmentation

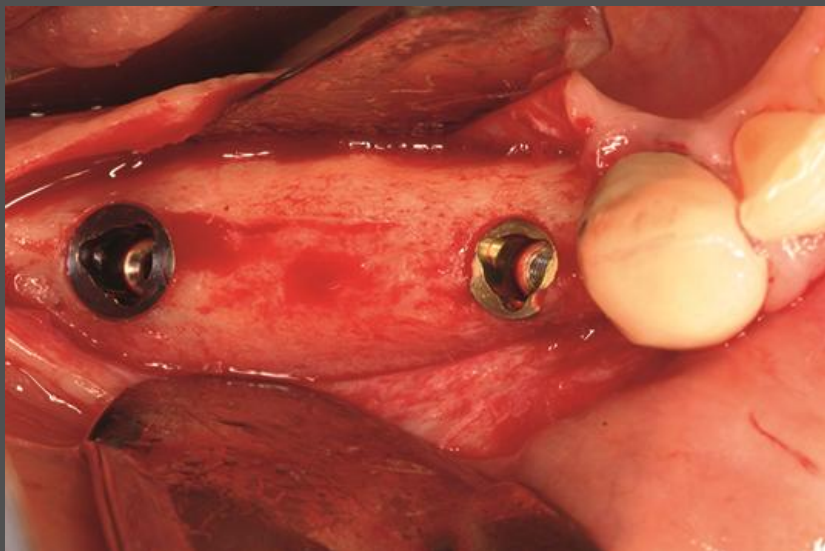


Placement of barrier membrane for guided bone regeneration (GBR).

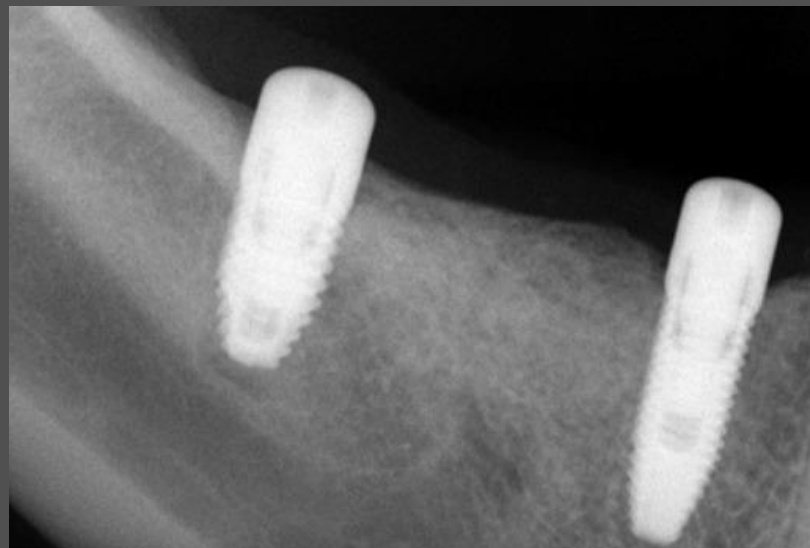

Primary closure achieved at surgical site with aid of periosteal releasing incision.

Ridge augmentation



After 3 months of healing, approx. 4mm of improved horizontal bone width was achieved to facilitate implant placement.



Radiographic record of implant placement following healed ridge split procedure.