

Clinical case NobelActive[®]

October 2013





Dr. Louwrens C. Swart
Maxillofacial and oral surgeon
Cape Town, South Africa



Premolar restoration

Female patient
39 years old
Asthma history

Implant:

NobelActive RP 4.3 x 13 mm

Surgery date:

August 28, 2008

Time for total treatment:

3 months

Flapless implant placement

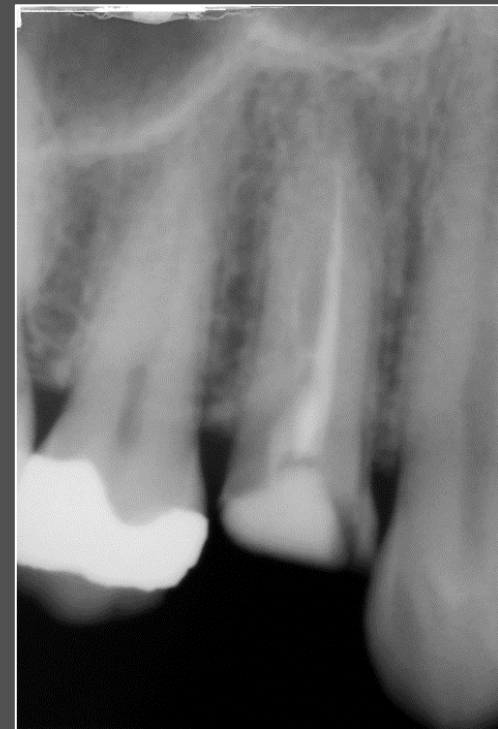
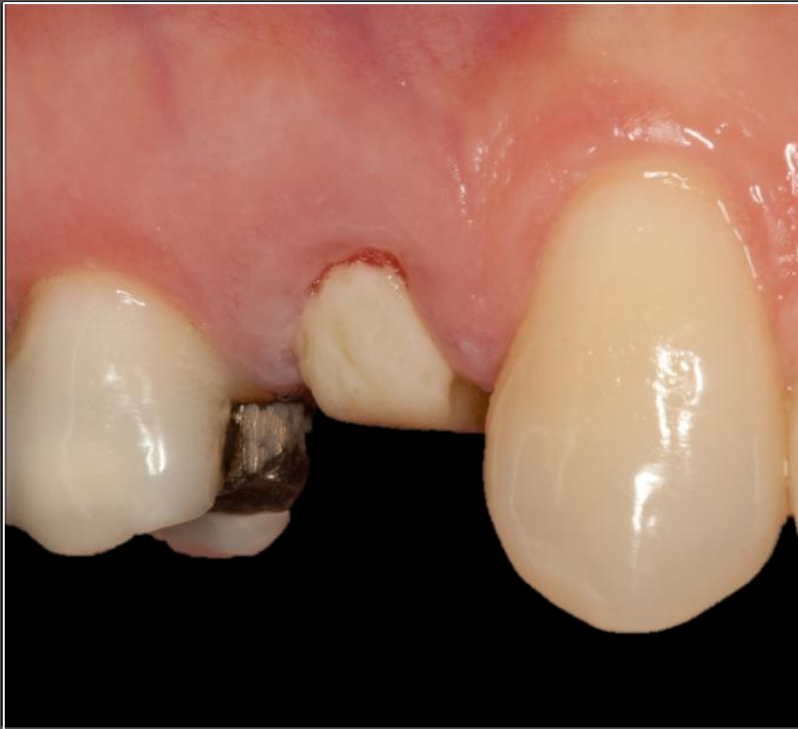Immediate loading of extraction site

FDI POS: tooth 14

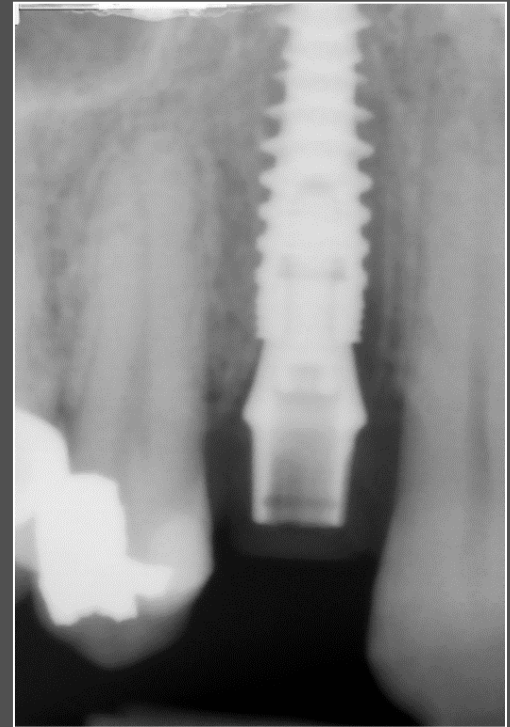
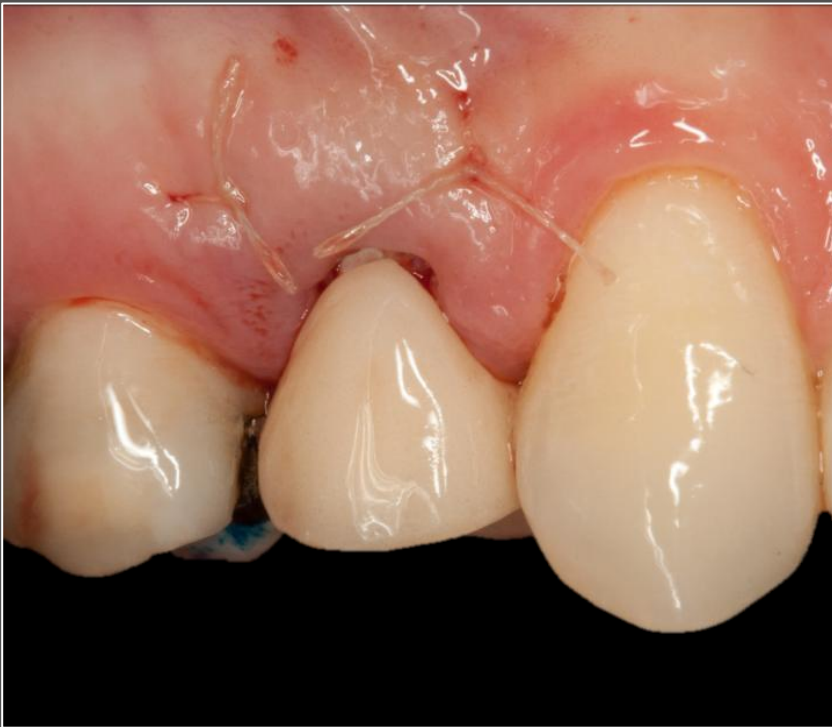Dental technician:

Ian Robertson
South Africa

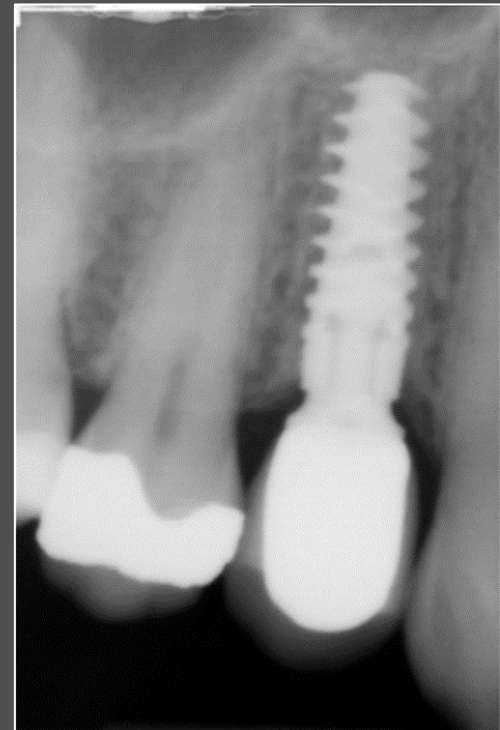
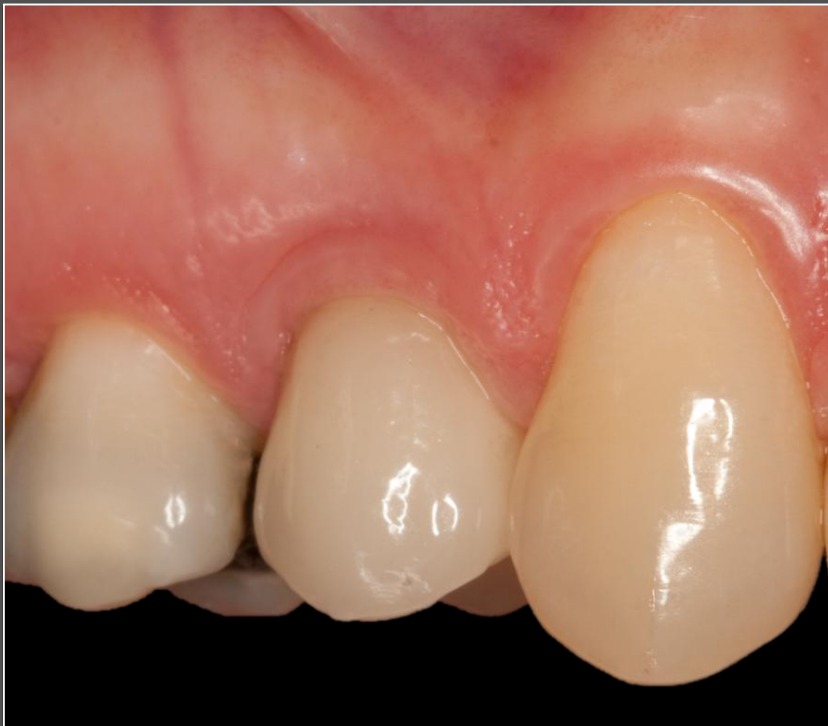Initial clinical situation



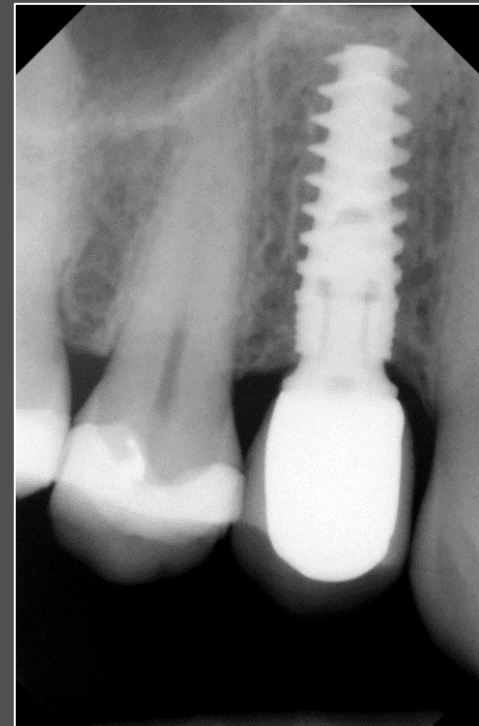
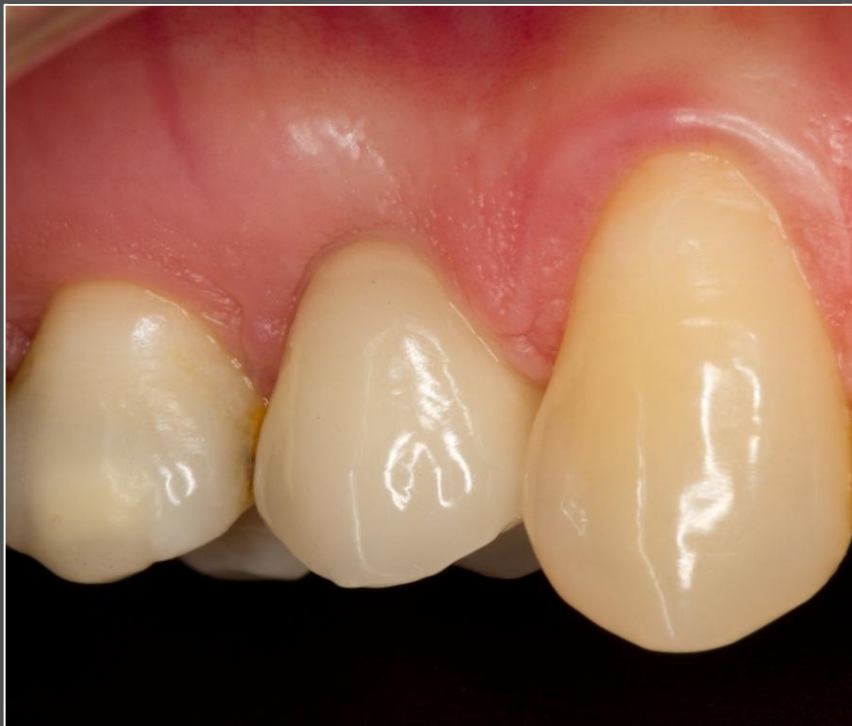Implant placement with provisional crown



Follow-up after 3 months



Follow-up after 3 years



Follow-up after 5 years

