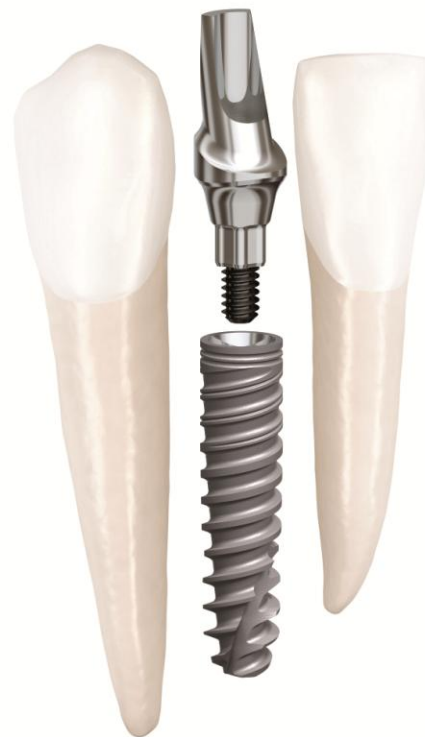

Clinical Case

NobelActive® 3.0

January, 2012




NobelActive[®] 3.0



Dr. Philip Russe

France



Upper lateral incisor restoration

Female patient

21 years old

Implant:

NobelActive 3.0 3.0 x 13mm

Surgery date:

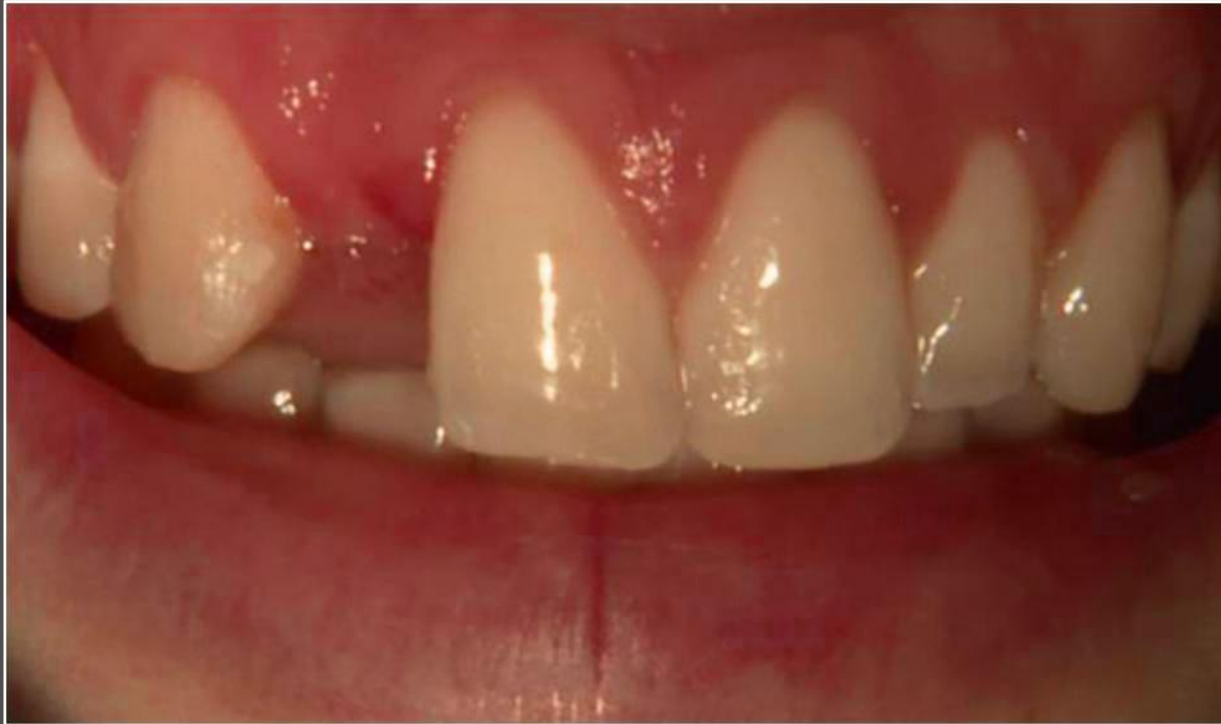March 11th, 2011

Flap without augmentation

FDI POS:

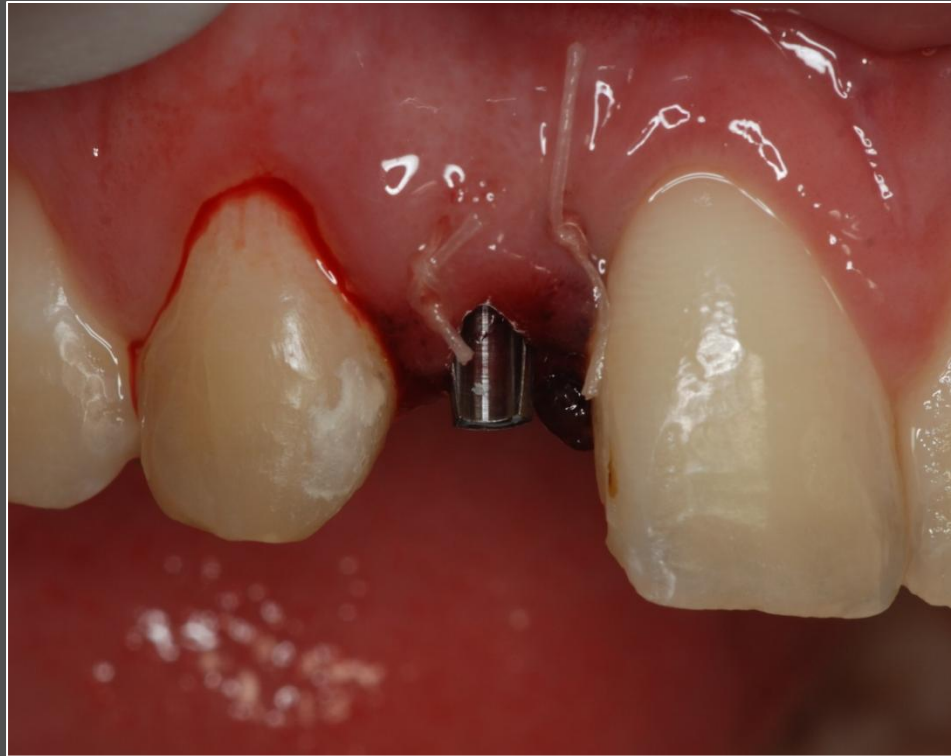Tooth 12

NobelActive[®] 3.0



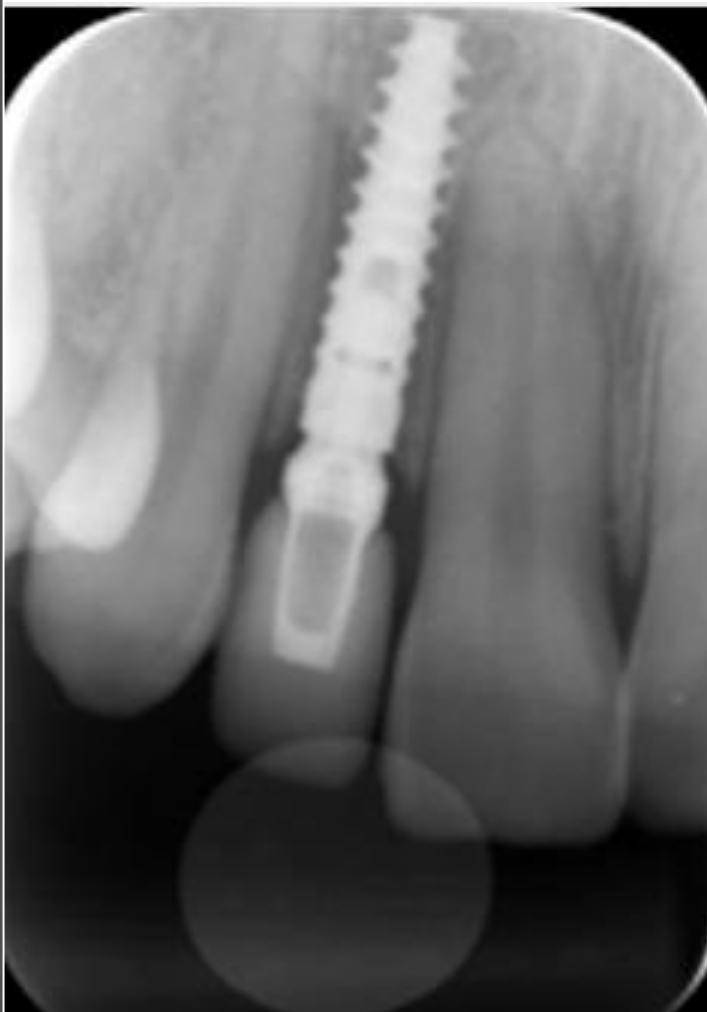Initial clinical situation:
Missing upper lateral incisor

NobelActive[®] 3.0



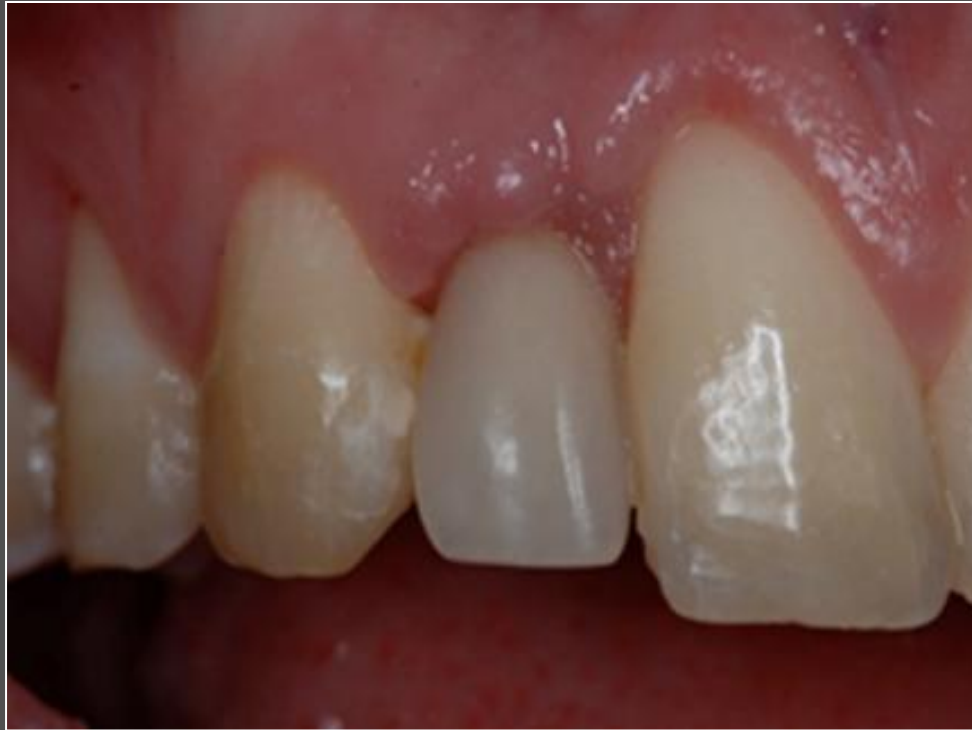Definitive abutment (15° Esthetic Abutment) placed at time of implant placement.

NobelActive[®] 3.0



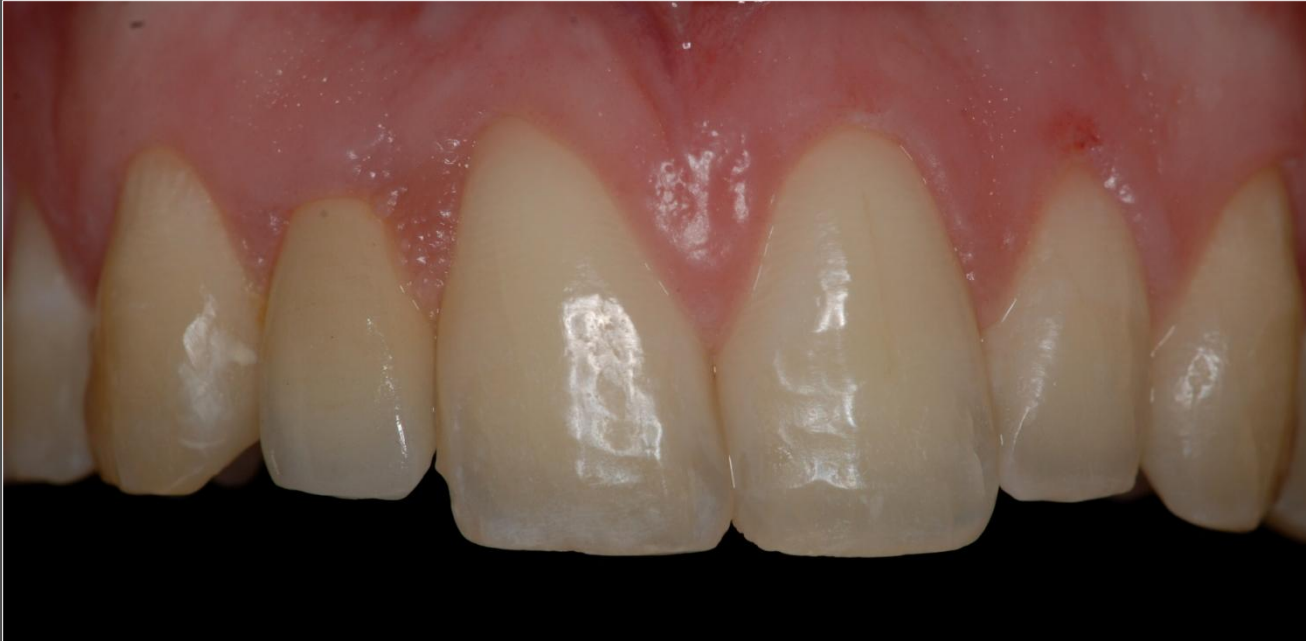Radiograph: Implant insertion

NobelActive[®] 3.0



Temporary restoration after healing period.

NobelActive[®] 3.0



Definitive restoration in place.