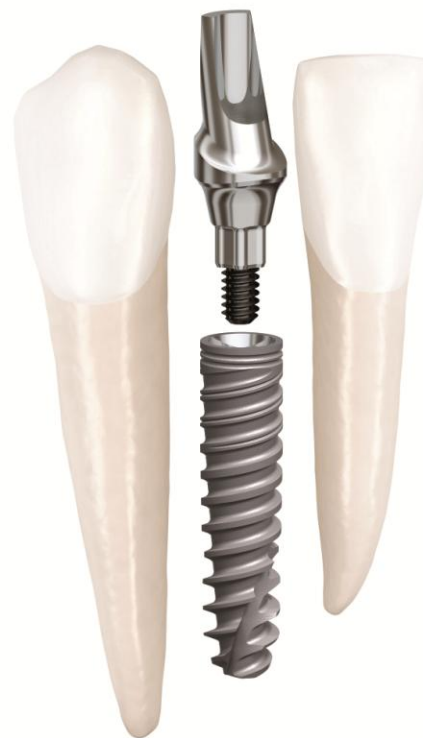

Clinical Case

NobelActive® 3.0

January, 2012




NobelActive® 3.0



Dr. Iñaki Gamborena

Spain



Narrow space restoration

Female patient
22 years old

Implant:

NobelActive 3.0 3.0x13mm

Flap with augmentation

FDI POS:

Teeth 31, 41

Dental Lab:

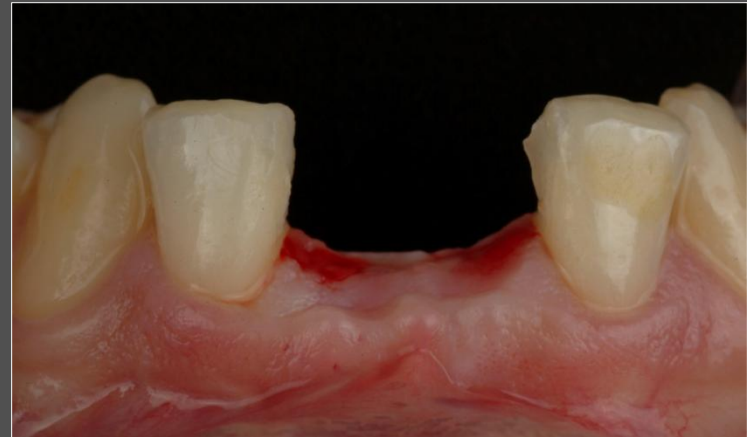Iñigo Casares

NobelActive® 3.0



„The narrow profile of NobelActive 3.0 maintains the high initial stability and strength associated with the original NobelActive, making it an implant I trust for treating narrow space cases.“

Dr. Iñaki Gamborena

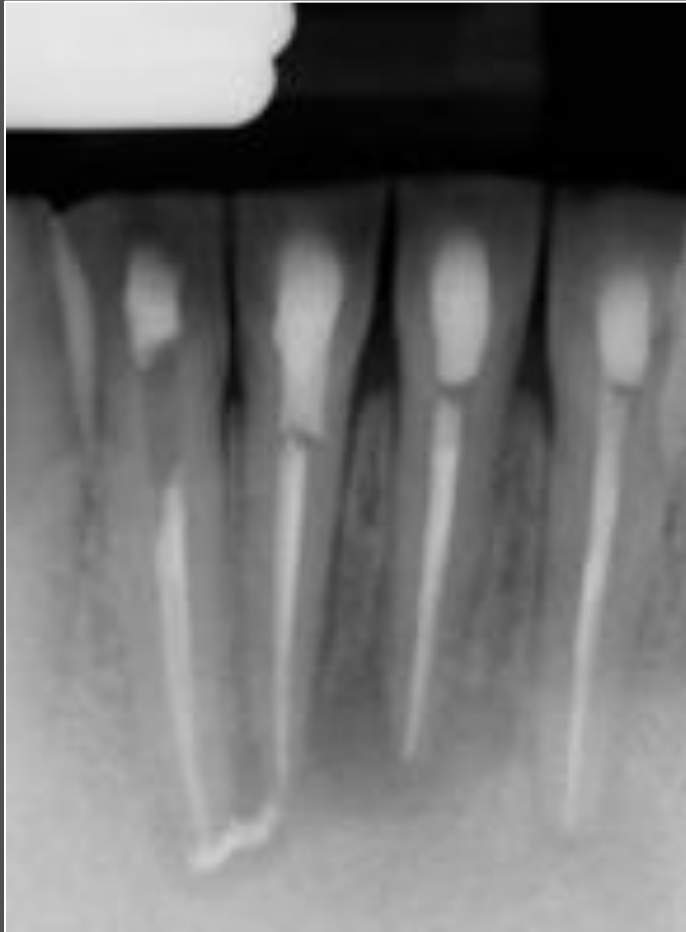


Initial clinical situation:

Extraction of both lower central incisors needed due to extensive root infection and fractured teeth. Highly limited space conditions.

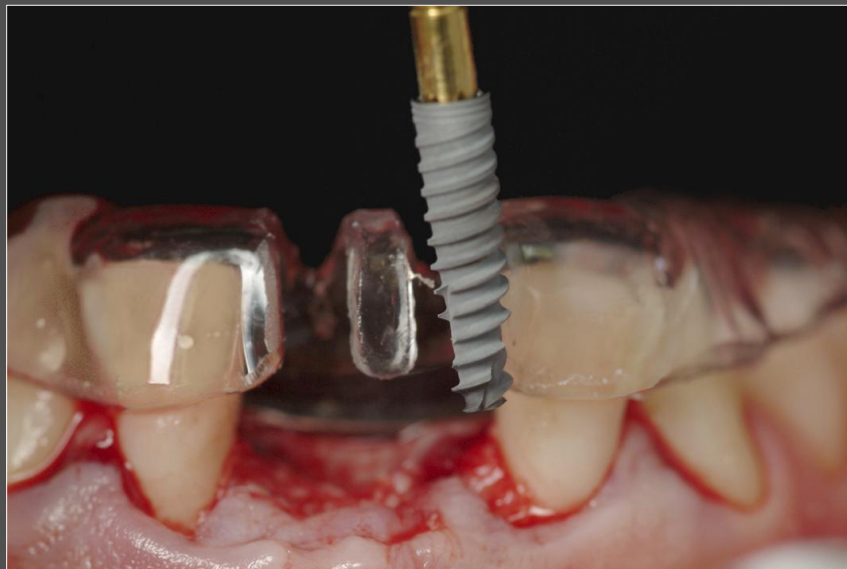
Courtesy of Dr. Iñaki Gamborena

NobelActive[®] 3.0

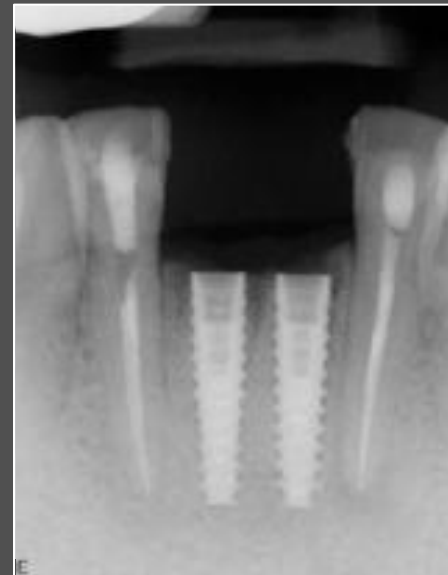

Pre-operative x-ray showing failed endodontic treatment.

NobelActive[®] 3.0

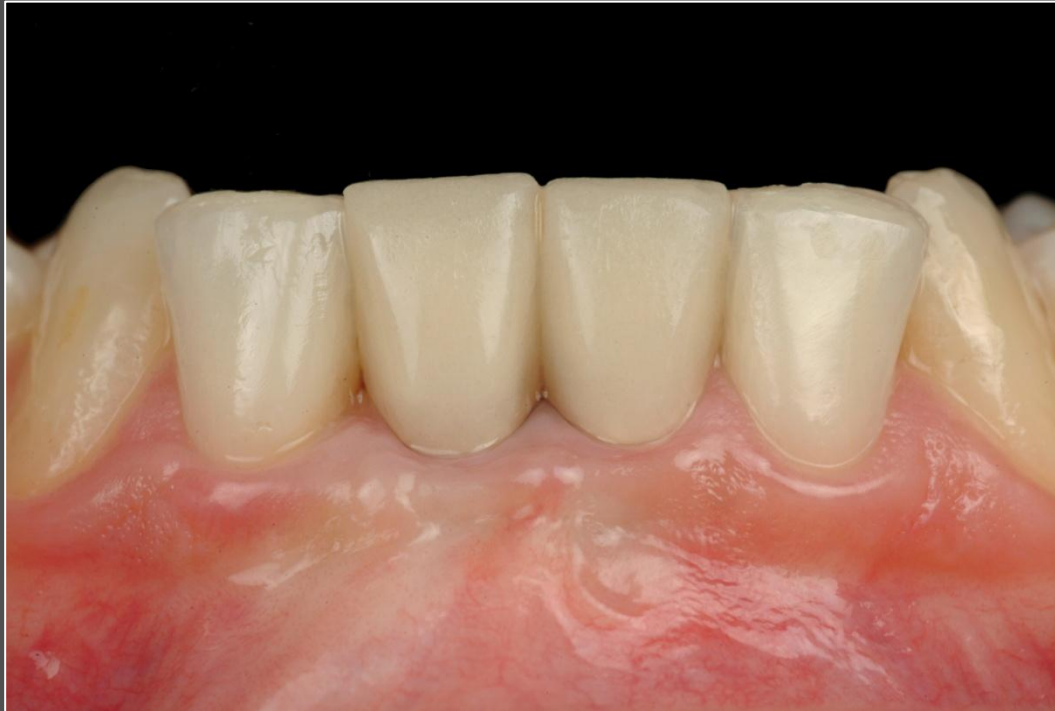

Placement of two NobelActive 3.0 x 13mm implants with immediate function protocol, including a connective tissue graft to increase soft tissue volume. A surgical guide was used to ensure optimal implant direction and depth.



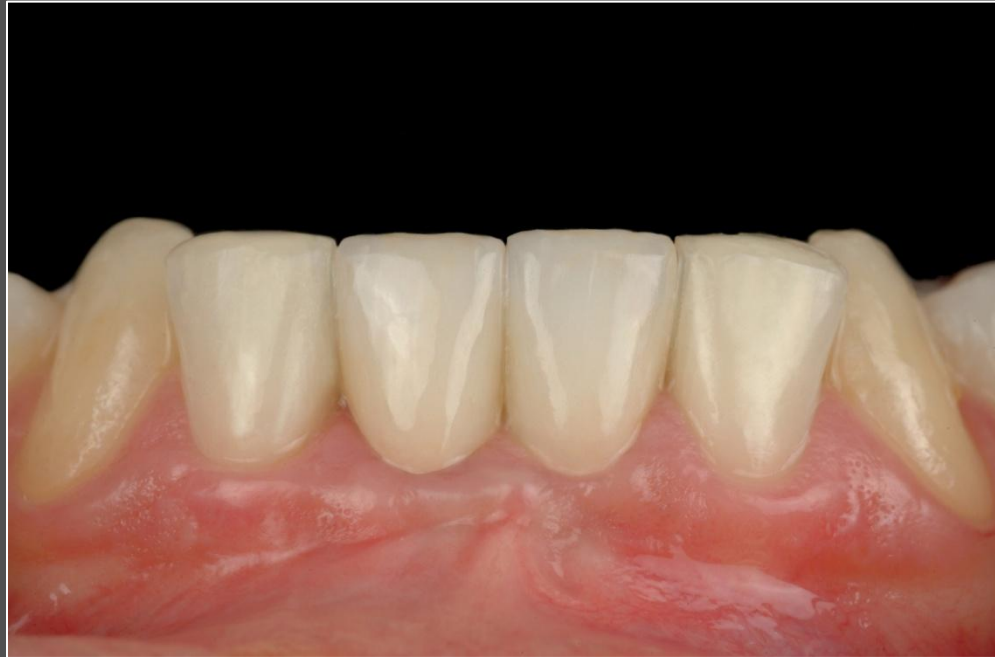NobelActive 3.0 implants in place.

NobelActive[®] 3.0



Development of an esthetic emergence profile three months after connective tissue graft maturation.

NobelActive[®] 3.0



Two NobelProcera Zirconia Crowns cemented on NobelProcera Abutments seven months after surgery.