

**Horizontal and vertical  
ridge augmentation using  
a bovine hydroxyapatite  
and ePTFE membrane  
with simultaneous  
implant placement**

**Dr. Lanka Mahesh**  
New Delhi, India



## CLINICIAN BIOSKETCH



Dr Lanka Mahesh has a bachelor's in dental surgery, and master's certificates in implant dentistry from UCLA, US and CUFD, Thailand. He has also undergone extensive surgical training in France, England, Spain and the USA. He is a visiting professor at the University of Murcia in Spain and is on the Faculty of the Stony Brook University (US)/Dental XP masters course in oral implantology. He is also an Honorary Consultant to the Armed Forces of India. Dr Lanka Mahesh is Fellow and Diplomate of ICOI, US, and a board member of ICOI Advance Credentialing Committee WAUPS, Korea.

He is Editor-in-Chief of the International Journal of Oral Implantology and Clinical Research. In addition, Dr Lanka is on the editorial boards of the Journal of Implants and Clinical Dentistry, JIACD-USA, Journal of Interdisciplinary Dentistry, E Journal of Dentistry and Journal of the Academy of Oral Implantology. Dr Lanka Mahesh is the author of the textbook, Practical Guide to Implant Dentistry, published by Quintessence.

He is an author of Colour Atlas of Oral Implantology which is co-authored by Craig Misch David Schward and Praful Bali. Currently Dr Lanka Mahesh is in private practice at The Specialist Clinic, South Delhi, Saket, New Delhi.





**Dr. Lanka Mahesh**

### **Patient**

28-year-old male, splint performed several years prior, no other relevant medical history

### **Clinical situation/Diagnosis**

21 and 22 mobile, atraumatic bite and healthy gingiva

### **Surgical solution**

Anesthesia with 2% Xylocaine®, full thickness flap, one tooth mesial and distal to the operative site, removal of 21 along with splint wire and 22 extraction, cleansing with saline, implants placed at 21 and 22 and defect grafted with creos™ xeniform and covered with a Titanium-Reinforced Cytoplast™ membrane.

5-months healing, control CBCT, healing collar placement.

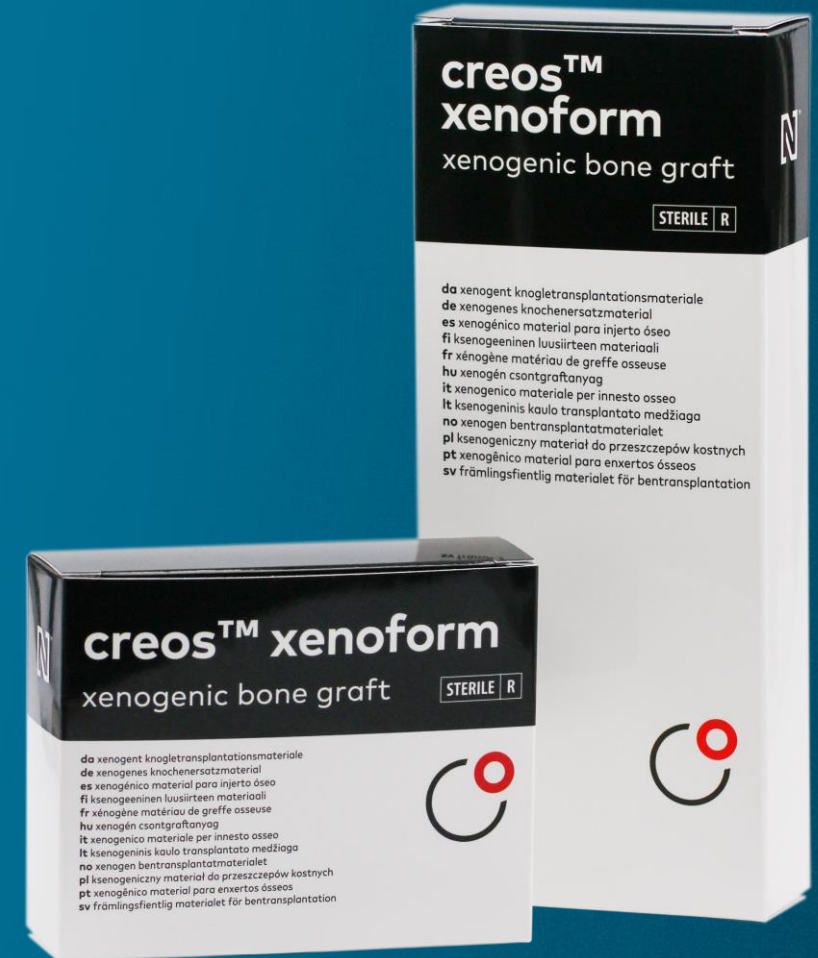3-weeks follow-up for impressions and PFM crowns delivery

### **Surgery date**

Implant placement and GBR: December 12, 2016

### **Total treatment time:**

6 months

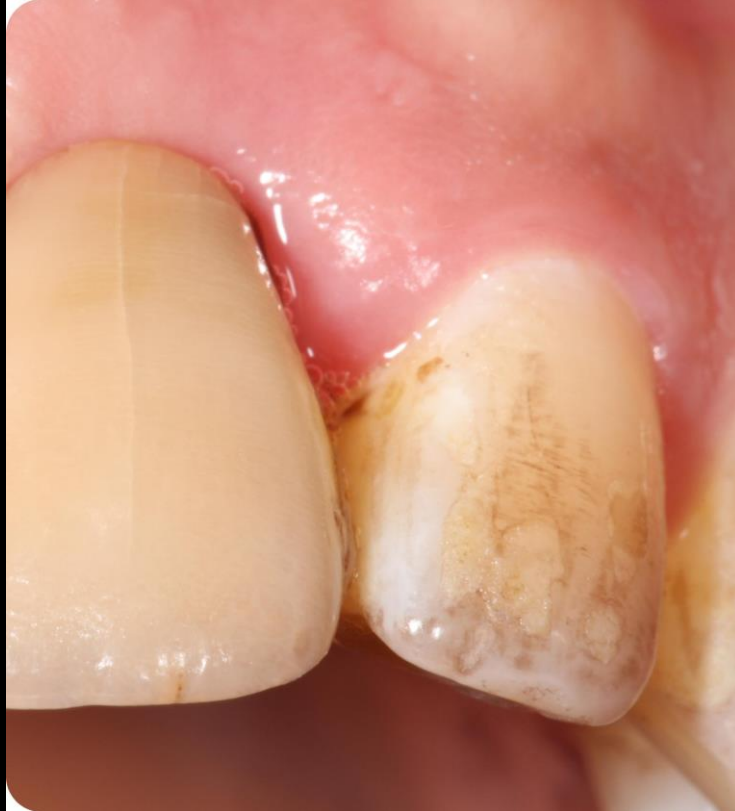

**Initial clinical  
situation**

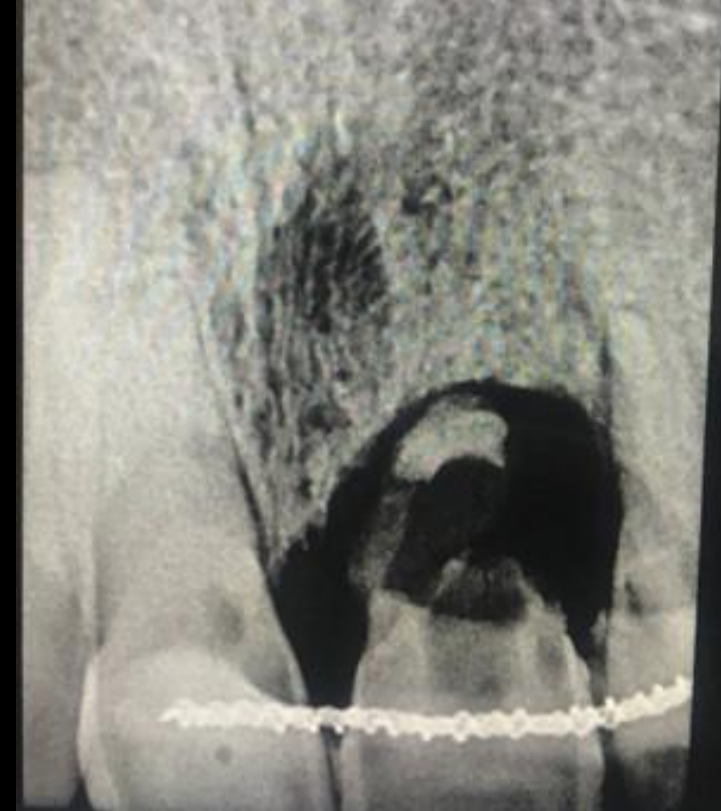
**Surgical  
procedure**

**Outcome**

**Initial clinical and radiographic examination**



**First clinical view of the teeth**



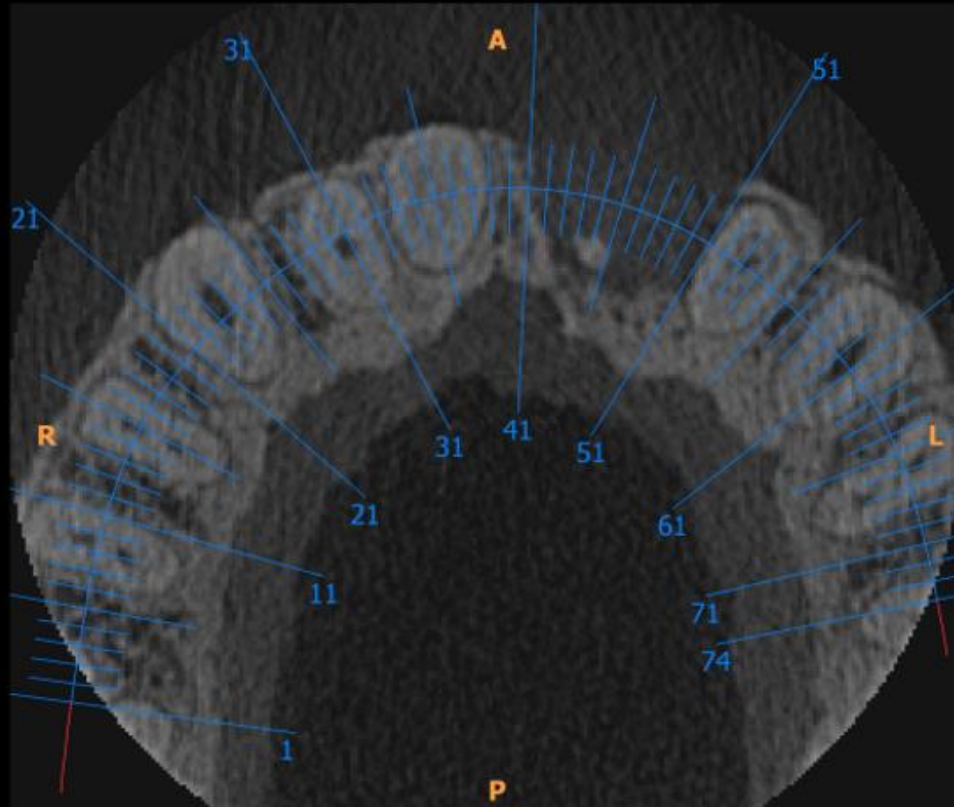
**Initial X-ray provides a first assessment of the defect**

# Initial clinical situation

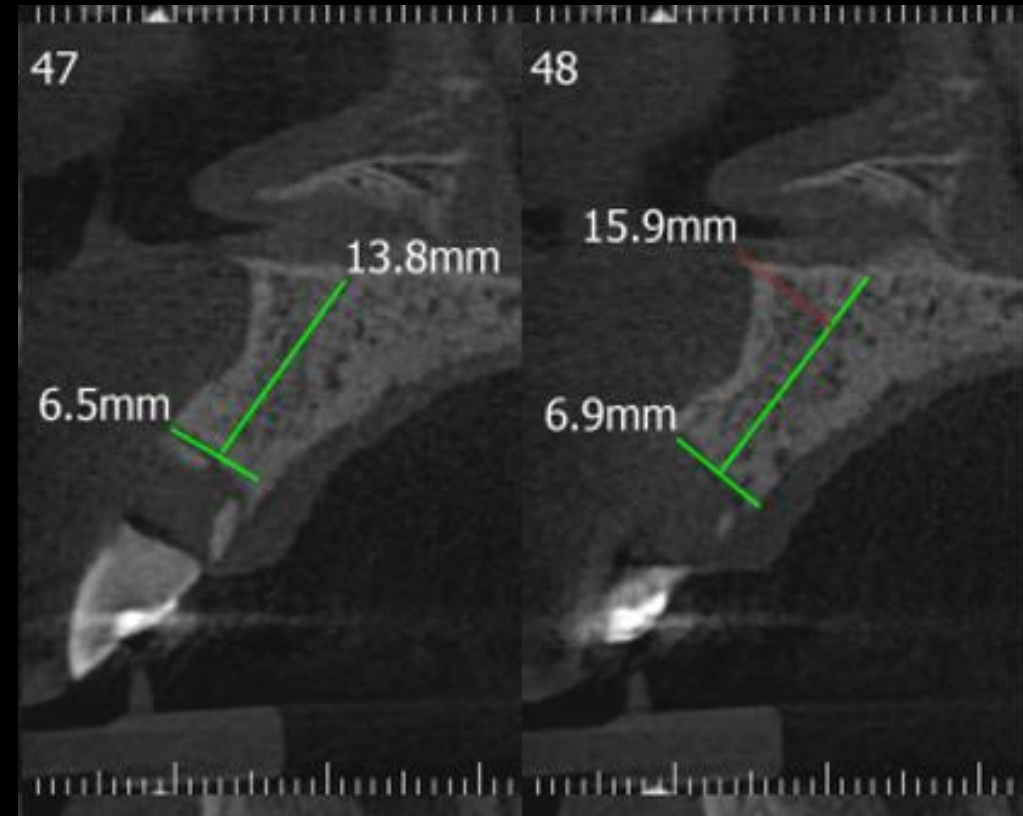
# Surgical procedure

# Outcome

## Pre-operative CBCT



Assessment of horizontal bone loss



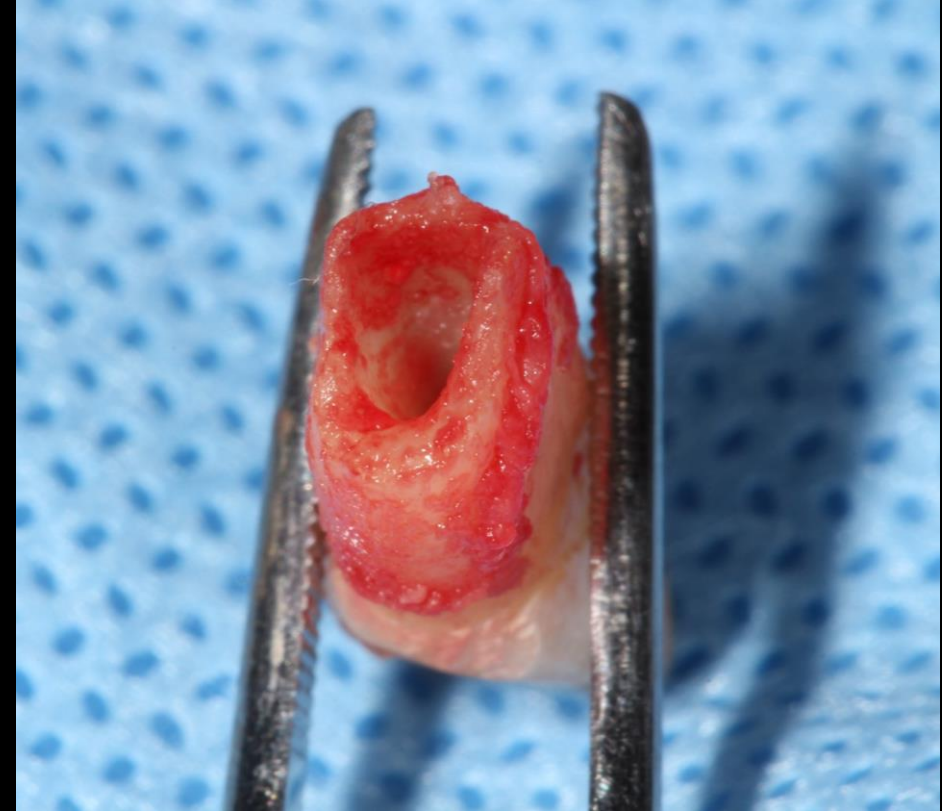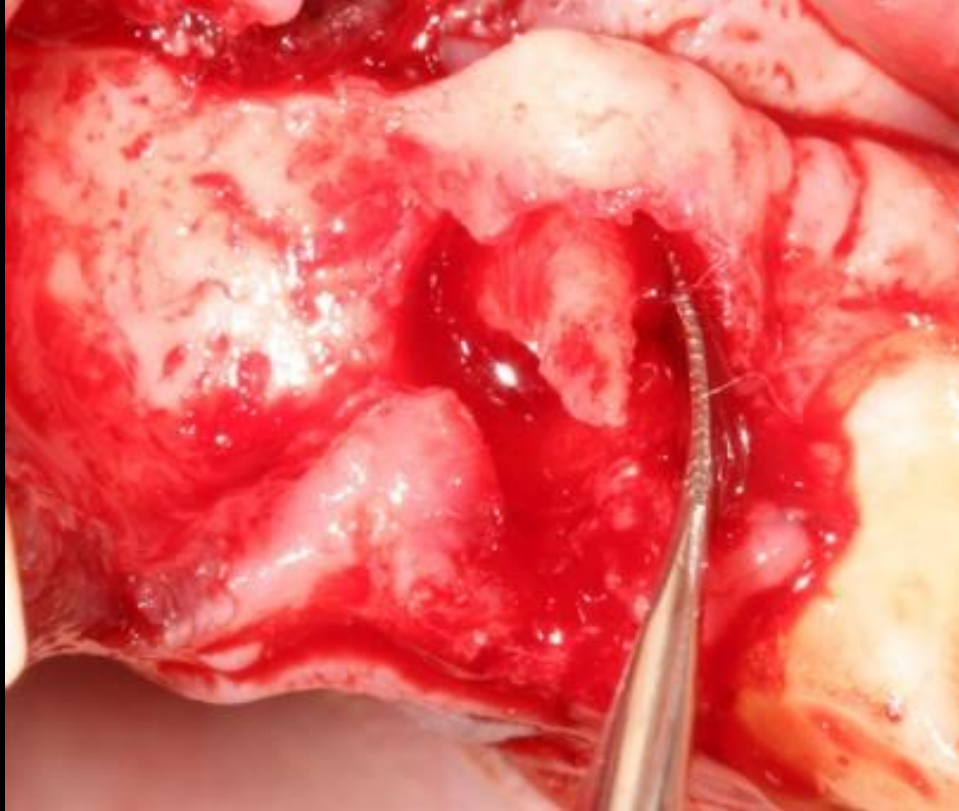
Measurement of vertical bone loss

**Initial clinical  
situation**

**Surgical  
procedure**

**Outcome**

**Extraction of 22**



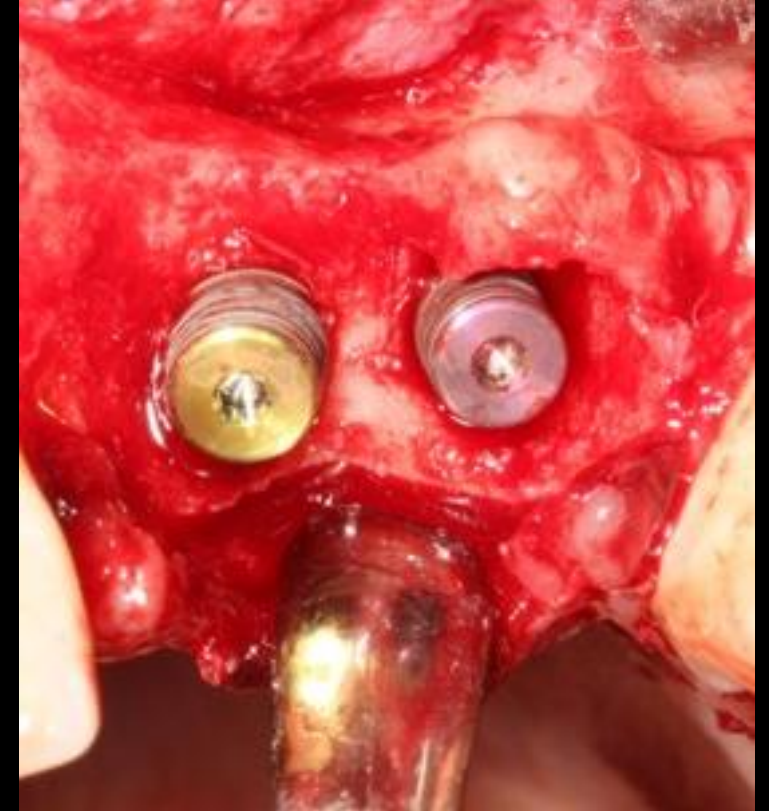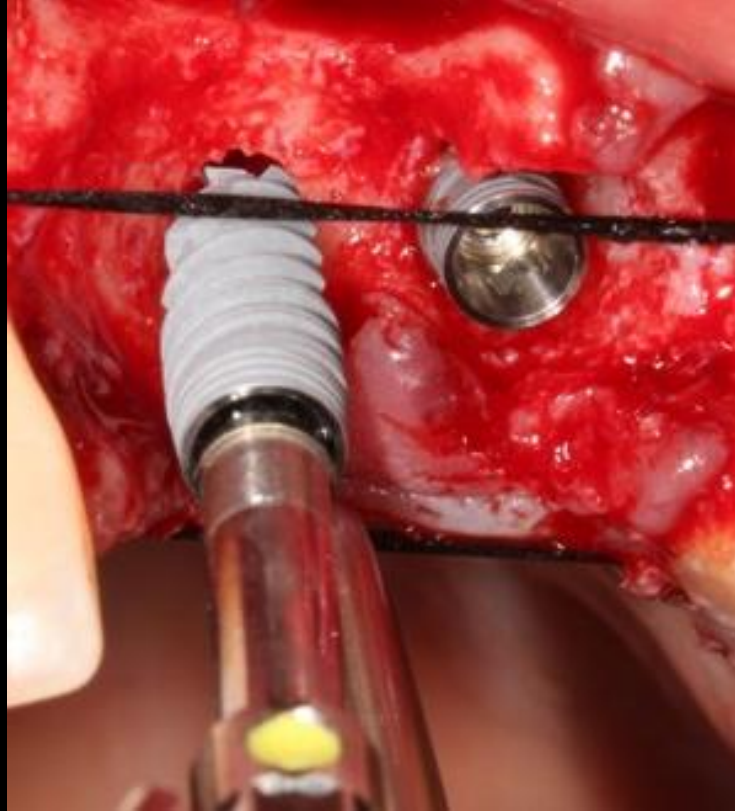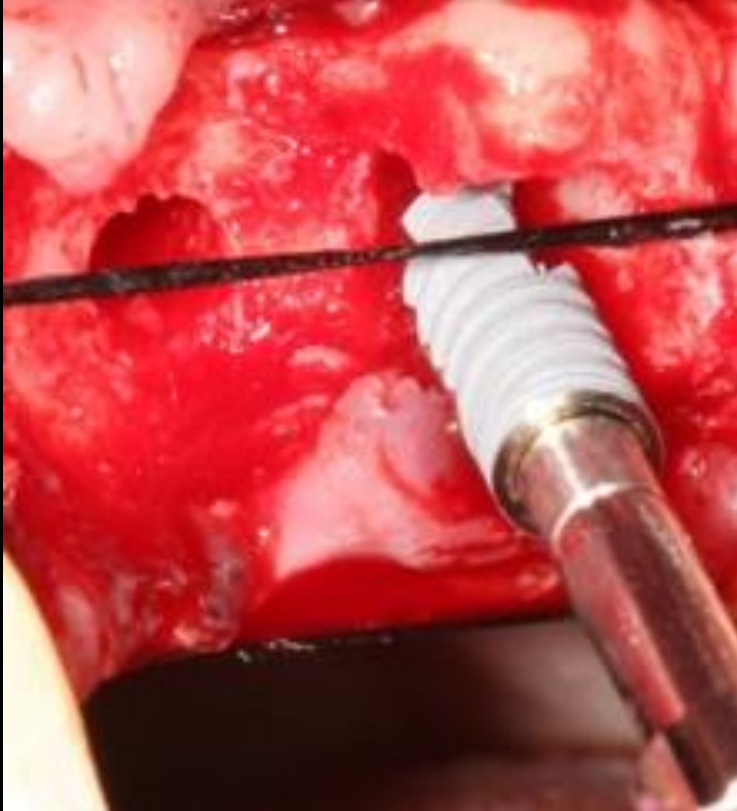**The root resorption is clearly visible at extraction**

**Initial clinical  
situation**

**Surgical  
procedure**

**Outcome**

**Implant positioning and cover screws**



**3.5/11.5 mm and 4.3/11.5 mm NobelActive® implants inserted at 40 Ncm torque**

**Cover screws in place**

## Initial clinical situation

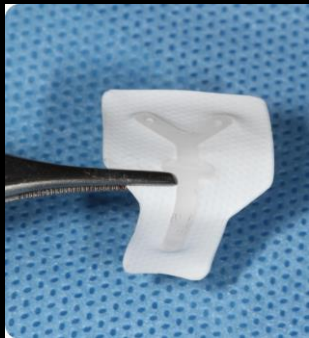
## Surgical procedure

## Outcome

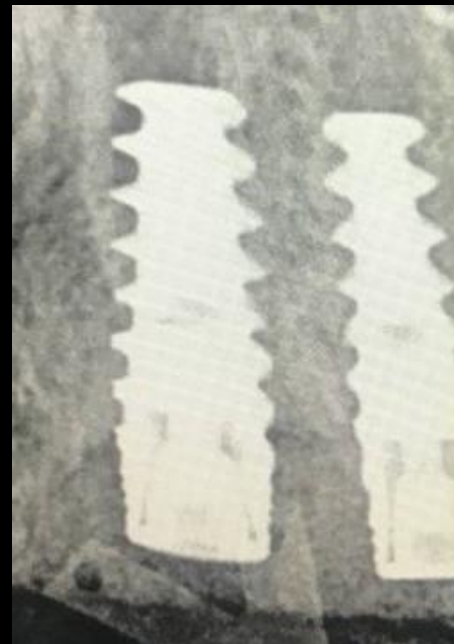### GBR and post-operative X-Ray



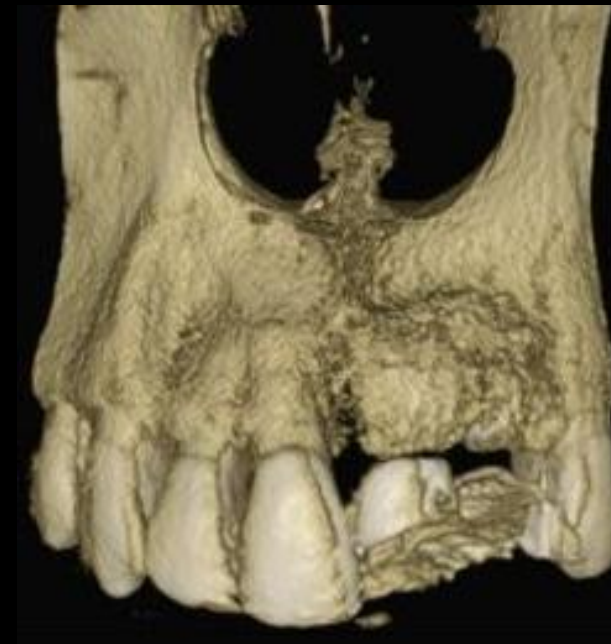The defect was filled with creos™ xeniform 0.5-1.2mm granules size, 0.5g



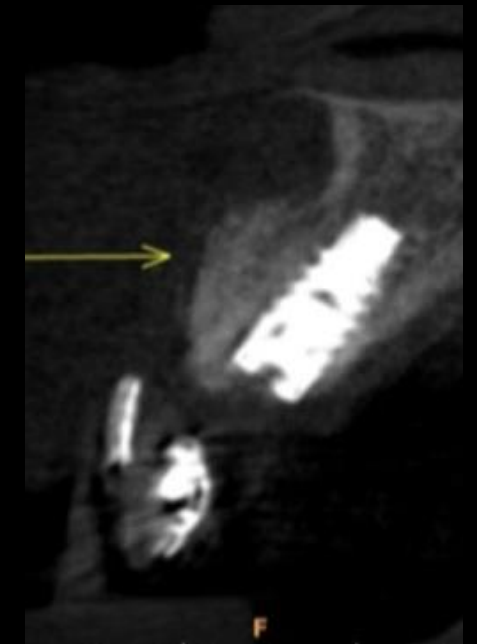The grafting material was covered with a Titanium-Reinforced Cytoplast™ membrane (Osteogenics Biomedical)



Post-operative X-Ray



5 months post operative CBCT sections show an evident horizontal and vertical bone volume gain



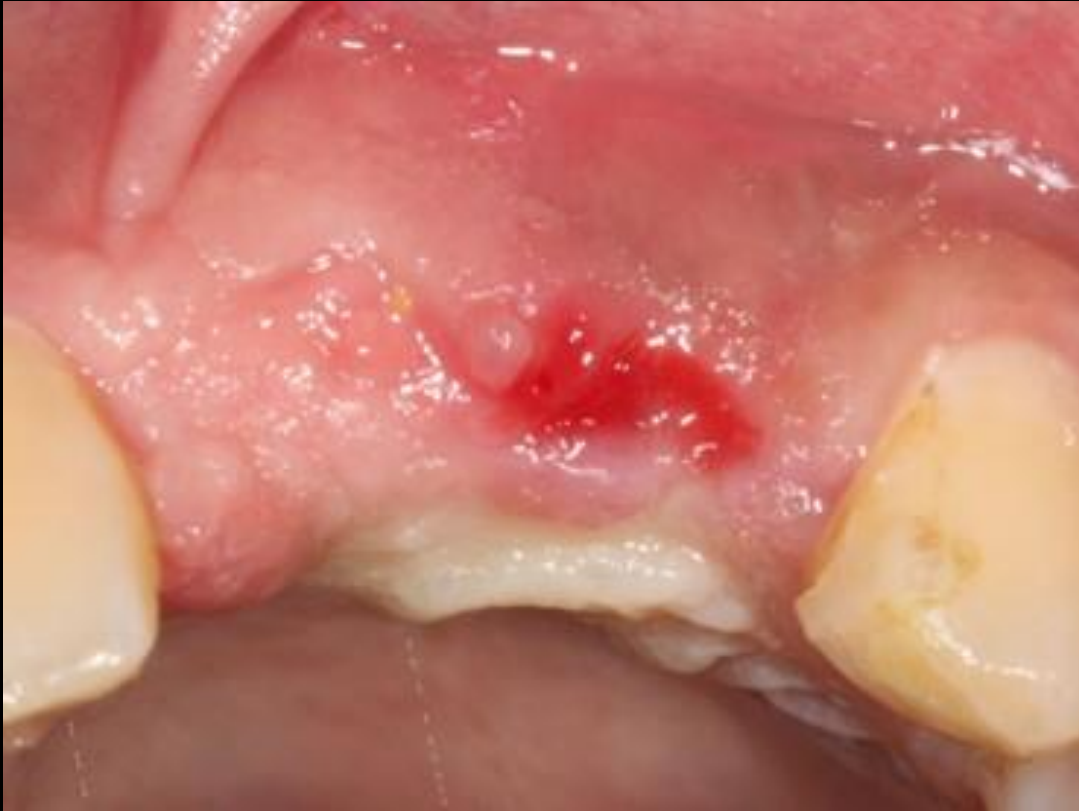

**Initial clinical situation**

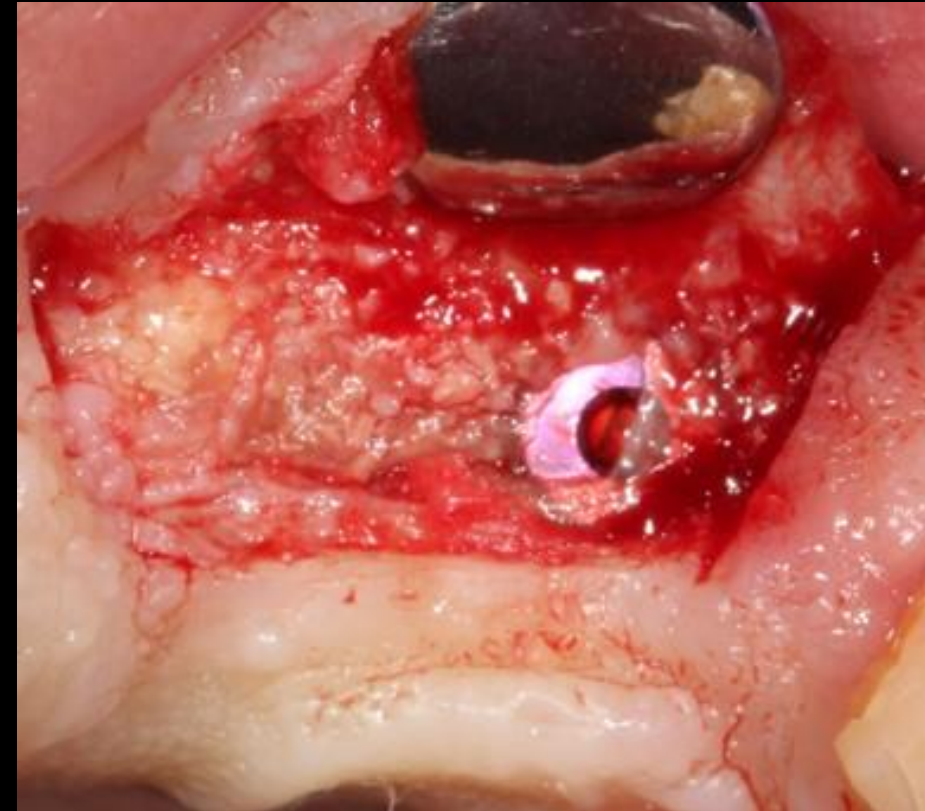
**Surgical procedure**

**Outcome**

**5-months re-entry**



**Clinical situation at 5-months re-entry**



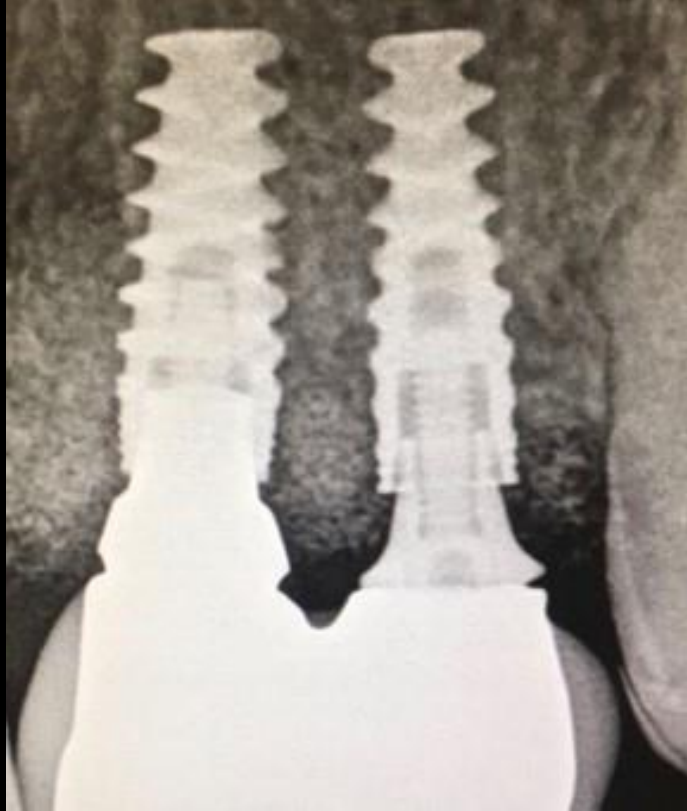**Complete integration of bone graft after membrane removal is evident. The bone growth over the implants was gently removed with a wheel bur on a high-speed handpiece.**

**Initial clinical situation**

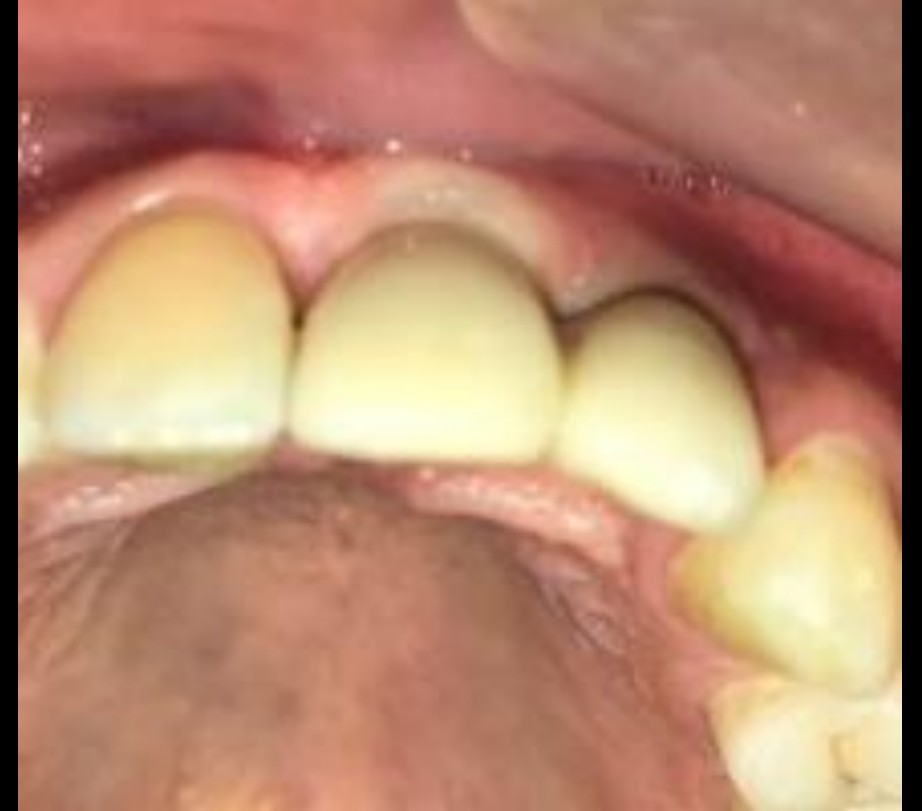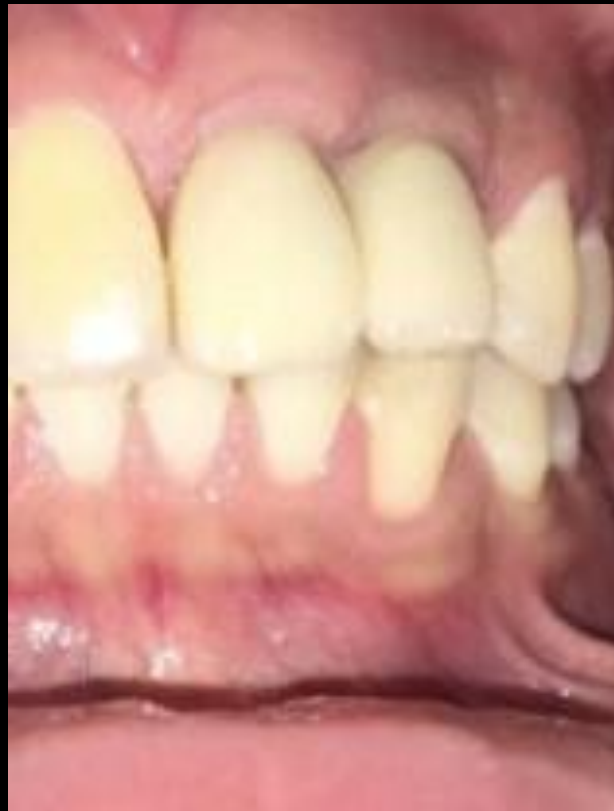**Surgical procedure**

**Outcome**

**1-year follow-up**



**1-year X-Ray: Bone growth in vertical and horizontal dimension is clearly evident**



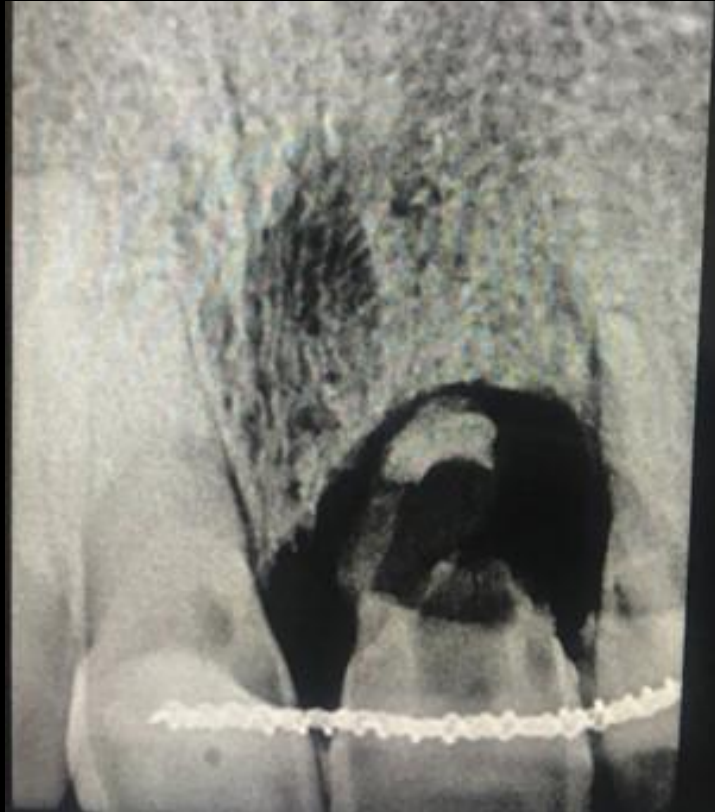
**Clinical situation at 1-year Follow-up**

**Initial clinical situation**

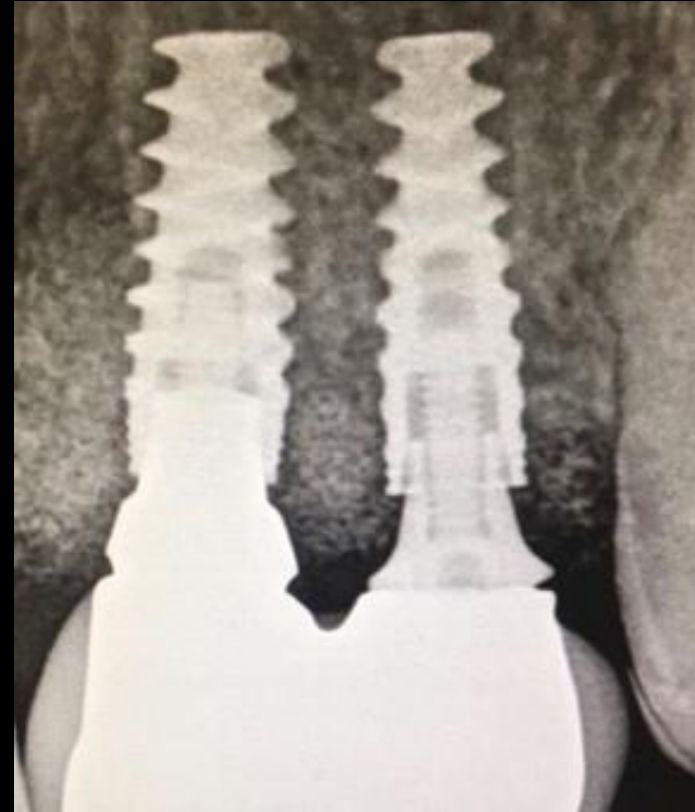**Surgical procedure**

**Outcome**

**Before and after**



**Pre-surgical x-ray**



**1-year follow-up X-Ray**

**Initial clinical situation**

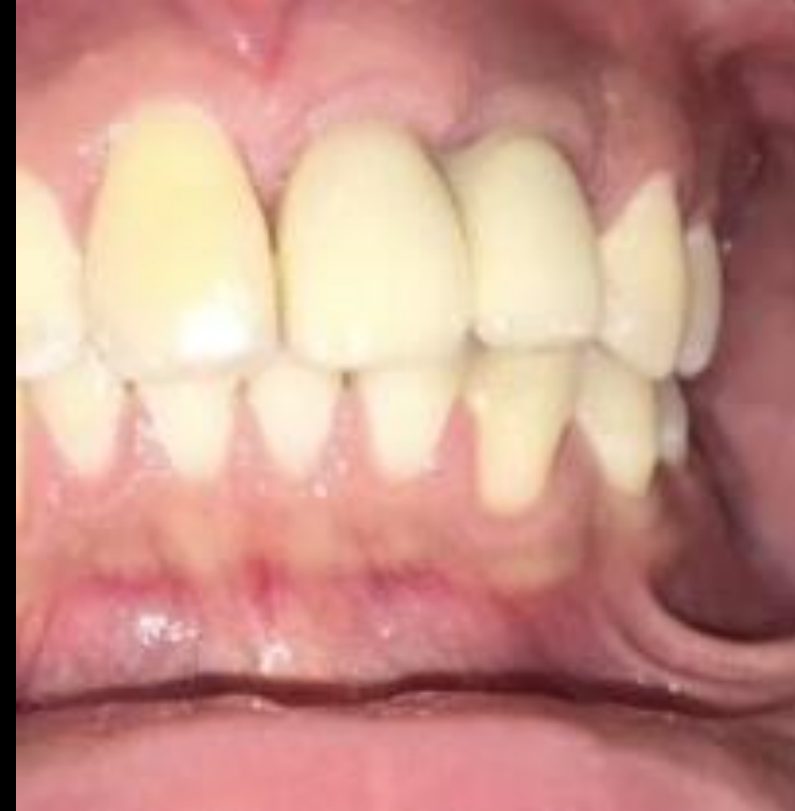**Surgical procedure**

**Outcome**

**Before and after**



**Pre-surgical clinical assessment**



**1-year follow-up X-Ray**

## Case courtesy of Dr. Lanka Mahesh



GMT 83801 GB 2302 © Nobel Biocare Services AG, 2023. . All rights reserved. Distributed by: Nobel Biocare. Nobel Biocare, the Nobel Biocare logotype and all other trademarks are, if nothing else is stated or is evident from the context in a certain case, trademarks of Nobel Biocare. Please refer to [nobelbiocare.com/trademarks](https://nobelbiocare.com/trademarks) for more information. Product images are not necessarily to scale. All product images are for illustration purposes only and may not be an exact representation of the product. Please contact the local Nobel Biocare sales office for current product assortment and availability. Disclaimer: For prescription use only. Caution: Federal (United States) law or the law in your jurisdiction may restrict this device to sale by or on the order of a licensed clinician, medical professional or physician. See Instructions For Use for full prescribing information, including indications, contraindications, warnings and precautions. Ti-oss® (Chiyewon Co., Ltd.) is distributed as creos™ xenoform since January 2023. Legal Manufacturer: Chiyewon Co., Ltd. 6F, 192 Gyeongchunro, Guri si, Gyeonggido, Korea 11927.

Nobel Biocare does not take any liability for any injury or damage to any person or property arising from the use of this clinical case. This clinical case is not intended to recommend any measures, techniques, procedures or products, or give advice, and is not a substitute for medical training or your own clinical judgement as a healthcare professional. Viewers should never disregard professional medical advice or delay seeking medical treatment because of something they have seen in this clinical case. Full procedure is not shown. Certain sequences have been cut.