

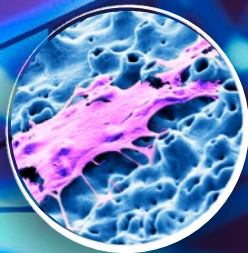

Science First

Volume 5, Issue 1

2018

NobelActive®

Over 10 years of clinical experience



Cover

NobelActive is an implant like no other. The back-tapered coronal design of NobelActive is designed to optimize bone and soft tissue volume for natural-looking esthetics. This is highlighted in the image in the foreground and the left inset. The right inset image focuses on a mesenchymal stem cell adhered to the proven TiUnite® implant surface. The background image shows the 3D mesh of the upper surface fading into a 2D outline illustration, combined with a NobelActive rendering focusing on the upper part of the implant.

Contents

NobelActive

Over ten years of clinical experience with NobelActive®	4
Scientific evidence backs NobelActive® implants	5
Key studies	6
Clinical cases	9
Overview of studies	12
References	15

Over ten years of clinical experience with NobelActive®

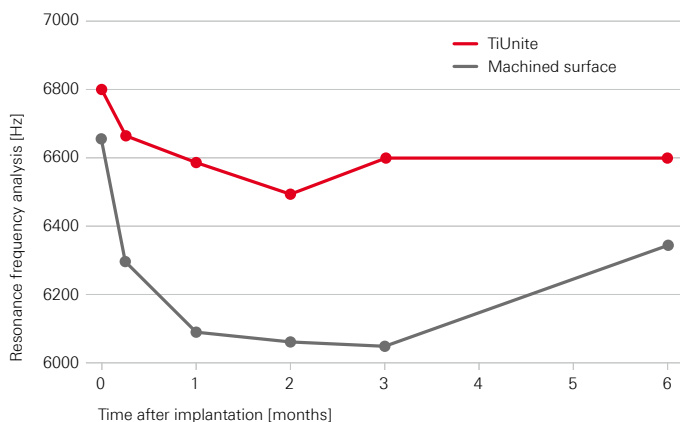
The innovation of NobelActive represented a breakthrough in implant design, harmonizing biomedical engineering expertise with the clinical needs and the wisdom of clinicians. NobelActive's expanding tapered implant body condenses bone gradually while the apex with drilling blades enables a smaller osteotomy. These features help to achieve good primary stability in demanding situations, such as soft bone or extraction sockets.

Perfect harmony of drilling protocol, geometric design and implant surface

The NobelActive surgical protocol and implant design are designed to provide good primary stability and support immediate loading. Reverse-cutting flutes with drilling blades on the apex enable experienced clinicians to adjust the implant position during placement for an optimized restorative orientation, particularly in extraction sites. NobelActive's patented back-tapered collar, together with the strong conical connection and built-in platform shifting, can aid in preservation of soft tissue and marginal bone.^{1, 2, 3, 4}

The osteoconductive properties of NobelActive's TiUnite surface, supporting fast apposition of newly formed bone, helps ensure that good stability achieved at implant insertion can be maintained throughout the critical healing phase. Clinically, this relationship between the osteoconductive effect of the TiUnite surface and implant stability in patients with predominantly soft bone was confirmed by Glauser et al, with Brånemark IV implants.⁵

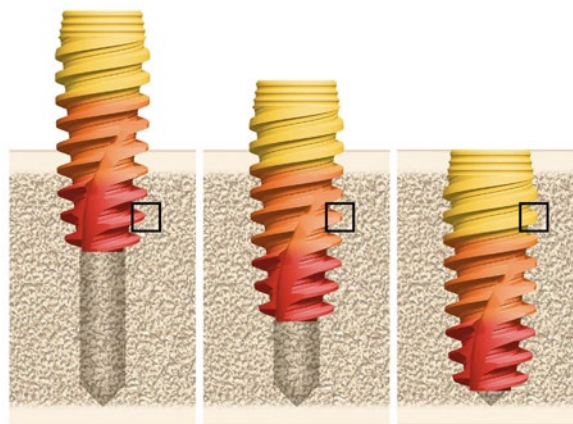
Good stability in the critical healing phase allows for Immediate Function



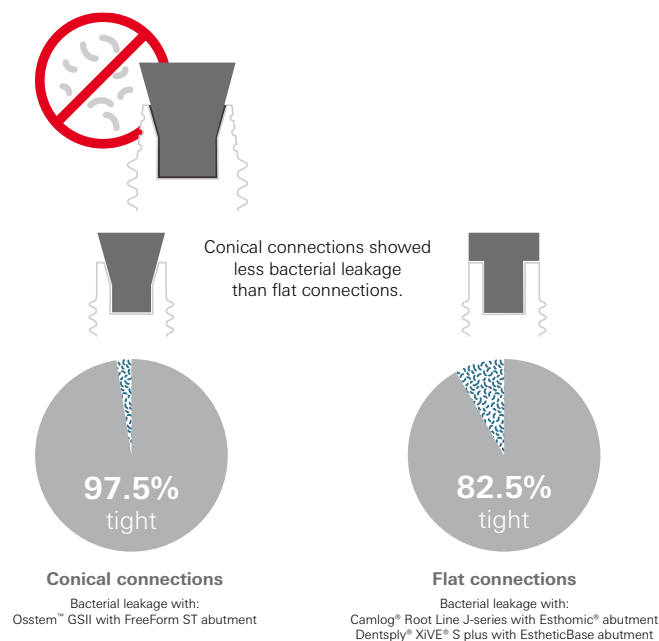
Higher stability with immediately loaded TiUnite surface implants (external hexagonal connection) than with the same implants with machined surface in the posterior maxilla.⁵

The conical connection of NobelActive seems to have an advantage against leakage. Conical connection implants, including Nobel Biocare's conical connection, showed lower bacterial leakage compared to flat connections, in an in-vitro model.⁶

Good primary stability in demanding situations, such as soft bone or extraction sockets



NobelActive's expanding tapered implant body condenses bone gradually while the apex with drilling blades enables a smaller osteotomy.



The included NobelActive Conical Connection implants with Snappy Abutment showed no leakage in this model.⁶

Scientific evidence backs NobelActive® implants

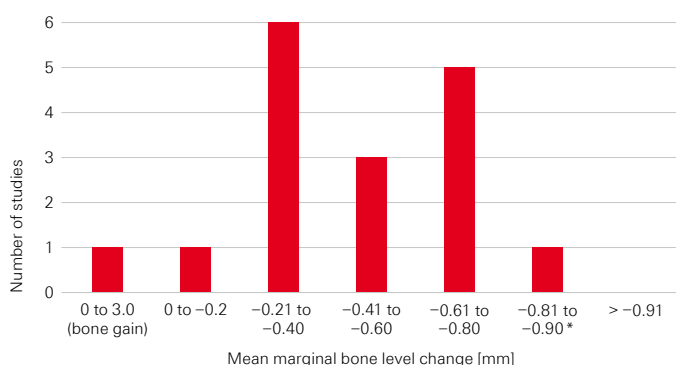
In the more than 10 years since its introduction to the market, over 14,300 NobelActive implants in over 2,600 patients have been clinically evaluated in 41 clinical studies^A (see tables on pages 12 to 14).

Key findings^B of clinical studies with NobelActive are:

- Studies reporting mean marginal bone level change with NobelActive implants show low bone remodeling in the healing phase followed by stable or increasing bone levels.^{1, 2, 3, 7, 8}
- After up to 6.7 years of function, NobelActive shows excellent hard- and soft-tissue outcomes and 100% survival rate.⁹
- The implant design and conical connection with built-in platform shifting result in less crestal bone change than a comparable implant without these features.^{2, 3}
- Papilla size significantly improves during the first year, and from implant insertion until 3 and 5 years.^{1, 7}
- The unique implant design ensures good primary stability¹⁰ even in soft bone and fresh extraction sockets.^{1, 3, 7, 8, 9, 11, 12}
- NobelActive is a reliable implant for Immediate Function protocols,^{1, 4, 11} as well as challenging cases such as severely atrophic maxilla.^{13, 14}
- NobelActive is successful with full-arch restorations including the All-on-4® treatment concept.^{14, 15, 16}

Twenty-two studies with 1 to 5 years' follow-up have evaluated bone level change with NobelActive implants. No study with a minimum of 1-year and up to 5-years of follow-up had a mean bone remodeling of over -0.89 mm.^{17, 18}

Studies report mean marginal bone level change from implant insertion with NobelActive implants



* Excludes a single study that evaluated a predecessor NobelActive implant that was not made commercially available, which had a slightly different connection and back-taper.

A Only peer-reviewed publications with minimum of 10 implants and minimum one-year follow-up. Meeting abstracts, reviews, single case reports, technique descriptions, and animal and in-vitro tests are excluded.

B Note: Findings may have been reported in clinical studies presented as conference abstracts.

NobelActive in patients with limited residual bone or inter-dental space

The design of NobelActive allows its insertion in difficult situations, e.g. in patients with limited residual bone or inter-dental space.

In a retrospective study to evaluate the clinical performance of 153 NobelActive implants placed in a tilted manner in fresh extraction sockets and immediately restored with Multi-unit Abutments, the survival rate was 99.3% at 3-year follow-up.¹⁹ Abutment angulation and implant diameter had no impact on mean marginal bone remodeling, which was -0.68 mm \pm 1.2 mm after 3 years.¹⁹

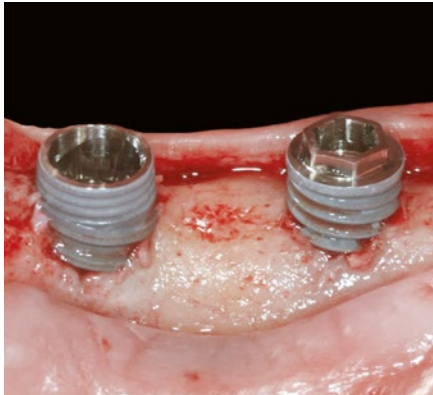NobelActive 3.0 implants in the esthetic zone allow clinicians to restore lateral maxillary incisors and lateral and central mandibular incisors immediately, with a high level of survival. In a recent publication by Kolinski and coworkers,²⁰ interim 1-year results of a 5-year study with 82 NobelActive 3.0 implants in the esthetic zone were reported. Implant survival was 96.7% and no implants fractured. Bone levels were stable with only -0.57 mm remodeling from insertion to 6 months, and -0.25 mm from insertion to 1-year follow-up. Pink esthetic scores significantly improved from 6.3 ± 0.4 at pre-treatment, to 8.5 ± 2.1 after placement of the definitive prosthesis, and to 10.5 ± 2.5 at 1 year. This further speaks to the crucial interrelationship between implant surface, drill protocols and geometrical design.

Key studies


Three-year post-loading results of a randomised, controlled, split-mouth trial comparing implants with different prosthetic interfaces and design in partially posterior edentulous mandibles

Pozzi A, Tallarico M, Moy PK


Eur J Oral Implantol 2014;7(1):47-61.



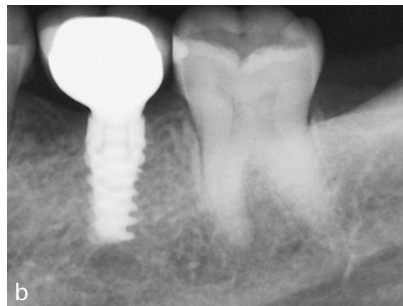
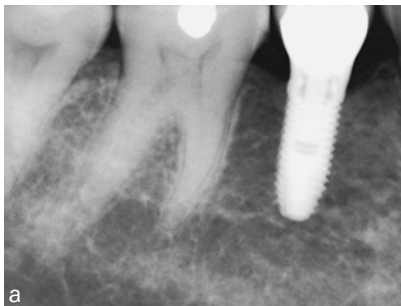
Clinical view of the two investigated implant designs.



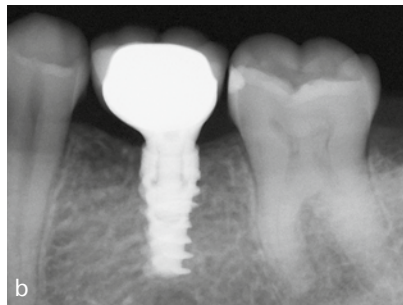
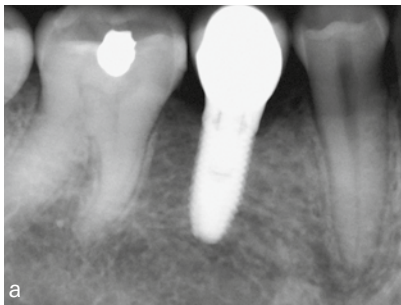
Characteristics of the two different implant designs and connections used in this study



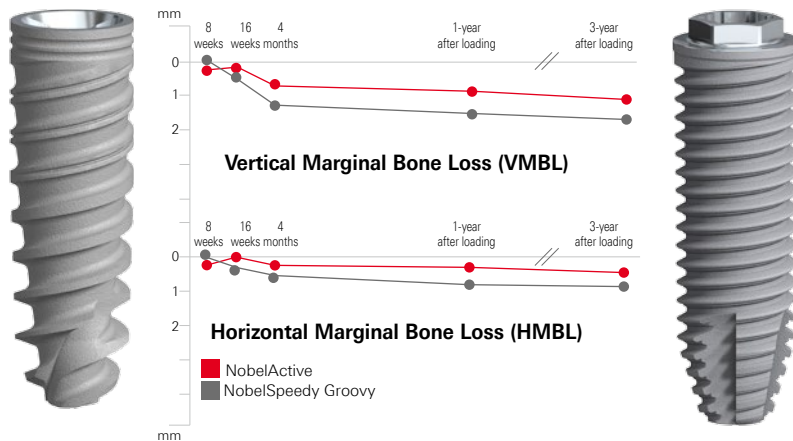
Diagrams showing the measurement locations utilized in this investigation:
 Vertical marginal bone loss (VMBL) = the distance from the most coronal margin of the implant collar (IC) and the top of the bone crest (BC)
 Horizontal marginal bone loss (HVBL) = the distance from the internal aspect of the socket wall at the level of the alveolar crest (IAC) to the implant surface (I).



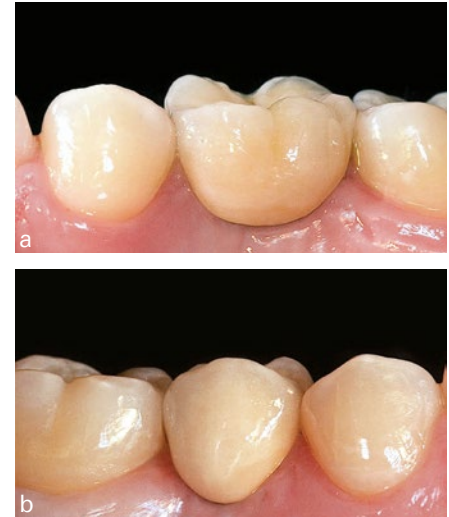Periapical radiographs after 1 year in function:
 (a) NobelSpeedy Groovy implant (control group);
 (b) NobelActive implant (test group)



Periapical radiographs after 3 years in function:
 (a) NobelSpeedy Groovy implant (control group);
 (b) NobelActive implant (test group)



Graph showing the vertical and horizontal marginal bone loss from implant insertion to 3-year follow-up of all implants



Intraoral photographs after 3 years in function:
(a) NobelSpeedy Groovy implant (control group);
(b) NobelActive implant (test group).

Original abstract

Purpose: To compare the clinical and radiological outcomes of two implant designs with different prosthetic interfaces and neck configurations.

Materials and methods: Thirty-four partially edentate patients randomly received at least one NobelActive implant (Nobel Biocare, Goteborg, Sweden) with back-tapered collar, internal conical connection and platform shifting design, and one NobelSpeedy implant (Nobel Biocare) with external hexagon and flat-to-flat implant-abutment interface according to a split-mouth design. Follow-up continued to 3 years' post-loading. The primary outcome measures were the success rates of the implants and prostheses, and the occurrence of any surgical and prosthetic complications during the entire follow-up. Secondary outcome measures were: horizontal and vertical peri-implant marginal bone level (MBL) changes, resonance frequency analysis values at implant placement and loading (4 months), sulcus bleeding index (SBI) and plaque score (PS).

Results: No drop-out occurred. No implants and prostheses failures were observed to the 3-year follow-up. MBL changes were statistically significant different with better results for the NobelActive implants for both horizontal and vertical

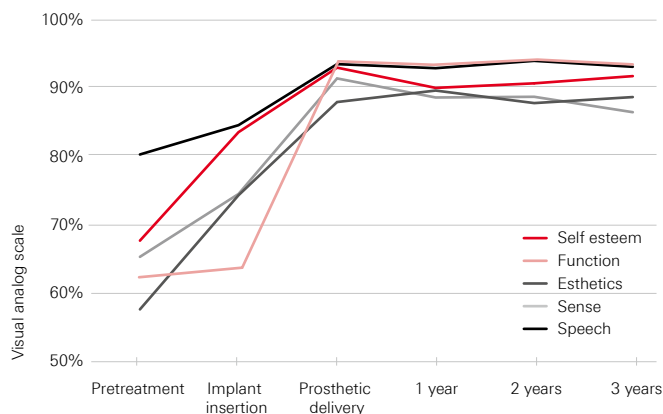
measurements ($p = 0.000$). After 3 years post-loading, the NobelActive implants underwent a mean vertical bone resorption of 0.66 mm, compared with 1.25 mm for the NobelSpeedy Groovy implants ($p = 0.000$); the mean horizontal bone resorption was 0.19 mm for the NobelActive implants and 0.60 mm for the NobelSpeedy Groovy implants ($p = 0.000$). A high ISQ value was found for both implants, and no statistically significant difference was found for ISQ mean values between interventions ($p = 0.941$ at baseline; $p = 0.454$ at implant-abutment connection; $p = 0.120$ at prosthesis delivery). All implants showed good periodontal health at the 3-year-in-function visit, with no significant differences between groups.

Conclusion: The results of this research suggest that in well-maintained patients, the MBL changes could be affected by the different implant design. After 4 months of unloaded healing, as well as after 3 years in function, both implants provided good results, however vertical and horizontal bone loss had statistically significant differences between the two groups (difference of 0.58 ± 0.10 mm for the vertical MBL, and 0.4 ± 0.05 mm for the horizontal MBL), with lower values in the NobelActive implants, compared to the NobelSpeedy Groovy implants.

Evaluation of a variable-thread tapered implant in extraction sites with immediate temporization: a 3-year multi-center clinical study

Kolinski ML, Cherry JE, McAllister BS, Parrish KD, Pumphrey DW, Schroering RL

J Periodontol 2014;85(3):386–394.



Significant improvements in patient self-ratings right after implant insertion and at delivery of the final prosthesis.

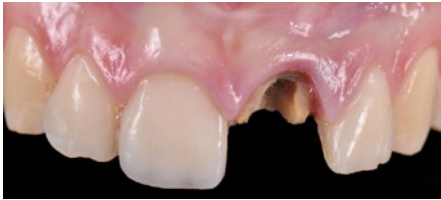Summary of the study

Kolinski et al. (2014) report excellent results: high CSR, stable bone levels, good soft tissue health and patient satisfaction using NobelActive implants. A total of 60 implants were placed in 55 patients at 6 centers, all in extraction sites and subjected to Immediate Function. Patients requiring major bone augmentations were excluded, while minor augmentations were permitted. CSR after 3 years was 98.3%. Bone levels were exceptionally stable: Bone remodeling of a mere -0.2 mm during the first 6 months quickly stabilized and showed even a non-significant bone gain of 0.3 mm at 3 years. Papilla scores increased significantly ($p < 0.001$) from insertion to 3-year follow-up, with most of the increase occurring during the first year.

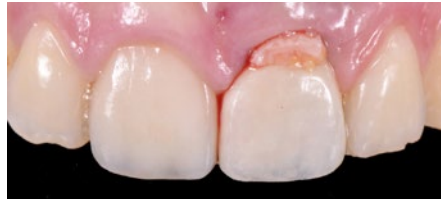The results on quality of life are also noteworthy, with significant improvements in patient self-ratings on esthetics, self-esteem, function, sense and speech. The authors therefore conclude that NobelActive can be used safely and effectively under demanding conditions such as immediate tooth replacement in extraction sites – not only with regards to CSR and hard- and soft-tissue health, but also in terms of patient satisfaction.

Clinical cases

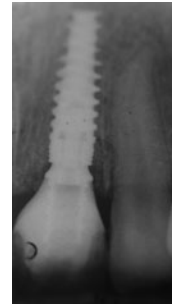
Excellent esthetic outcome at 8-year follow-up with immediate temporization on a NobelActive implant



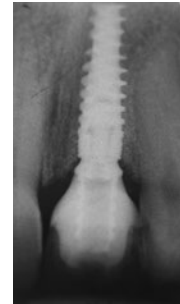Clinical situation before treatment.



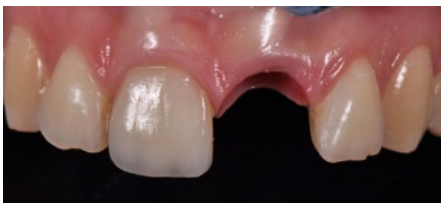Clinical view of temporary after surgery (immediate provisionalization).



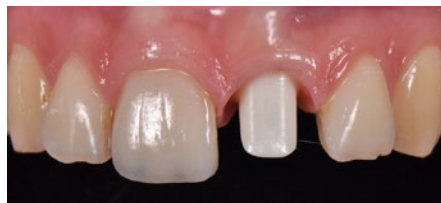Radiograph showing temporary after surgery.



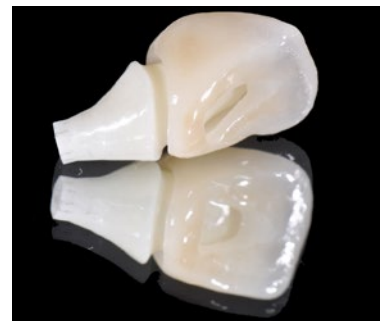Radiograph showing temporary after 3 months.



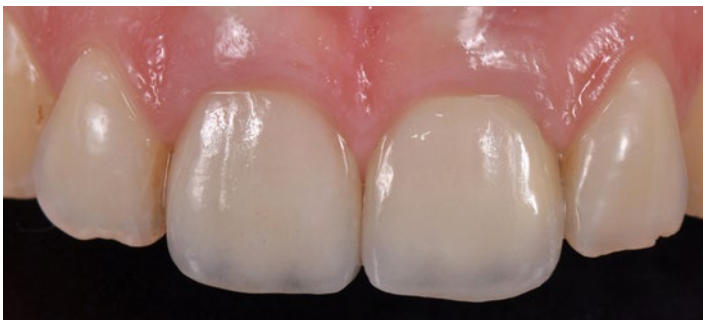Clinical view of soft tissue before finalization.



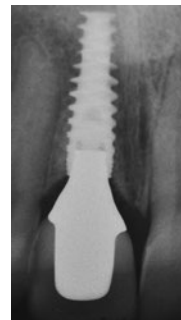Zirconia abutment in situ.



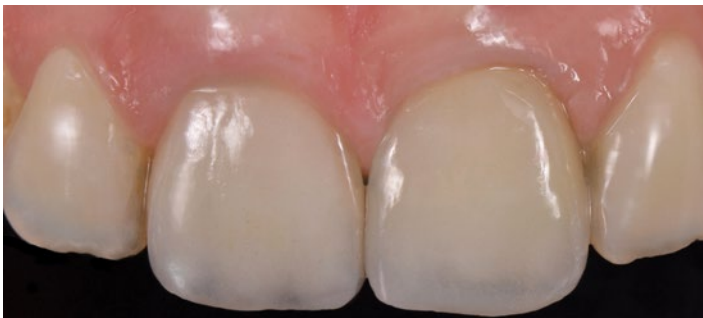Screw-retained crown



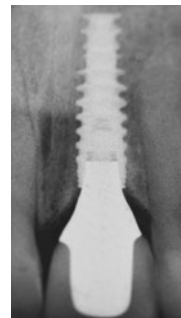Clinical view following finalization.



Radiograph following finalization.



Excellent esthetic outcome at 8 years' follow-up



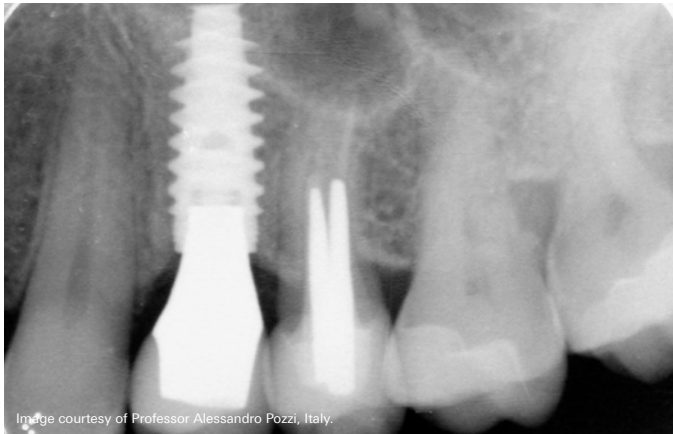
Radiograph at 8 years' follow-up

Images courtesy of Dr. Giacomo Fabbri, Italy.

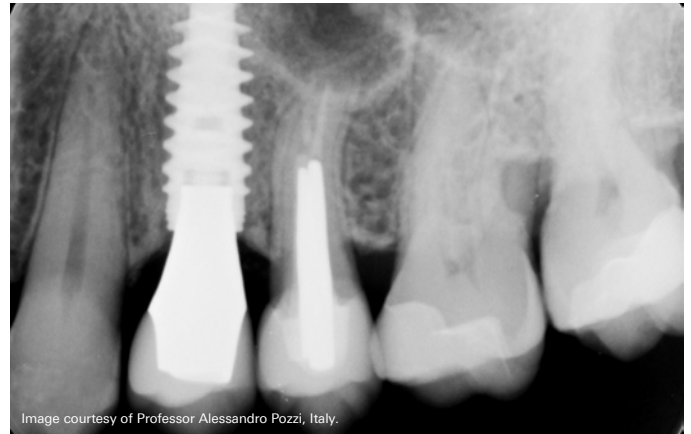
NobelActive supporting hard and soft tissue long-term

Immediate implant placement in a fresh extraction socket of a NobelActive RP implant 4.3 mm × 13 mm. Socket augmentation was performed, using xenograft and autogenous soft tissue grafting harvested from the tuberosity

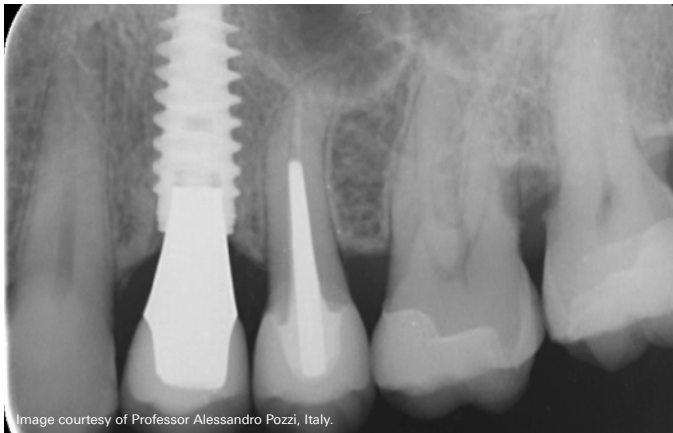
area, to close the socket and increase the amount of soft tissue at the recipient site. A lithium disilicate crown was cemented onto an anatomically shaped zirconia abutment.



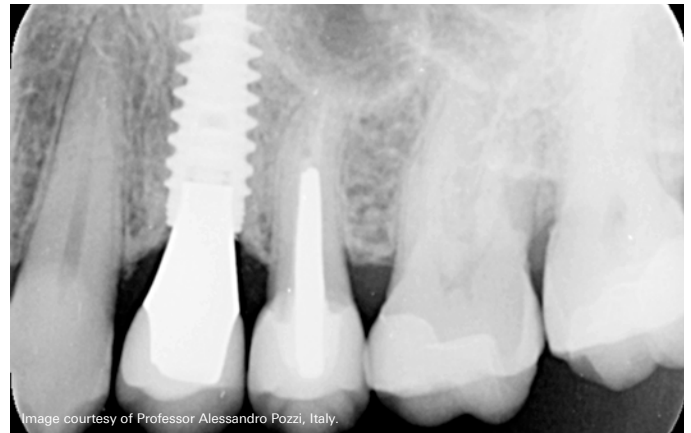
Radiological outcome with NobelActive at 1-year follow-up, showing stable bone.



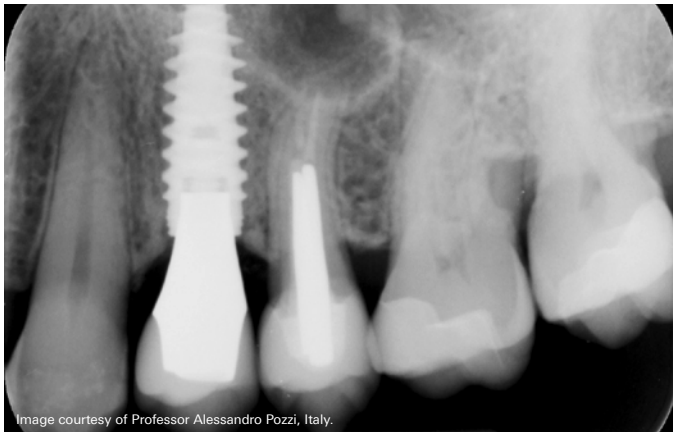
Radiological outcome with NobelActive at 7-year follow-up, showing stable bone.



Radiological outcome with NobelActive at 3-year follow-up, showing stable bone.



Radiological outcome with NobelActive at 9.5-year follow-up, showing bone overgrowth over time onto the implant platform.



Radiological outcome with NobelActive at 5-year follow-up, showing stable bone.

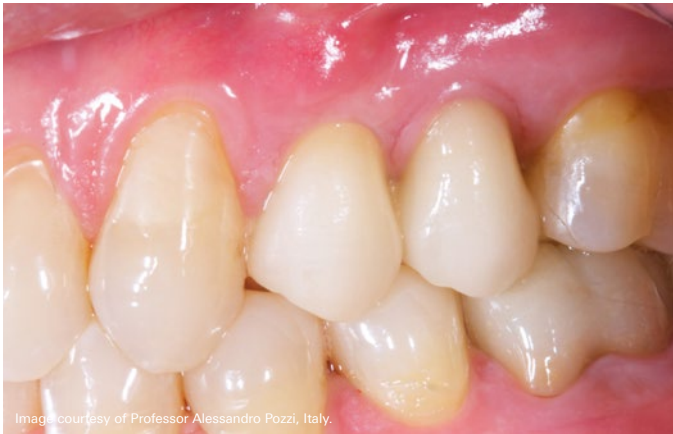

Image courtesy of Professor Alessandro Pozzi, Italy.

Clinical outcome with NobelActive at 1-year follow-up, showing healthy papilla.

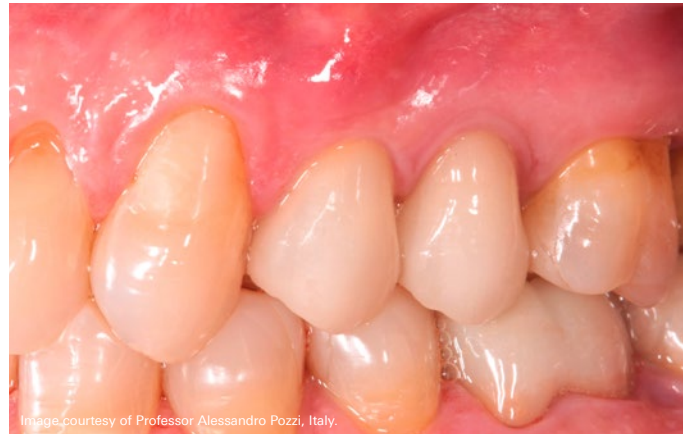

Image courtesy of Professor Alessandro Pozzi, Italy.

Clinical outcome with NobelActive at 7-year follow-up, showing healthy papilla.

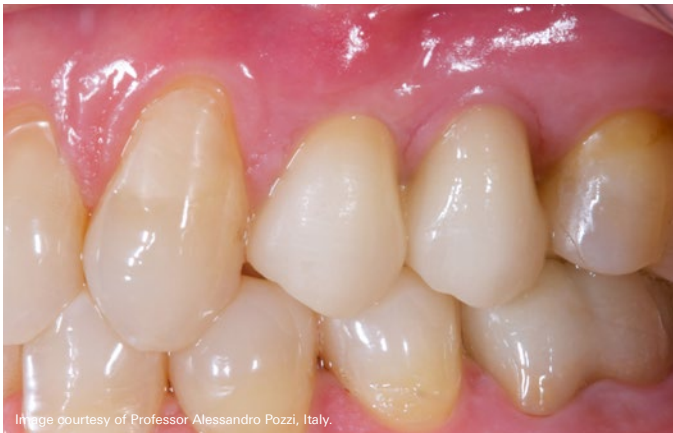

Image courtesy of Professor Alessandro Pozzi, Italy.

Clinical outcome with NobelActive at 3-year follow-up, showing healthy papilla.

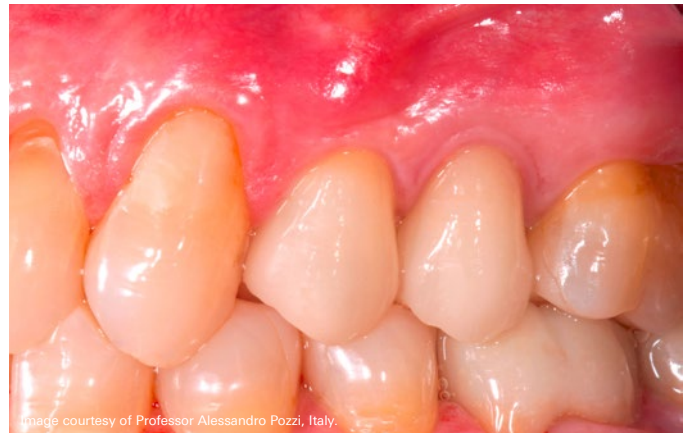

Image courtesy of Professor Alessandro Pozzi, Italy.

Clinical outcome with NobelActive at 9.5-year follow-up.

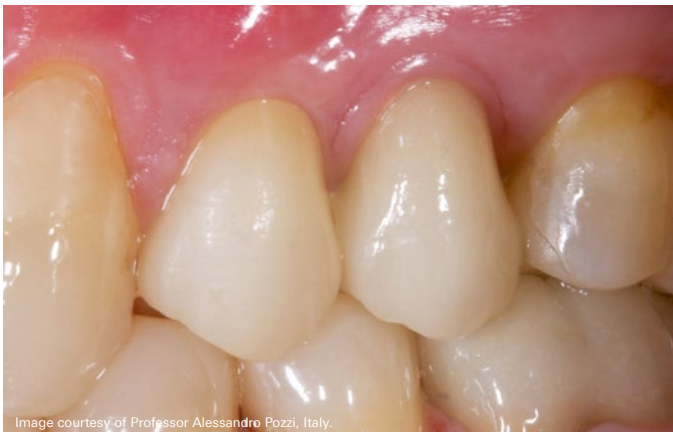

Image courtesy of Professor Alessandro Pozzi, Italy.

Clinical outcome with NobelActive at 5-year follow-up, showing healthy papilla.

Overview of studies

The following overview includes clinical studies using NobelActive implants. The studies are ordered by follow-up time.

Only peer-reviewed publications are listed. Meeting abstracts, reviews, single case reports, technique descriptions, and animal and in-vitro tests are excluded. The total number of implants and patients included in this overview is over 14,300 and 2,600 respectively, with mean implant survival rate of 98.5%.^A

Marginal bone level change is reported only for studies where implant level baseline is presented. For more information on these studies visit PubMed at pubmed.gov.

Reference	Mean follow-up time [years] ^B	Study type	Indication/ study focus	No. of implants ^C	No. of patients	Implant survival rate [%]	Mean change in marginal bone level (SD) [mm]
Jensen et al., 2016 ¹⁴	5	Retrospective	Fully edentulous, Maxilla, Immediate loading	158	39	94.9 ^D	NR
Li et al., 2017 ²¹	5	Prospective	Fully edentulous, Maxilla & mandible, Extraction, All-on-4	28	NR	100 ^D	NR
Cosyn et al., 2016 ⁷ Cosyn et al., 2013 ²²	5	Prospective	Single tooth, Anterior & posterior, Maxilla, Cement & screw, Extraction, Immediate loading	22	22	94.1 ^D	-0.19 (0.3)
Passos et al., 2016 ²³	5	Retrospective	Single tooth, Anterior, Maxilla & mandible	12	NR	100 ^D	NR
Babbush, 2015 ²⁴	4.5	Retrospective	Maxilla & mandible, Screw, Healed & extraction, All-on-4	5002	NR	98.1	NR
Pozzi et al., 2015 ²⁵	4.1	Prospective	Fully edentulous, Maxilla & mandible, Screw, Healed, Immediate loading, Guided surgery	62	NR	100	NR
Pozzi and Moy, 2014 ²⁶	3.7	Prospective	Partially edentulous, Maxilla, Posterior, Immediate loading, Guided surgery	37	NR	97.3	NR
Pozzi et al., 2015 ²⁷	3.5	Retrospective	Fully edentulous, Maxilla & mandible, Healed & extraction, Immediate loading, Guided surgery	85	NR	100 ^D	NR
Babbush et al., 2014 ²⁸	3.4	Retrospective	Maxilla & mandible, Anterior & posterior, Cement & screw, Fully edentulous, Healed & extraction, All-on-4	60	15	98.3 ^D	NR
Demanet et al., 2011 ²⁹	3	Retrospective	Maxilla & mandible, Anterior & posterior, Healed & extraction, 1-stage & 2-stage	466	172	99.1	-0.39 (NR)
De Santis et al., 2016 ³⁰	3	Prospective	Maxilla & mandible, Anterior & posterior, Screw, 2-stage, Delayed loading	144	62	98.6	-0.70 (0.5)
Arnhart et al., 2012 ¹⁷ Kielbassa et al., 2009 ¹⁸	3	Prospective	Maxilla & mandible, Anterior & posterior, Cement & screw, Healed, 1-stage, Immediate loading	117	117	96 ^D	-0.89 (1.7) ^D
Kolinski et al., 2014 ¹ McAllister et al., 2012 ³¹	3	Prospective	Maxilla & mandible, Anterior & posterior, Screw, Extraction, 1-stage, Immediate loading	60	55	98.3	+0.30 (1.6)
Pozzi et al., 2014 ² Pozzi et al., 2014 ³²	3	Prospective	Mandible, Posterior, Cement, Single-tooth, Healed, 2-stage, Early loading	44	34	100	-0.67 (0.4)

Reference	Mean follow-up time [years] ^b	Study type	Indication/ study focus	No. of implants ^c	No. of patients	Implant survival rate [%]	Mean change in marginal bone level (SD) [mm]
Chrcanovic et al., 2018³³	2.9	Retrospective	Maxilla & mandible, Anterior & posterior, Screw, Partially & fully edentulous	123	NR	NR	NR
Polizzi et al., 2016¹¹	2.4	Retrospective	Maxilla, Anterior & posterior, Healed & extraction, Immediate loading, Guided-Surgery	160	27	99.4	-0.58 (0.98)
De Vico et al., 2011³⁴	2.1	Prospective	Maxilla & mandible, Anterior & posterior, Screw, Fully edentulous, Healed & extraction, 1-stage, Immediate loading, Guided surgery, All-on-4	140	35	100	-0.72 @ 1 year (NR) ^d
Babbush and Brokloff, 2012¹⁵ Babbush et al., 2011³⁵	2	Retrospective	Maxilla & mandible, Anterior & posterior, Healed & extraction, 1-stage & 2-stage	1001	293	97.4	NR
Drago, 2016³⁶	2	Retrospective	Maxilla & mandible, Anterior & posterior, Screw, Fully edentulous, Healed & extraction, 1-stage, Immediate loading	774	130	99.5	NR
Drago, 2017³⁷	2	Retrospective	Maxilla & mandible, Anterior & posterior, Screw, Fully edentulous, Healed & extraction, Immediate loading, All-on-4	770	128	99.5	NR
Drago, 2016³⁸	2	Retrospective	Maxilla & mandible, Anterior & posterior, Screw, Fully edentulous, Healed & extraction, 1-stage, Immediate loading, All-on-4	766	129	99.5	NR
Orentlicher et al., 2014³⁹	2	Retrospective	Maxilla & mandible, Anterior & posterior, Healed & extraction, Guided surgery	121	NR	95.9	NR
Ganeles et al., 2017⁸	2	Prospective	Single-arm, single center, Maxilla, Anterior & posterior, Single-tooth, Extraction, 1-stage	15	15	100	+0.83 (2.73)
Aires and Berger, 2016⁴⁰	1.6	Retrospective	Maxilla & mandible, Anterior & posterior, Screw, Fully edentulous, Healed & extraction, 1-stage & 2-stage, Guided surgery	1657	228	99.4	NR
Younes et al., 2016⁴¹	1.6	Retrospective	Maxilla, Posterior, Cement & screw, 1-stage & 2-stage	165	57	98.2 ^d	NR
Babbush et al., 2016⁴²	1.3	Retrospective	Maxilla & mandible, Anterior & posterior, Fully edentulous, Healed & extraction, 1-stage, Immediate loading, All-on-4	856	169	99.8	-0.14 (0.6)
MacLean et al., 2016⁴³	1.3	Retrospective	Maxilla & mandible, Anterior, Cement & screw, Single-tooth, Healed & extraction, 1-stage & 2-stage	44	34	96.4	-0.36 (0.9)
Gultekin et al., 2013³	1.25	Prospective	Maxilla & mandible, Anterior & posterior, Cement, Partially edentulous, Healed, 2-stage, Delayed loading, Guided surgery	43	NR	100	-0.35 (0.1)
Babbush and Kanawati, 2015⁴⁴	1.0	Retrospective	Maxilla & mandible, Anterior & posterior, Healed & extraction	262	65	98.1	NR
Yamada et al., 2015⁴	1	Prospective	Maxilla, Anterior & posterior, Screw, Fully edentulous, Healed, 1-stage, Immediate loading, Guided surgery	290	50	98.6	-0.32 (0.4)
Babbush et al., 2013¹³	1	Retrospective	Maxilla & mandible, Anterior & posterior, Fully edentulous, Healed & extraction, 1-stage & 2-stage	227	53	98.7	NR
Esposito et al., 2017⁴⁵	1	Prospective	Maxilla & mandible, Single-tooth, Immediate loading, Immediate-delayed & delayed loading	210	210	95.7	-0.28 (0.16) ^d
Galindo and Butura, 2012⁴⁶	1	Retrospective	Mandible, Anterior & posterior, Screw, Fully edentulous, Mixed, 1-stage, Immediate loading, Guided surgery, All-on-4	60	183	100 ^d	≤-1.0 (NR)

Reference	Mean follow-up time [years] ^B	Study type	Indication/ study focus	No. of implants ^C	No. of patients	Implant survival rate [%]	Mean change in marginal bone level (SD) [mm]
Cosyn et al., 2015⁴⁷	1	Prospective	Maxilla, Anterior & posterior, Screw, Single-tooth, Healed, 1-stage, Delayed loading	47	47	100	-0.48 (0.5)
Slagter et al., 2015⁴⁸	1	Prospective	Maxilla, Anterior & posterior, Cement & screw, Single-tooth, Extraction, 1-stage & 2-stage	40	40	100	-0.70 (NR) ^D
Slagter et al., 2016⁴⁹	1	Prospective	Maxilla, Anterior, Cement & screw, Single-tooth, Healed & extraction, 2-stage, Delayed loading	40	40	100	-0.53 (NR) ^D
Cristalli et al., 2015⁵⁰	1	Prospective	Maxilla & mandible, Anterior & posterior, Cement, Single-tooth, Extraction, 1-stage, Immediate loading	25	24	92	-0.33 (NR) ^D
Rokn et al., 2015⁵¹	1	Prospective	Mandible, Posterior, Single-tooth	25	NR	100 ^D	-0.68 (0.5)
Antoun et al., 2017⁵²	1	Retrospective	Maxilla & mandible, Anterior & posterior, Cement & screw, Single-tooth, Fully & partially edentulous, 1-stage & 2-stage, Immediate loading, Early & delayed loading	134	NR	97.0	NR
Zuiderveld et al., 2018⁵³	1	Retrospective	Maxilla, Anterior, Screw, Single-tooth, Extraction, 1-stage, Immediate loading	60	60	96.7	-0.01 ^D
Kolinski et al., 2018²⁰	1	Prospective	Maxilla & mandible, Anterior, Cement & screw, Single-tooth, Healed & Extraction, Immediate loading	82	71	96.7	-0.25

Source: Nobel Biocare data on file (REP 134625/000/05), updated with Nobel Biocare database and PubMed search results for publications in 2016 – February 2018.

A: Arithmetic mean weighted by number of initially placed implants (implant survival rate).

B: Where the mean follow-up time was not available the reported follow-up time was used (minimum one-year follow-up). Last radiological follow-up for mean marginal bone level change may differ from the overall study follow-up.

C: Minimum 10 implants.

D: The percentage of surviving implants/prostheses or MBL was calculated.

NR: Not reported.

References

- Kolinski ML, Cherry JE, McAllister BS, et al. Evaluation of a variable-thread tapered implant in extraction sites with immediate temporization: a 3-year multi-center clinical study. *J Periodontol* 2014;85(3):386–394.
- Pozzi A, Tallarico M, Moy PK. Three-year post-loading results of a randomised, controlled, split-mouth trial comparing implants with different prosthetic interfaces and design in partially posterior edentulous mandibles. *Eur J Oral Implantol* 2014;7(1):47–61.
- Gultekin BA, Gultekin P, Leblebicioglu B, Basegmez C, Yalcin S. Clinical evaluation of marginal bone loss and stability in two types of submerged dental implants. *Int J Oral Maxillofac Implants* 2013;28(3):815–823.
- Yamada J, Kori H, Tsukiyama Y, et al. Immediate loading of complete-arch fixed prostheses for edentulous maxillae after flapless guided implant placement: a 1-year prospective clinical study. *Int J Oral Maxillofac Implants* 2015;30(1):184–193.
- Glauser R, Portmann M, Ruhstaller P, et al. Stability measurements of immediately loaded machined and oxidized implants in the posterior maxilla. A comparative clinical study using resonance frequency analysis. *Appl Osseointegrat Res* 2011;2:27–29.
- Zipprich H, Miatke S, Hmaidouch R, Lauer HC. A new experimental design for bacterial microleakage investigation at the implant-abutment interface: an in vitro study. *Int J Oral Maxillofac Implants* 2016;31(1):37–44.
- Cosyn J, Eghbali A, Hermans A, et al. A 5-year prospective study on single immediate implants in the aesthetic zone. *J Clin Periodontol* 2016;43(8):702–709.
- Ganeles J, Norkin FJ, Zfaz S. Single-tooth implant restorations in fresh extraction sockets of the maxillary esthetic zone: two-year results of a prospective cohort study. *Int J Periodontics Restorative Dent* 2017;37(2):e154–e162.
- Polizzi G, Cecchini P, Pasini E. 6-year retrospective analysis of variable-thread tapered implants placed in demanding situations. *Clin Oral Impl Res* 2017;28:229.
- Karl M, Irastorza-Landa A. Does implant design affect primary stability in extraction sites? *Quintessence Int* 2017;48(3):219–224.
- Polizzi G, Cantoni T, Pasini E, Tallarico M. Immediate loading of variable-thread expanding tapered-body implants placed into maxillary post-extraction or healed sites using a guided surgery approach: An up-to-five-year retrospective analysis. *J Oral Science Rehabilitation* 2016;2(3):50–60.
- Irinakis T, Wiebe C. Clinical evaluation of the NobelActive implant system: a case series of 107 consecutively placed implants and a review of the implant features. *J Oral Implantol* 2009;35(6):283–288.
- Babbush CA, Kanawati A, Brokloff J. A new approach to the all-on-four treatment concept using narrow platform NobelActive implants. *J Oral Implantol* 2013;39(3):314–325.
- Jensen OT, Ringeman JL, Adams MW, Gregory N. Reduced arch length as a factor for four implant immediate function in the maxilla: A technical note and report of 39 patients followed for 5 years. *J Oral Maxillofac Surg* 2016;74(12):2379–2384.
- Babbush CA, Brokloff J. A single-center retrospective analysis of 1001 consecutively placed NobelActive implants. *Implant Dent* 2012;21(1):28–35.
- Todisco M. All-on-4 with NobelActive implants: 3-year clinical and radiological follow-up. *Clin Oral Impl Res* 2016;27(Suppl 13):225.
- Arnhart C, Kielbassa AM, Martinez-de Fuentes R, et al. Comparison of variable-thread tapered implant designs to a standard tapered implant design after immediate loading. A 3-year multicentre randomised controlled trial. *Eur J Oral Implantol* 2012;5(2):123–136.
- Kielbassa AM, Martinez-de Fuentes R, Goldstein M, et al. Randomized controlled trial comparing a variable-thread novel tapered and a standard tapered implant: interim one-year results. *J Prosthet Dent* 2009;101(5):293–305.
- Villa R, Villa G, Del Fabbro M. OnlyOne: a novel technique for immediate post-extraction screw-retained partial and full-arch rehabilitation. A 3-year follow-up retrospective clinical study. *Int J Periodontics Restorative Dent* 2018 (in press).
- Kolinski M, Hess P, Leziy S, et al. Immediate provisionalization in the esthetic zone: 1-year interim results from a prospective single-cohort multicenter study evaluating 3.0-mm-diameter tapered implants. *Clin Oral Investig* 2018; doi:10.1007/s00784-017-2329-2.
- Li S, Di P, Zhang Y, Lin Y. Immediate implant and rehabilitation based on All-on-4 concept in patients with generalized aggressive periodontitis: A medium-term prospective study. *Clin Implant Dent Relat Res* 2017;19(3):559–571.
- Cosyn J, De Bruyn H, Cleymaet R. Soft tissue preservation and pink aesthetics around single immediate implant restorations: a 1-year prospective study. *Clin Implant Dent Relat Res* 2013;15(6):847–857.
- Passos SP, Linke B, Larjava H, French D. Performance of zirconia abutments for implant-supported single-tooth crowns in esthetic areas: a retrospective study up to 12-year follow-up. *Clin Oral Implants Res* 2016;27(1):47–54.
- Babbush CA. A multi-center review of 53,802 implants utilized in over 13,000 jaws for All-On-4 reconstruction. *AO* 2015;108(4):28–31.
- Pozzi A, Tallarico M, Barlattani A. Monolithic lithium disilicate full-contour crowns bonded on CAD/CAM zirconia complete-arch implant bridges with 3 to 5 years of follow-up. *J Oral Implantol* 2015;41(3):450–458.
- Pozzi A, Moy PK. Minimally invasive transcrestal guided sinus lift (TGSL): a clinical prospective proof-of-concept cohort study up to 52 months. *Clin Implant Dent Relat Res* 2014;16(4):582–593.
- Pozzi A, Holst S, Fabbri G, Tallarico M. Clinical reliability of CAD/CAM cross-arch zirconia bridges on immediately loaded implants placed with computer-assisted/template-guided surgery: a retrospective study with a follow-up between 3 and 5 years. *Clin Implant Dent Relat Res* 2015;17(Suppl 1):e86–e96.
- Babbush CA, Kanawati A, Kotsakis GA, Hinrichs JE. Patient-related and financial outcomes analysis of conventional full-arch rehabilitation versus the All-on-4 Concept: a cohort study. *Implant Dent* 2014;23(2):218–224.
- Demant M, Merheb J, Simons WF, Leroy R, Quirynen M. The outcome of a novel tapered implant in a private practice limited to Periodontology. *Le Dentiste* 2011;426:22–25.
- De Santis D, Cucchi A, Rigoni G, Longhi C, Nocini PF. Relationship between primary stability and crestal bone loss of implants placed with high insertion torque: a 3-year prospective study. *Int J Oral Maxillofac Implants* 2016;31(5):1126–1134.
- McAllister BS, Cherry JE, Kolinski ML, et al. Two-year evaluation of a variable-thread tapered implant in extraction sites with immediate temporization: a multicenter clinical trial. *Int J Oral Maxillofac Implants* 2012;27(3):611–618.
- Pozzi A, Agliardi E, Tallarico M, Barlattani A. Clinical and radiological outcomes of two implants with different prosthetic interfaces and neck configurations: randomized, controlled, split-mouth clinical trial. *Clin Implant Dent Relat Res* 2014;16(1):96–106.
- Chrcanovic BR, Jenö K, Albrektsson T, et al. Factors influencing the fracture of dental implants. *Clin Implant Dent Relat Res* 2018;20(1):58–67.
- De Vico G, Bonino M, Spinelli D, et al. Rationale for tilted implants: FEA considerations and clinical reports. *Oral Implantol (Rome)* 2011;4(3-4):23–33.
- Babbush C, Kutsko G, Brokloff J. The All-on-Four Immediate Function treatment concept with NobelActive implants – A retrospective study. *J Oral Implantol* 2011;37(4):431–445.
- Drago C. Ratios of cantilever lengths and anterior-posterior spreads of definitive hybrid full-arch, screw-retained prostheses: results of a clinical study. *J Prosthodont* 2016; doi: 10.1111/jopr.12519.
- Drago C. Cantilever lengths and anterior-posterior spreads of interim, acrylic resin, full-arch screw-retained prostheses and their relationship to prosthetic complications. *J Prosthodont* 2017;26(6):502–507.
- Drago C. Frequency and type of prosthetic complications associated with interim, immediately loaded full-arch prostheses: a 2-year retrospective chart review. *J Prosthodont* 2016;25(6):433–439.
- Orentlicher G, Horowitz A, Goldsmith D, et al. Cumulative survival rate of implants placed “fully guided” using CT-guided surgery: a 7-year retrospective study. *Compend Contin Educ Dent* 2014;35(8):590–597.
- Aires I, Berger J. Planning implant placement on 3D stereolithographic models applied with immediate loading of implant-supported hybrid prostheses after multiple extractions: a case series. *Int J Oral Maxillofac Implants* 2016;31(1):172–178.
- Younes F, Eghbali A, De Troyer S, et al. Marginal and apical bone stability after staged sinus floor augmentation using bone condensing implants with variable-thread design: a two-dimensional analysis. *Int J Oral Maxillofac Surg* 2016;45(9):1135–1141.
- Babbush CA, Kanawati A, Kotsakis GA. Marginal bone stability around tapered, platform-shifted implants placed with an immediately loaded four-implant-supported fixed prosthetic concept: a cohort study. *Int J Oral Maxillofac Implants* 2016;31(3):643–650.
- MacLean S, Hermans M, Villata L, et al. A retrospective multicenter case series evaluating a novel 3.0-mm expanding tapered body implant for the rehabilitation of missing incisors. *Quintessence Int* 2016;47(4):297–306.

References

44. Babbush CA, Kanawati A. Clinical evaluation of 262 osseointegrated implants placed in sites grafted with calcium phosphosilicate putty: a retrospective study. *J Oral Implantol* 2015;41(1):63–69.
45. Esposito M, Zucchelli G, Cannizzaro G, et al. Immediate, immediate-delayed (6 weeks) and delayed (4 months) post-extractive single implants: 1-year post-loading data from a randomised controlled trial. *Eur J Oral Implantol* 2017;10(1):11–26.
46. Galindo DF, Butura CC. Immediately loaded mandibular fixed implant prostheses using the all-on-four protocol: a report of 183 consecutively treated patients with 1 year of function in definitive prostheses. *Int J Oral Maxillofac Implants* 2012;27(3):628–33.
47. Cosyn J, Pollaris L, Van der Linden F, De Bruyn H. Minimally invasive single implant treatment (M.I.S.I.T.) based on ridge preservation and contour augmentation in patients with a high aesthetic risk profile: one-year results. *J Clin Periodontol* 2015;42(3):398–405.
48. Slagter KW, Meijer HJ, Bakker NA, Vissink A, Raghoobar GM. Feasibility of immediate placement of single-tooth implants in the aesthetic zone: a 1-year randomized controlled trial. *J Clin Periodontol* 2015;42(8):773–782.
49. Slagter KW, Meijer HJ, Bakker NA, Vissink A, Raghoobar GM. Immediate single-tooth implant placement in bony defects in the esthetic zone: a 1-year randomized controlled trial. *J Periodontol* 2016;87(6):619–629.
50. Cristalli MP, Marini R, La Monaca G, et al. Immediate loading of post-extractive single-tooth implants: a 1-year prospective study. *Clin Oral Implants Res* 2015;26(9):1070–1079.
51. Rohn AR, Badri S, Rasouli Ghahroudi AA, et al. Comparison of bone loss around bone platform shift and non-bone platform shift implants after 12 months. *J Dent (Tehran)* 2015;12(3):183–187.
52. Antoun H, Karouni M, Abitbol J, et al. A retrospective study on 1592 consecutively performed operations in one private referral clinic. Part I: Early inflammation and early implant failures. *Clin Implant Dent Relat Res* 2017;19(3):404–412.
53. Zuiderveld EG, Meijer HJA, den Hartog L, et al. Effect of connective tissue grafting on peri-implant tissue in single immediate implant sites: A RCT. *J Clin Periodontol* 2018;45(2):253–264.

