

All-on-4[®] treatment concept

Mandible – TiUltra™ & Xeal™

Dr. Philip M. Walton





Patient

78 years, female

Clinical situation

Failing mandibular dentition

Surgical solution

Full arch clearance + same day
rehabilitation with All-on-4® treatment
concept

Restorative solution

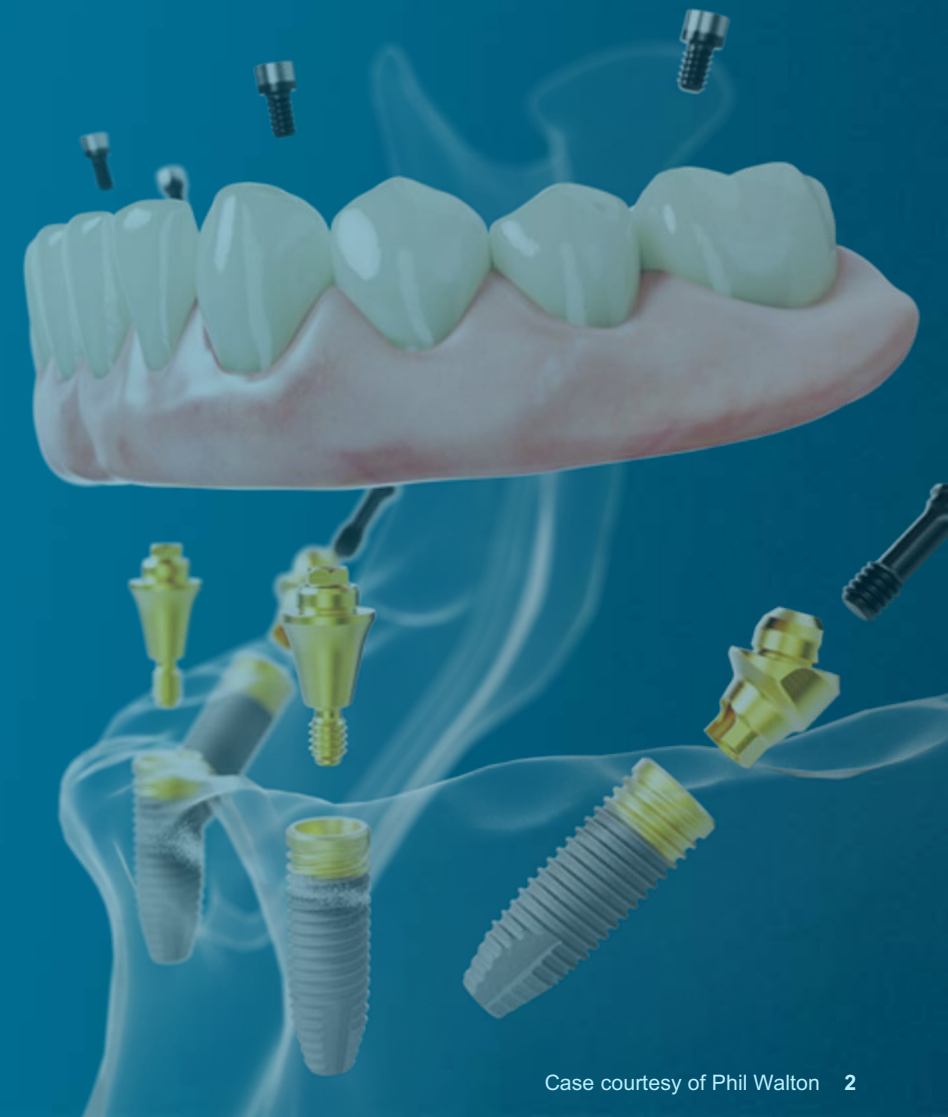Immediate PMMA temporary
Definitive zirconia

Surgery date

July 2019

Total treatment time

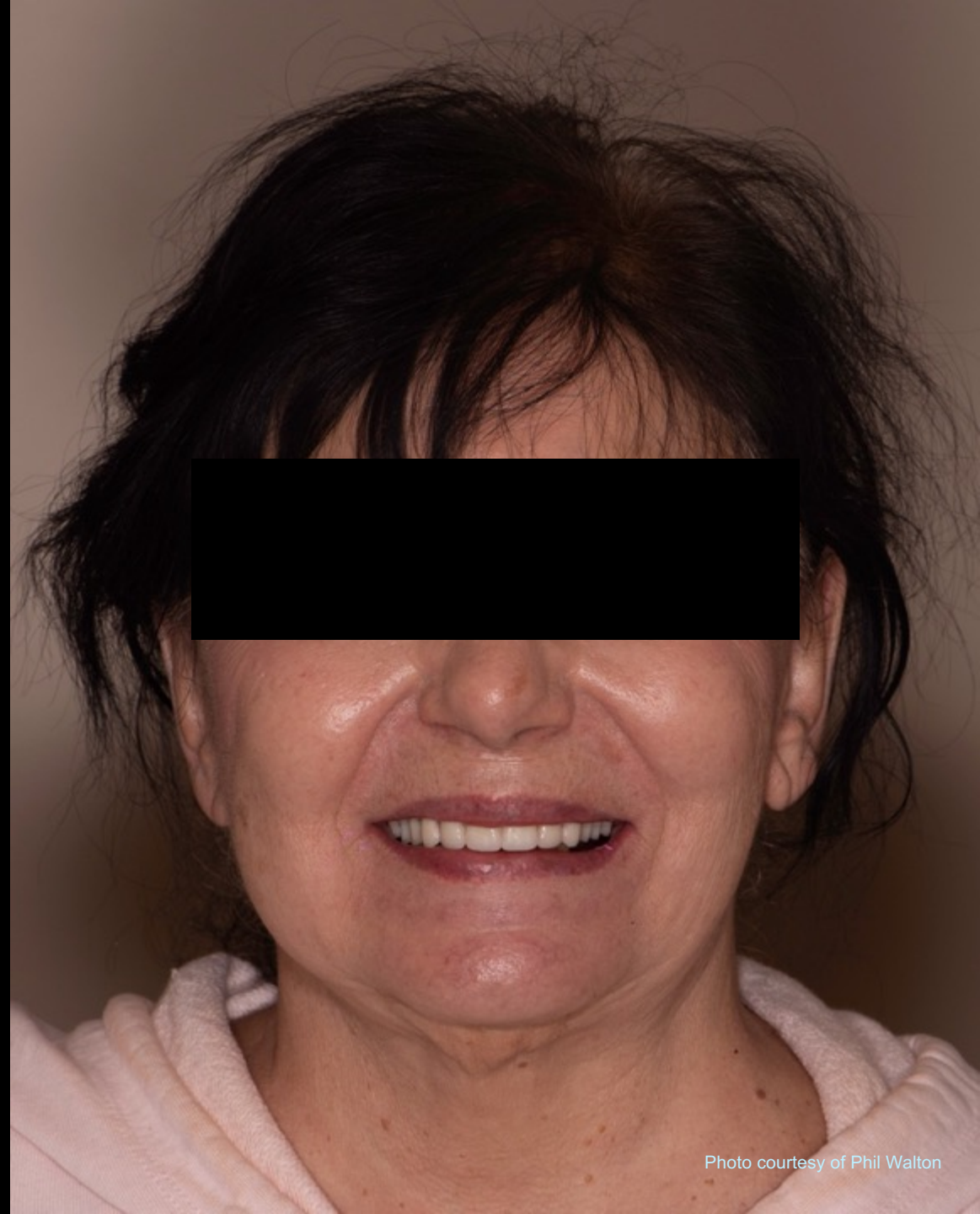18 months



“I hated my teeth since I was a teenager and as far as I can remember they were fraught with problems – constant cavities, fillings, root canals, extractions.

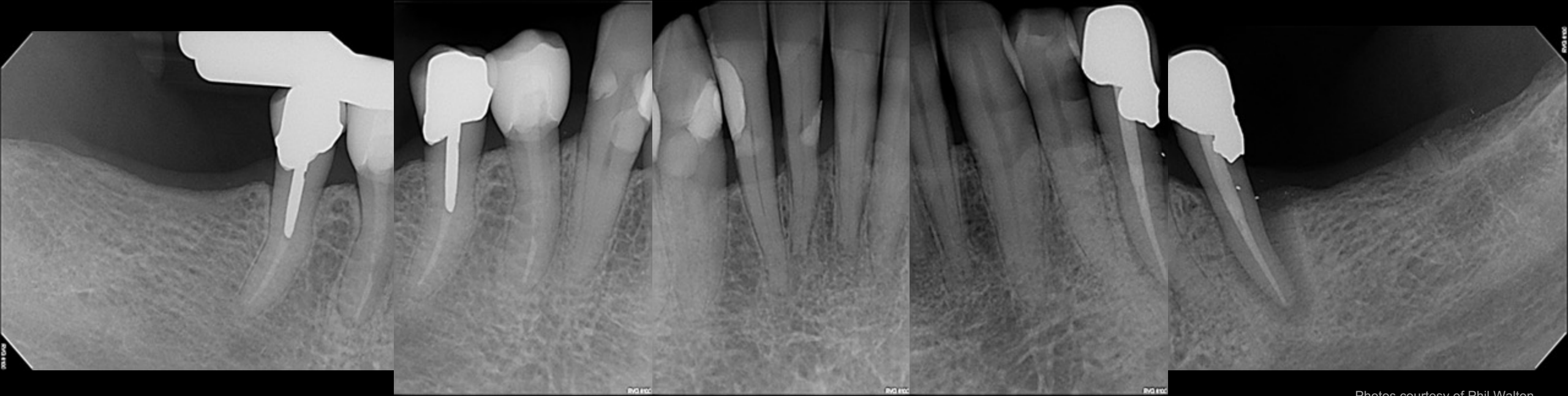
The pain associated with my teeth and the recurrent issues were a source of stress.

When I lost my back lower teeth the dentist attempted to use a denture that made me gag, was ill-fitting and uncomfortable – I simply could not wear it and as a result my chewing/function was impacted.”



Initial presentation

Initial presentation



Photos courtesy of Phil Walton

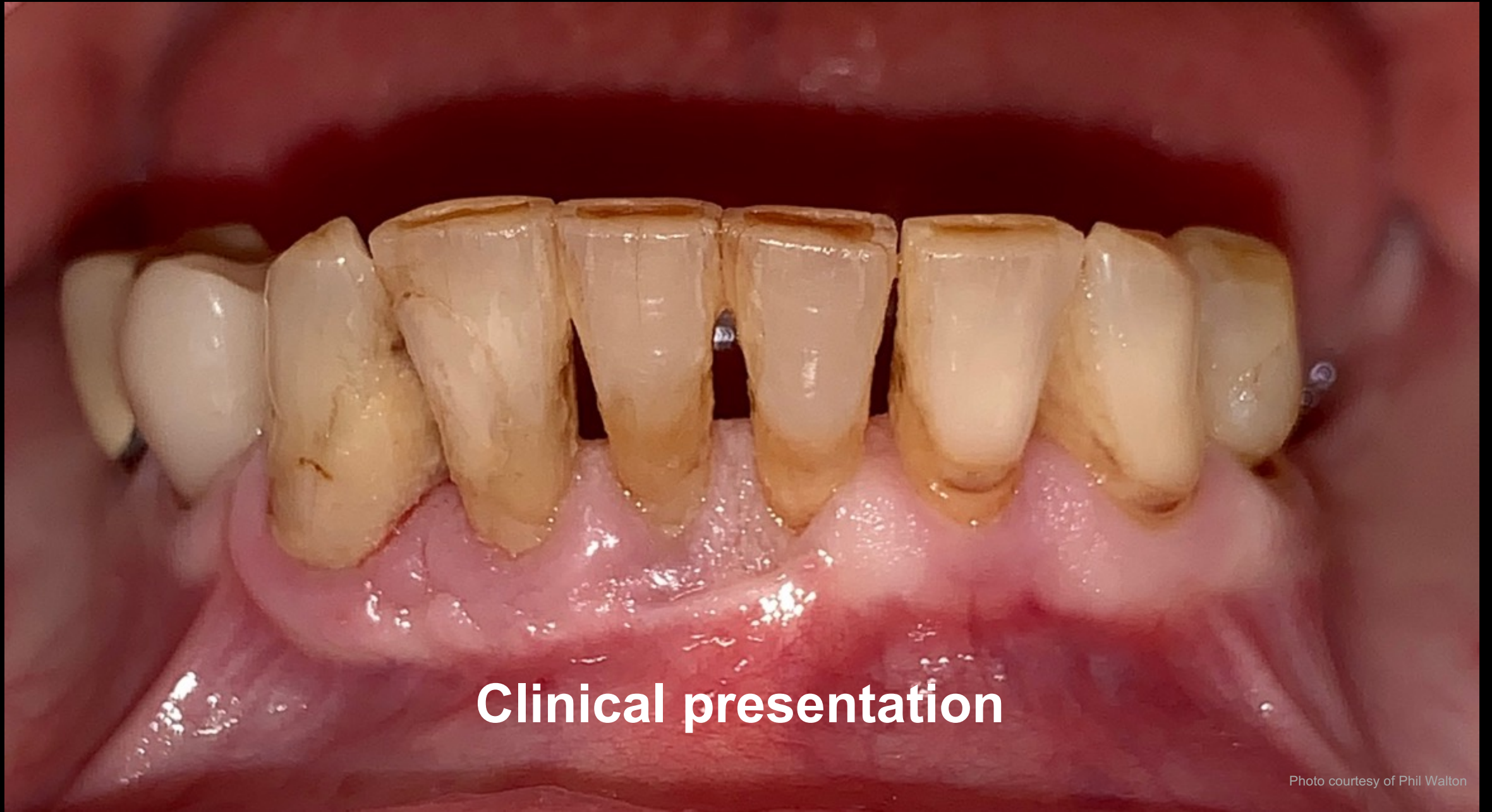Day of surgery

Day of surgery



Photo courtesy of Phil Walton

Day of surgery



Clinical presentation

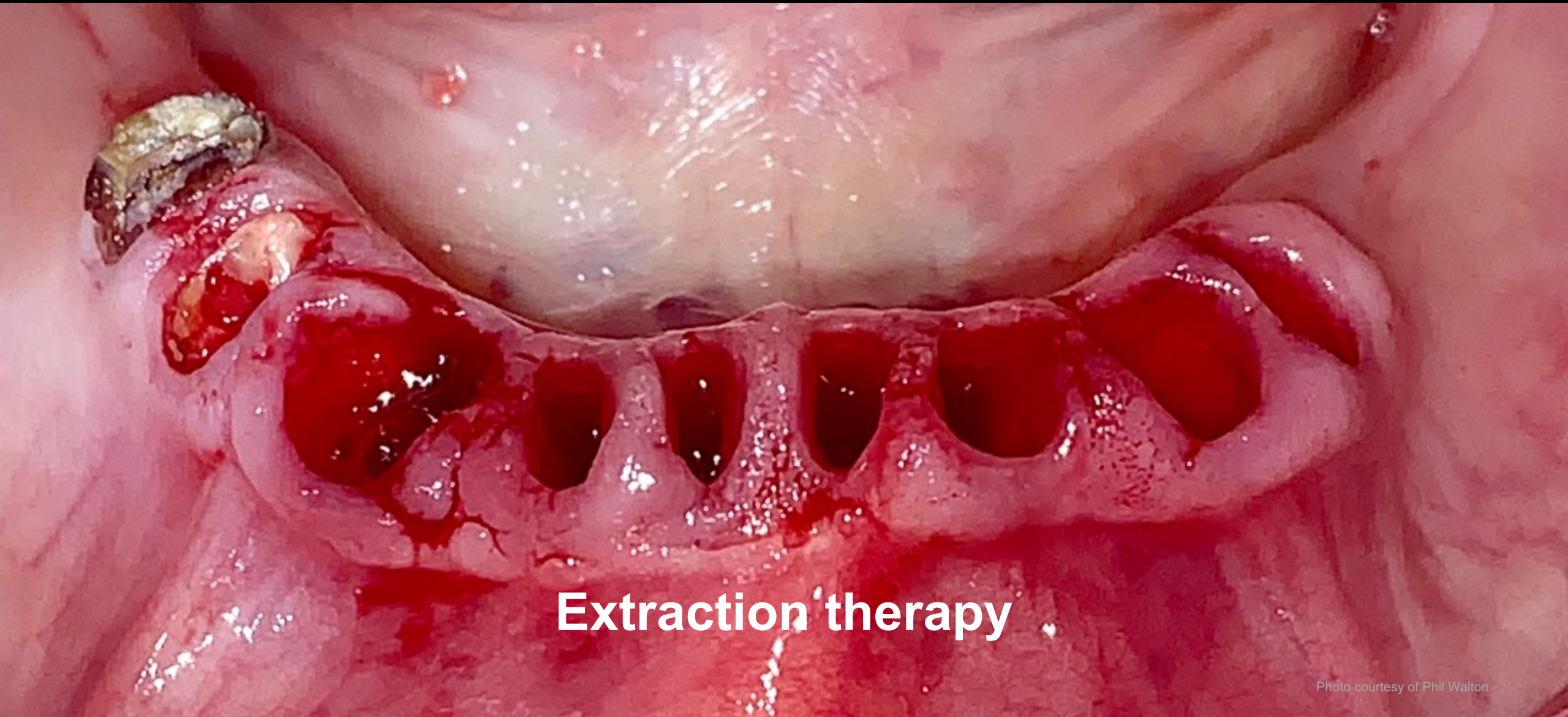
Day of surgery



VDO measurement

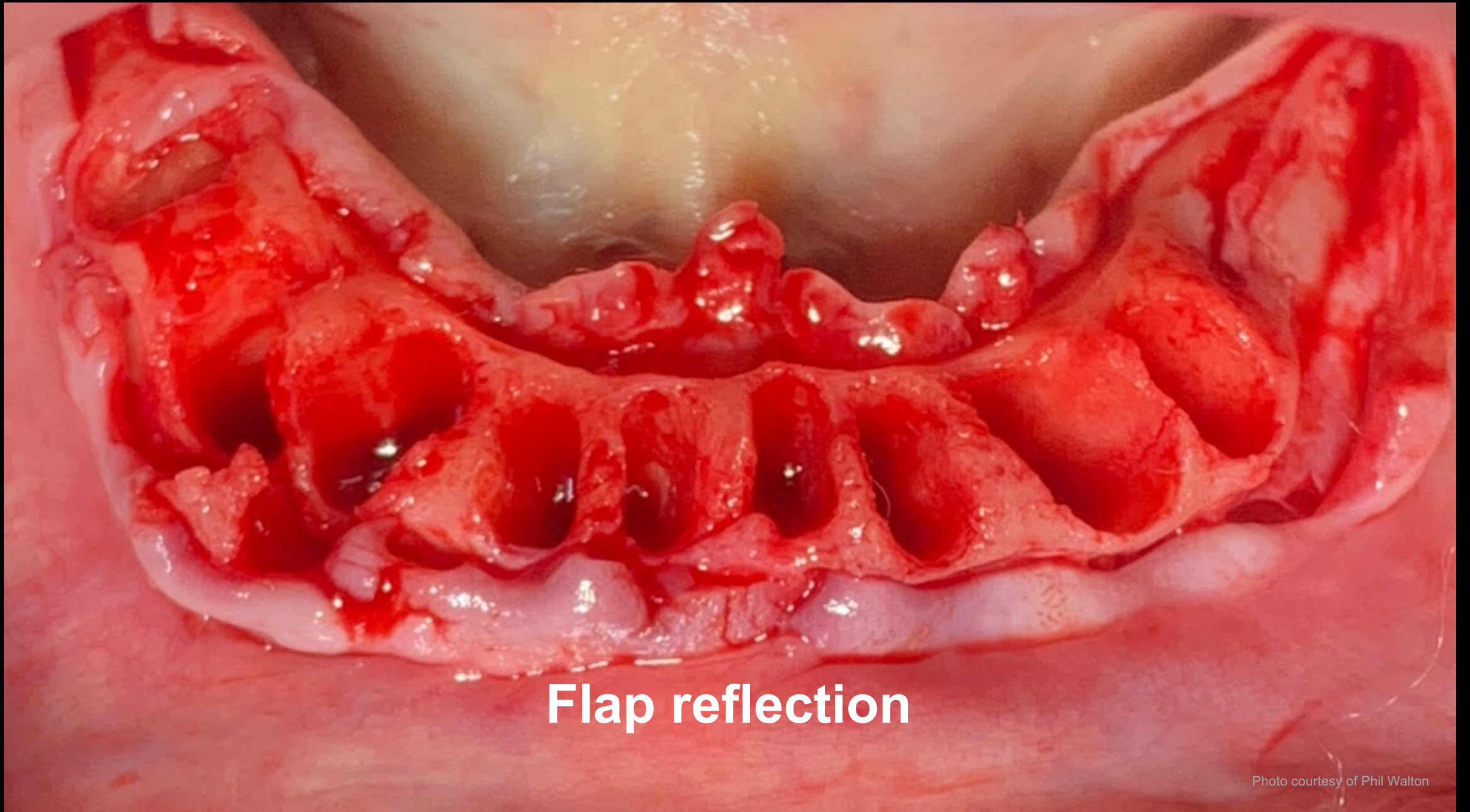
Photo courtesy of Phil Walton

Day of surgery



Extraction therapy

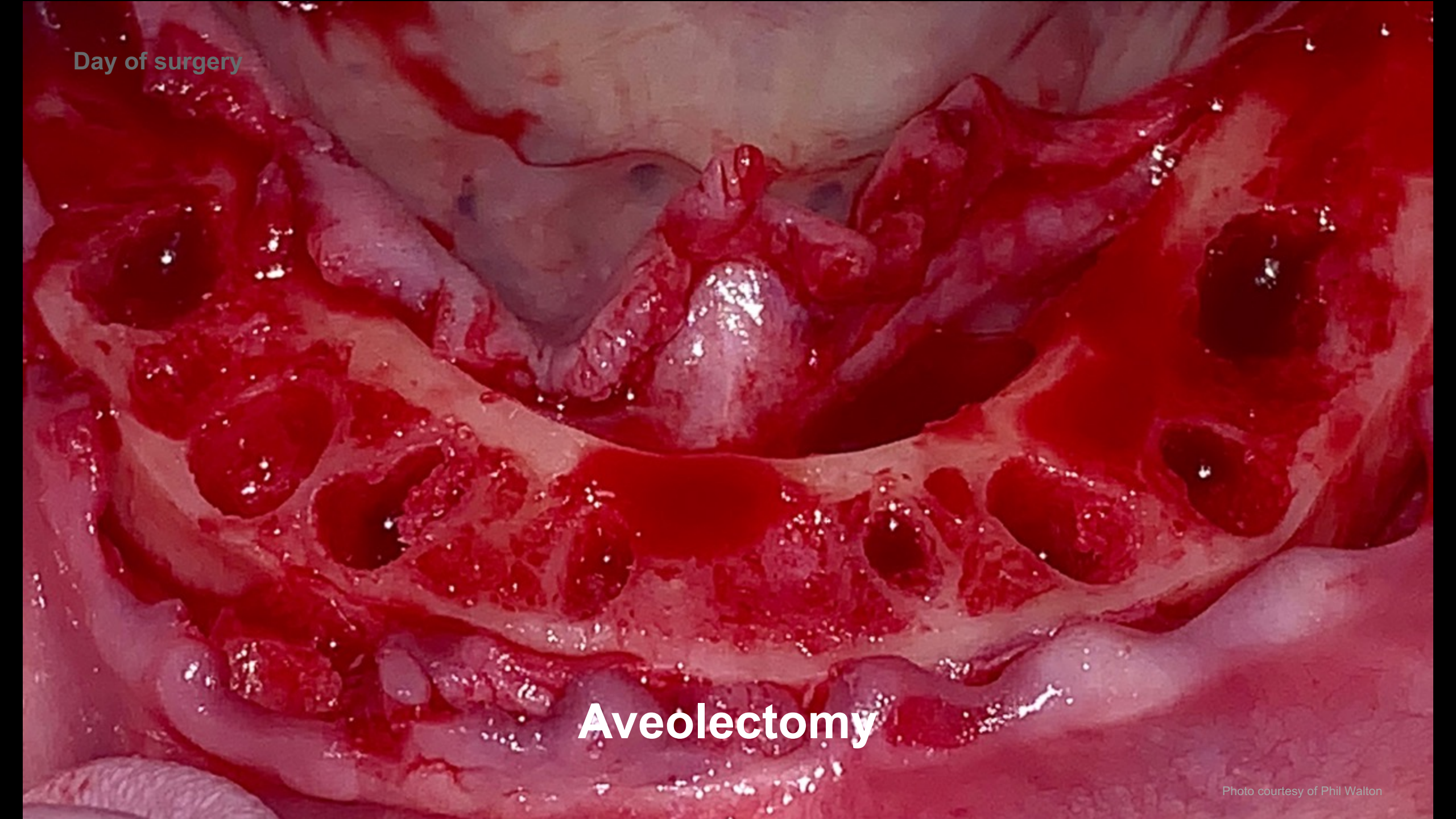
Day of surgery



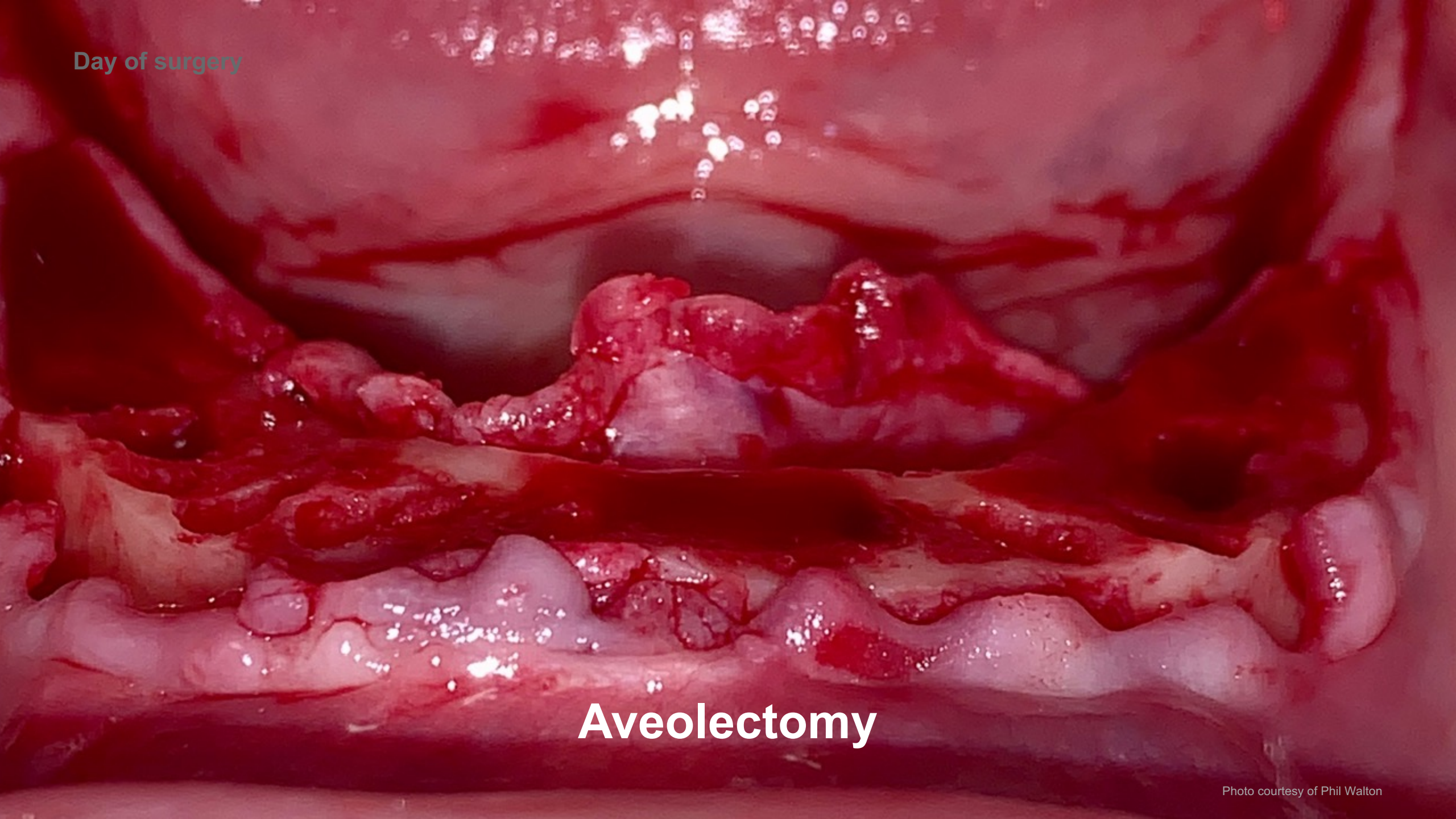
Flap reflection

Day of surgery

Aveolectomy

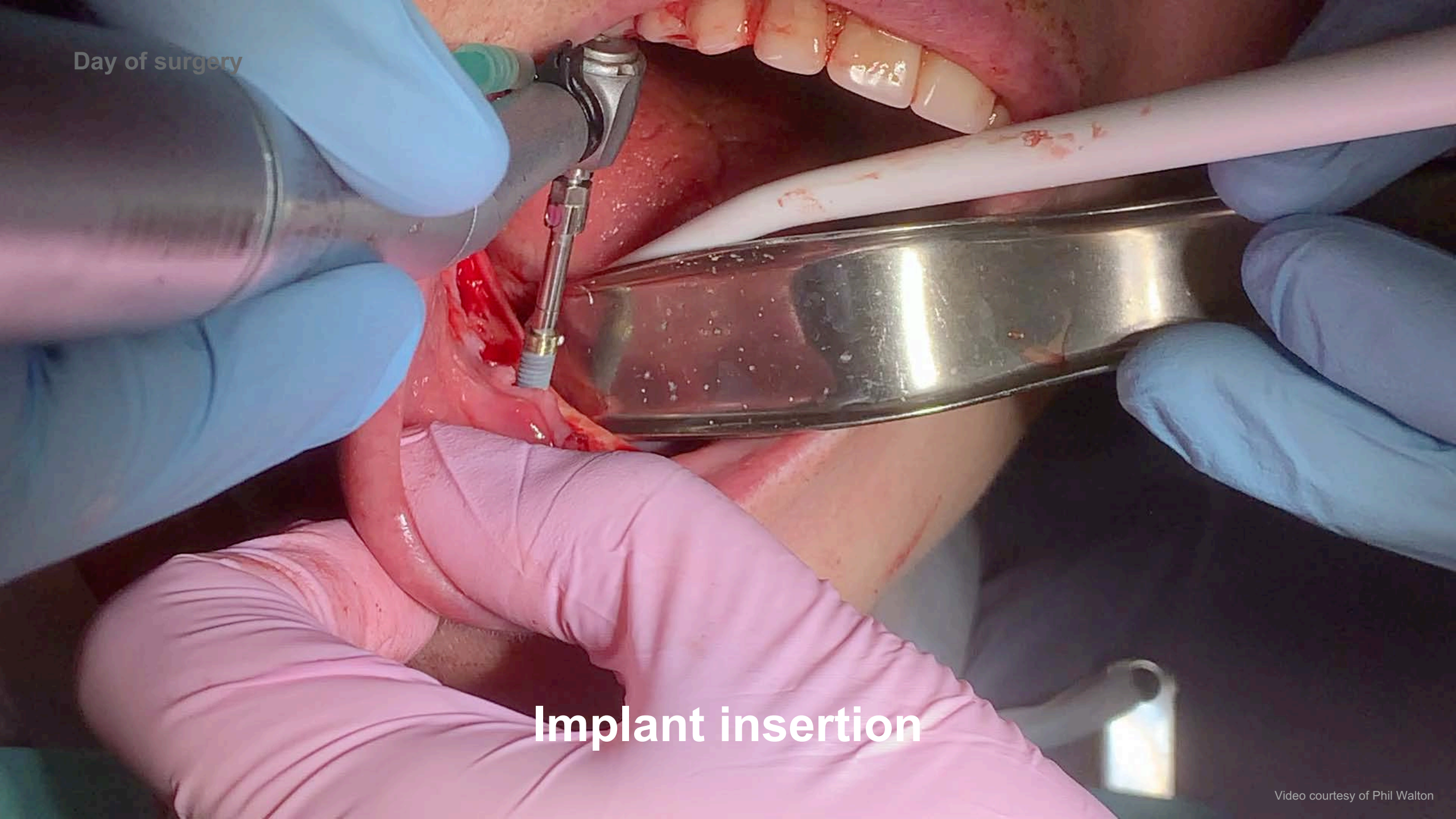


Day of surgery



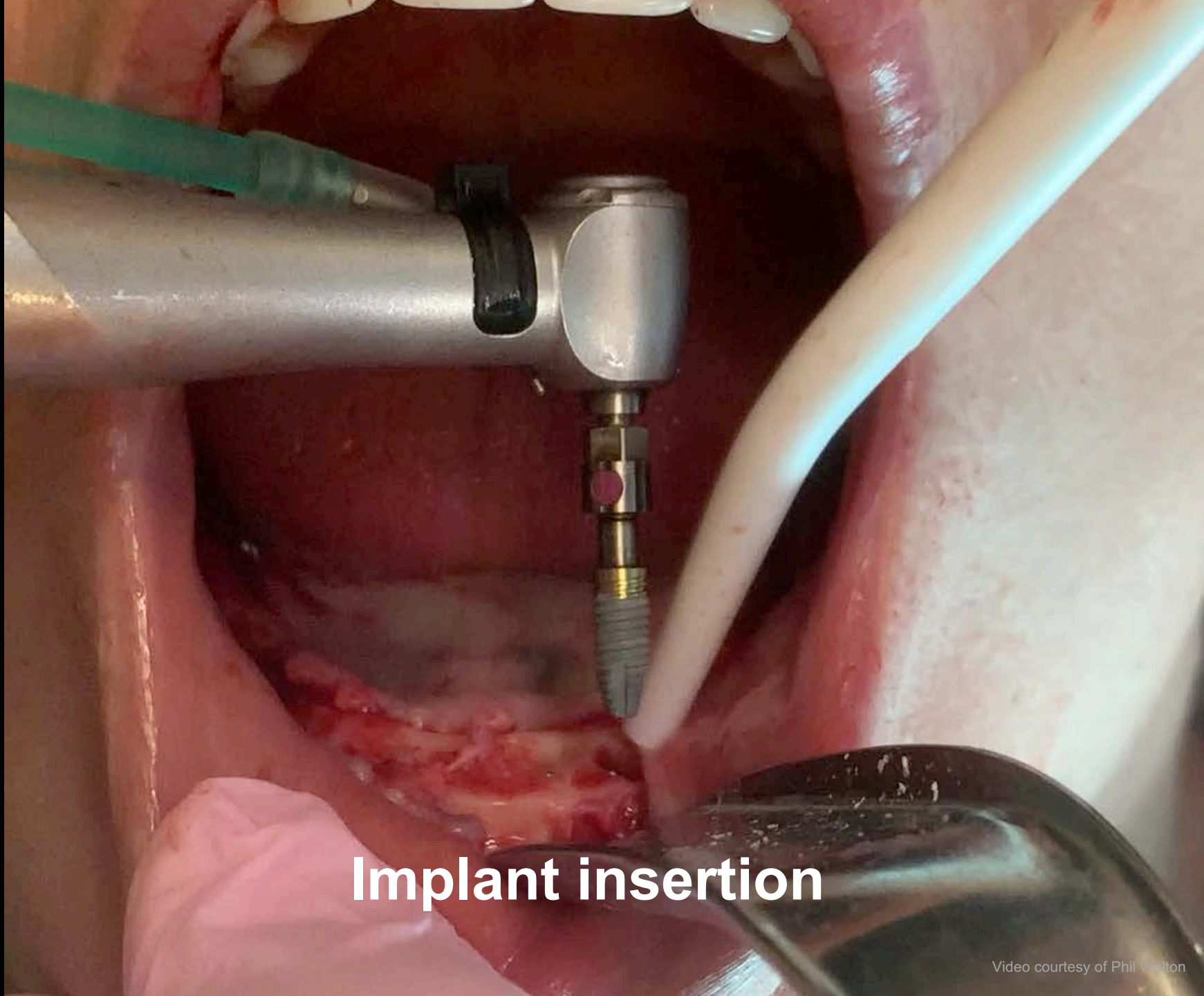
Aveolectomy

Day of surgery



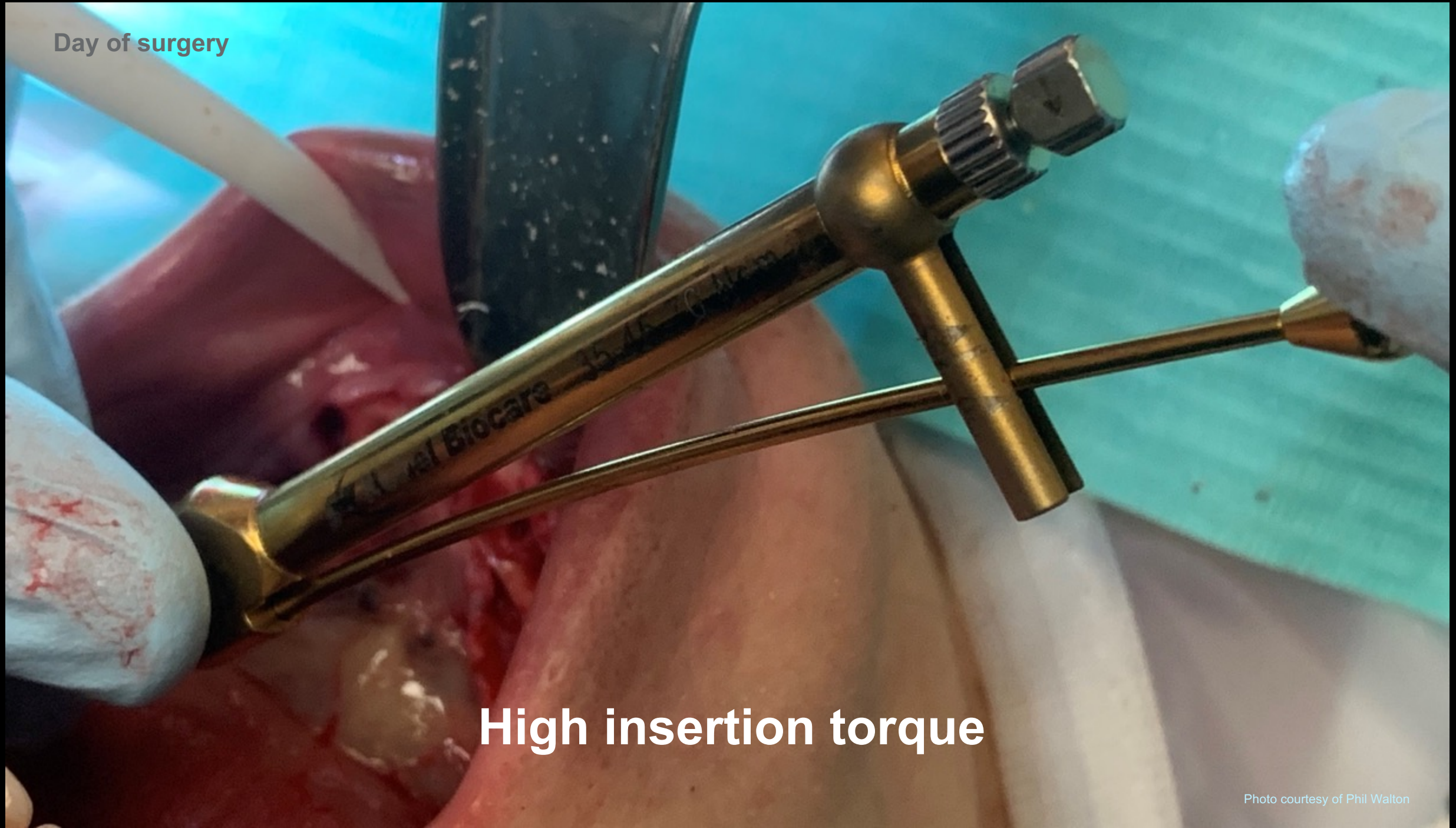
Implant insertion

Day of surgery



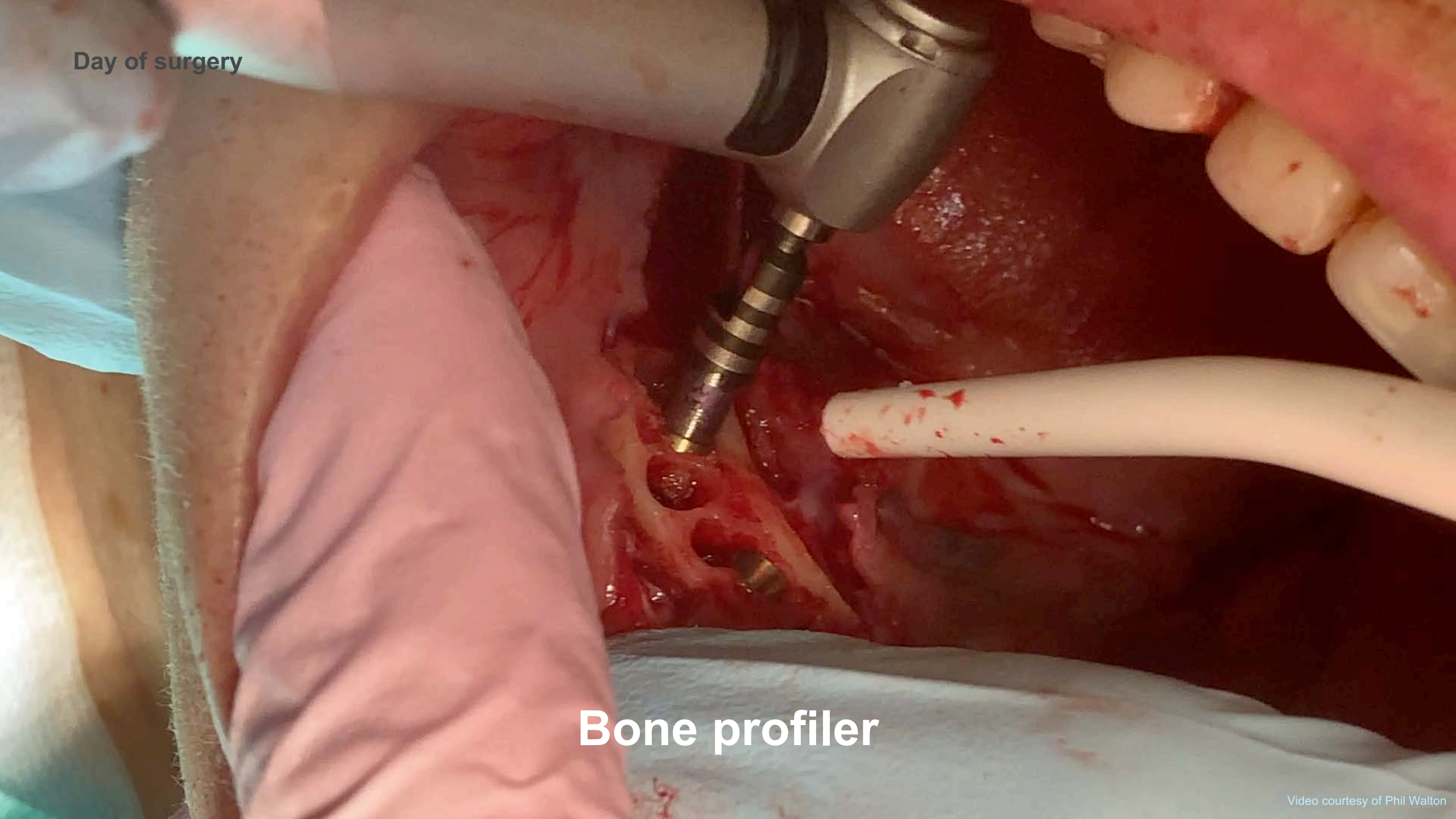
Implant insertion

Day of surgery



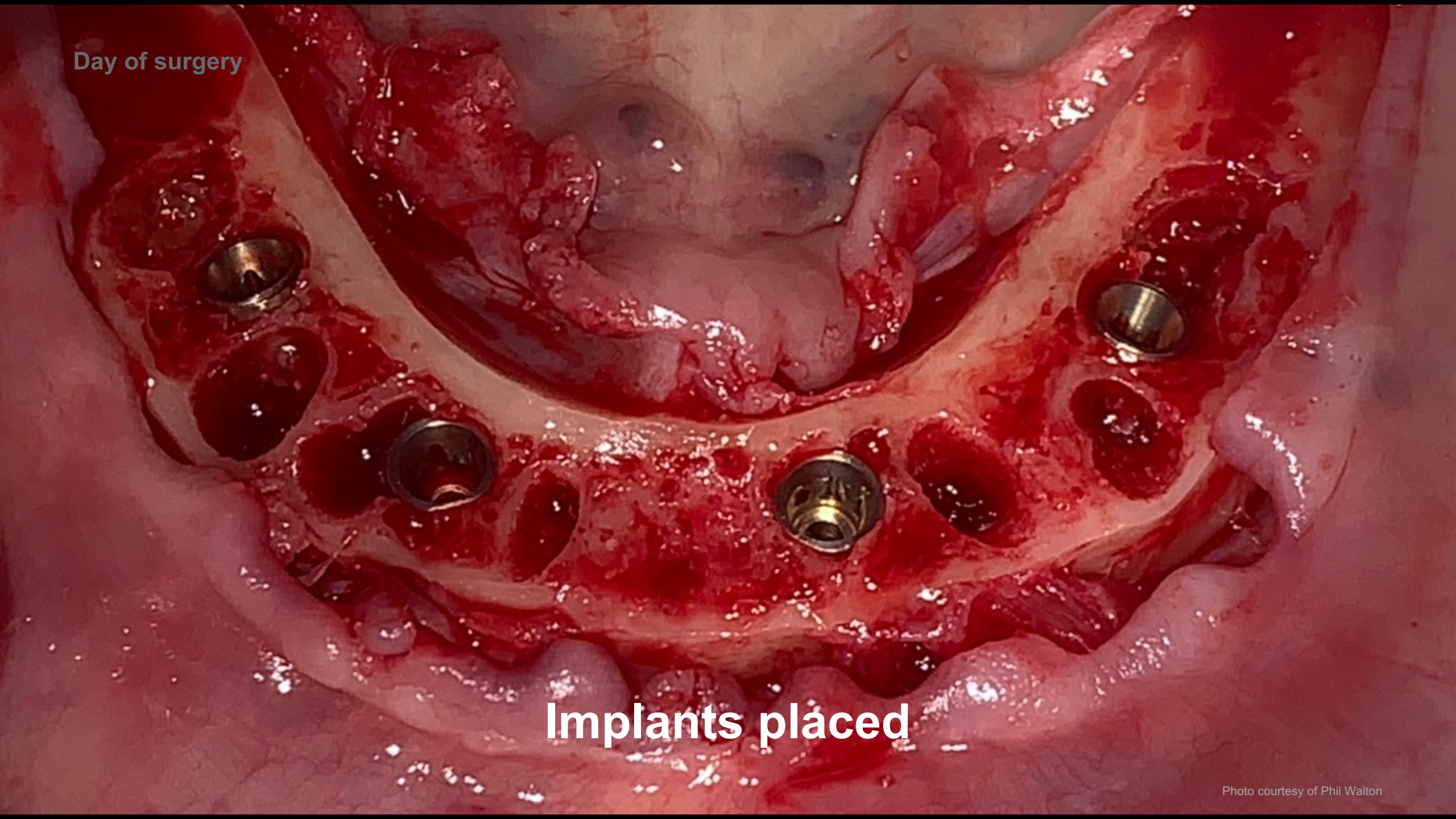
High insertion torque

Day of surgery



Bone profiler

Day of surgery



Implants placed

Day of surgery



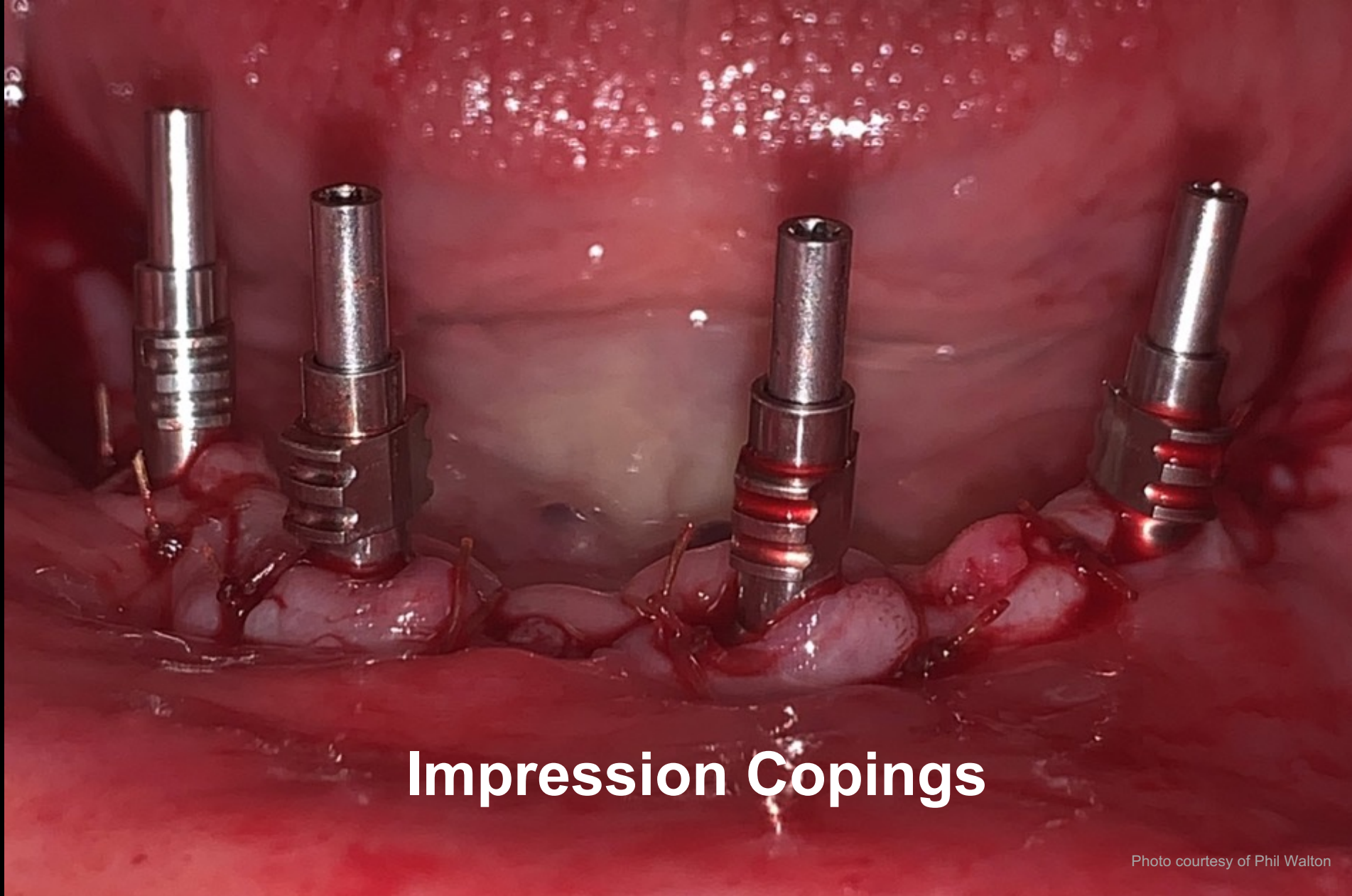
Multi-unit Abutment Xeal™

Photo courtesy of Phil Walton

Day of surgery

Multi-unit Abutments Xeal™

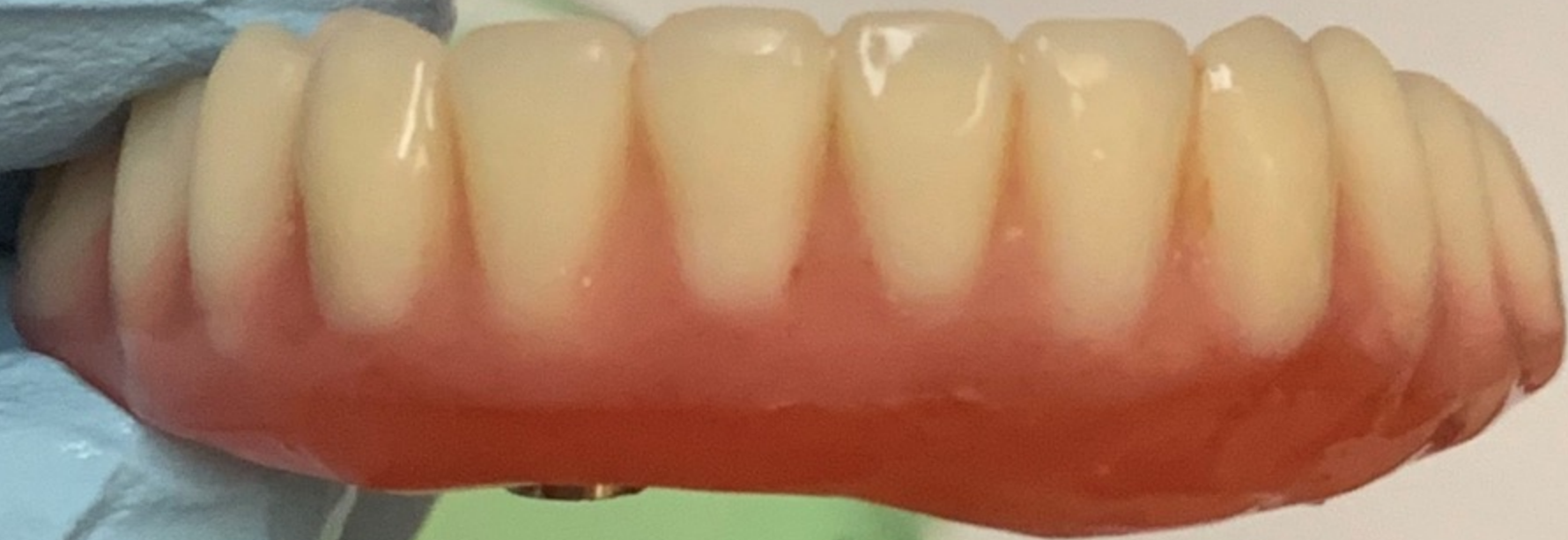Day of surgery



Impression Copings

Photo courtesy of Phil Walton

Day of surgery



PMMA prosthetic

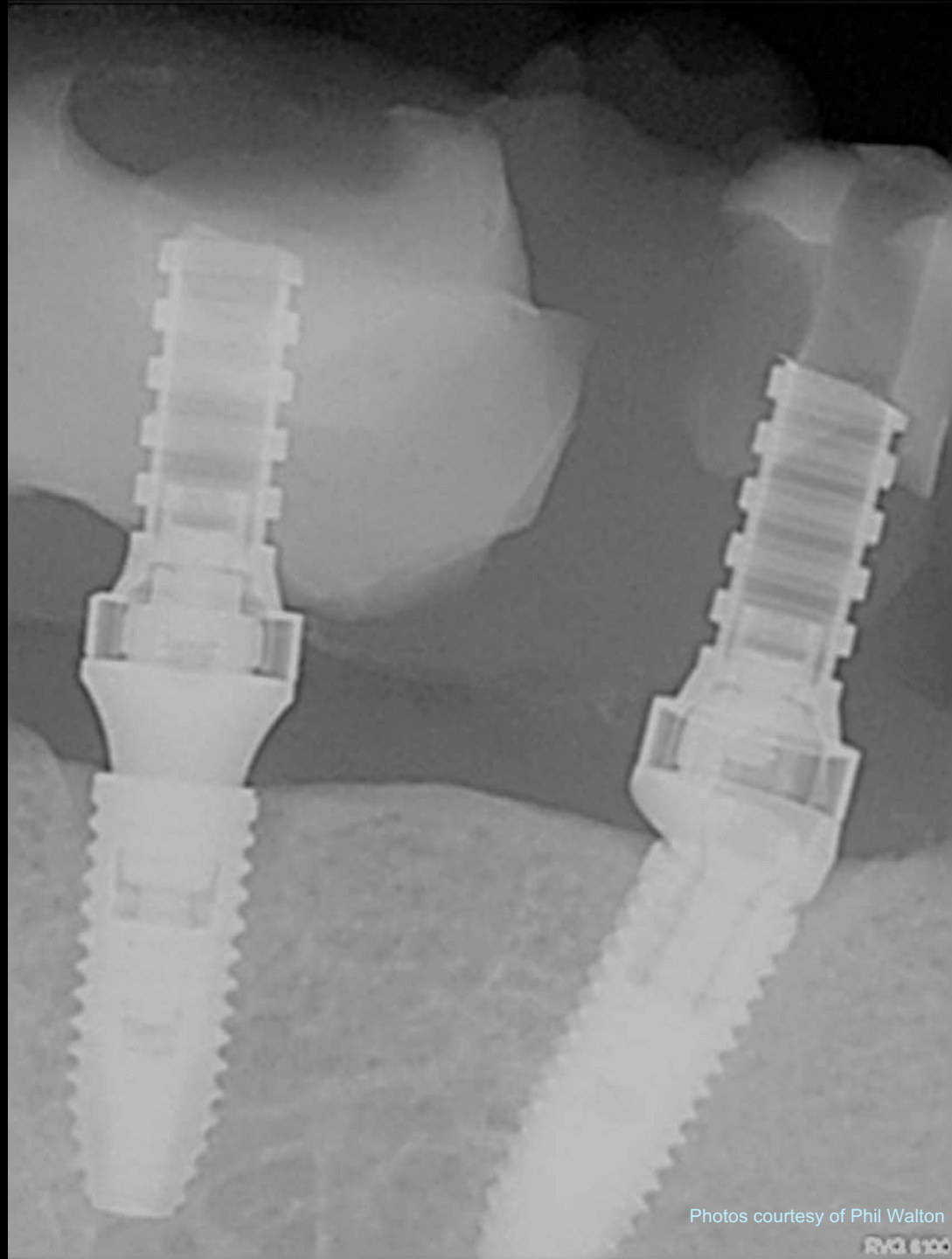
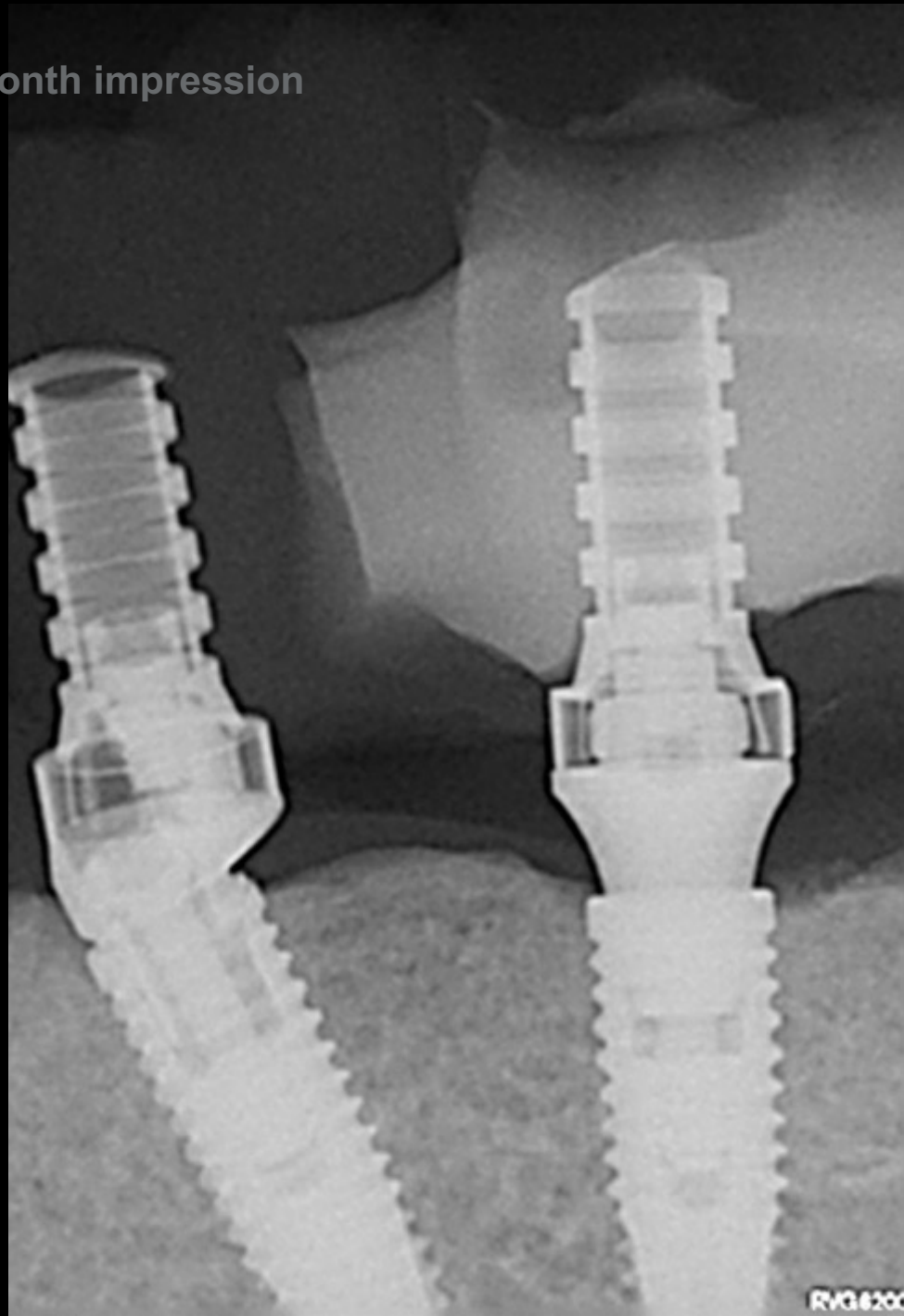
Day of surgery

Temporary

Temporary

6-month impression

6-month impression

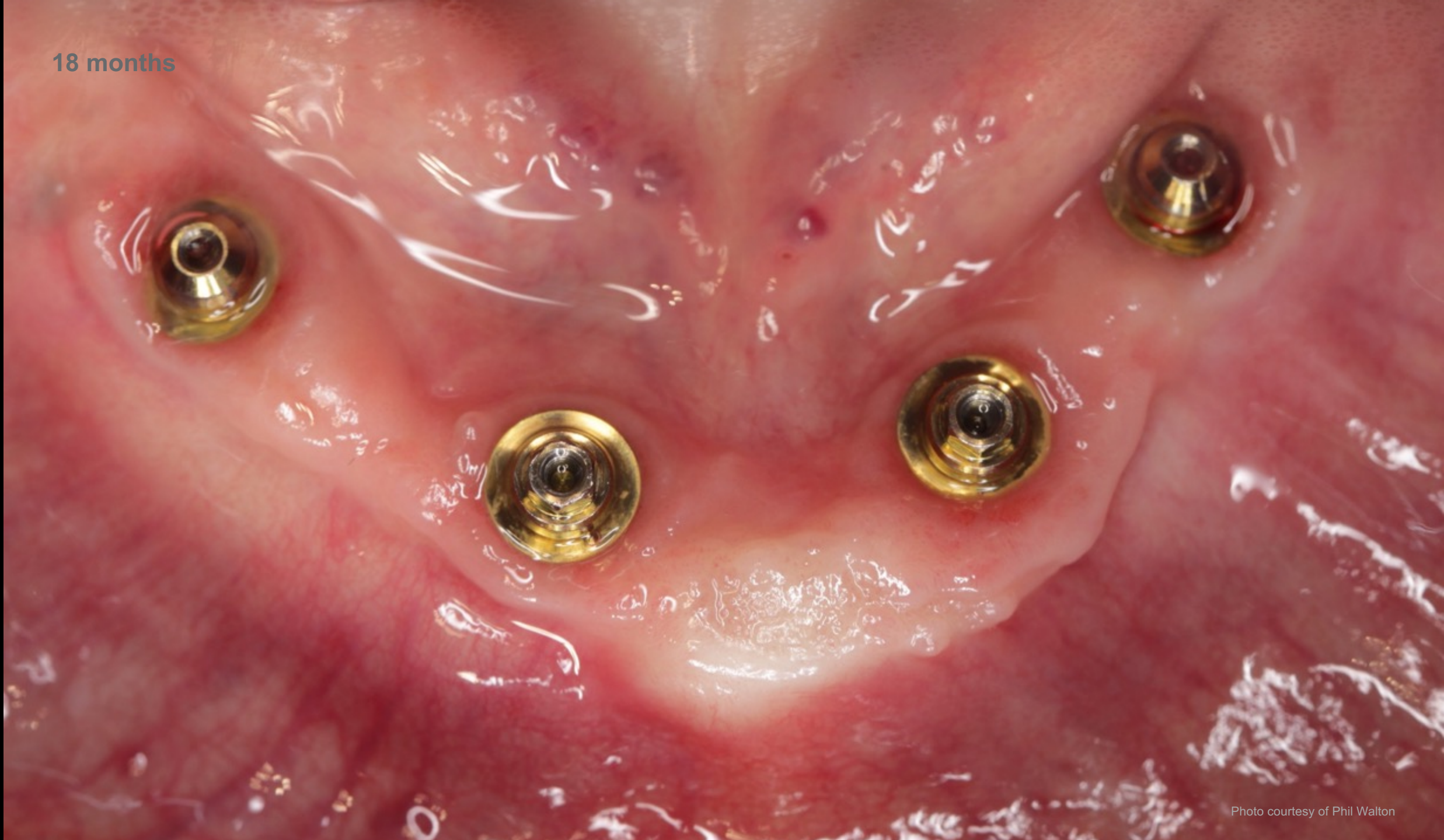

Photos courtesy of Phil Walton

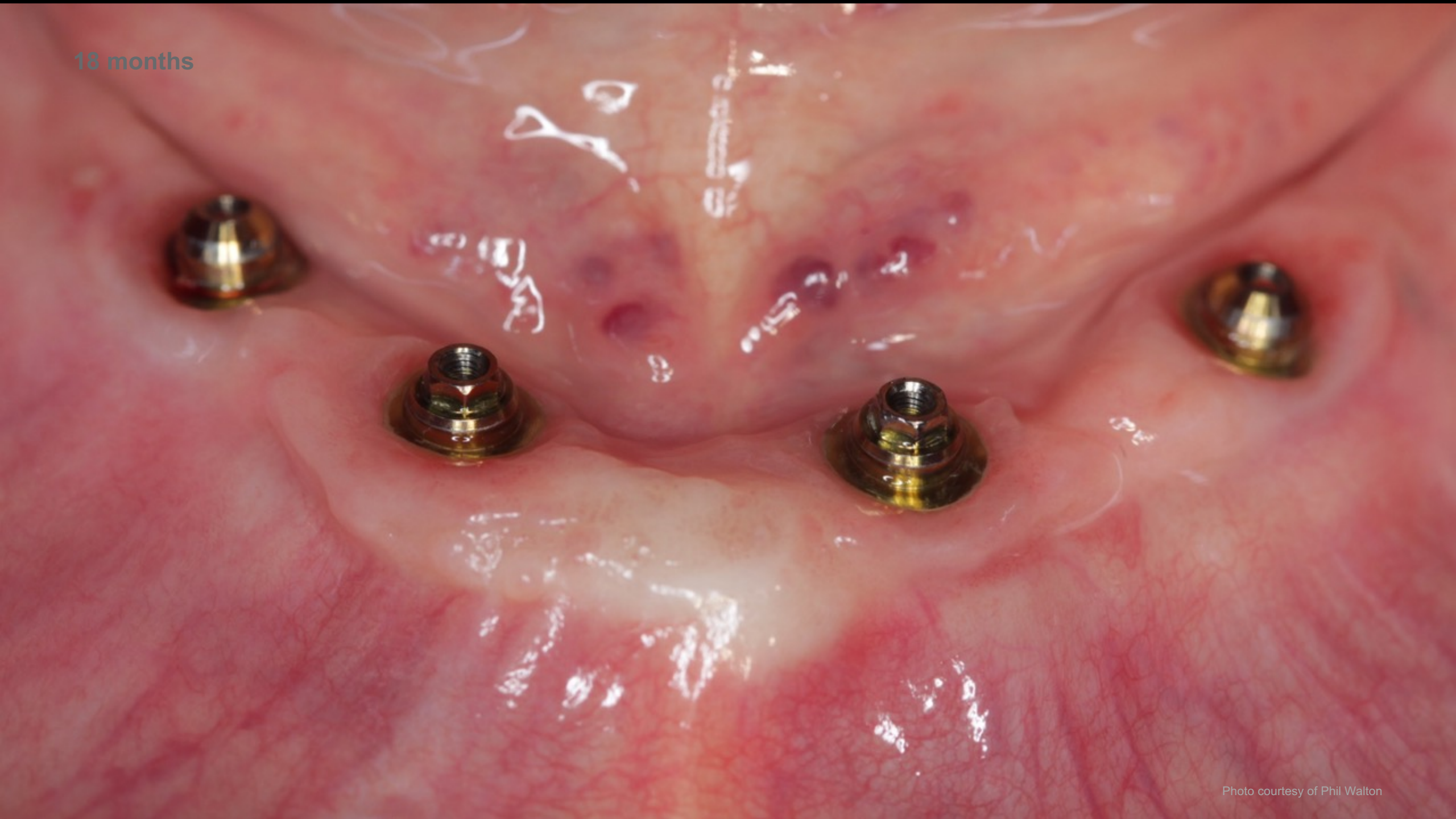RVG 6100

18 months

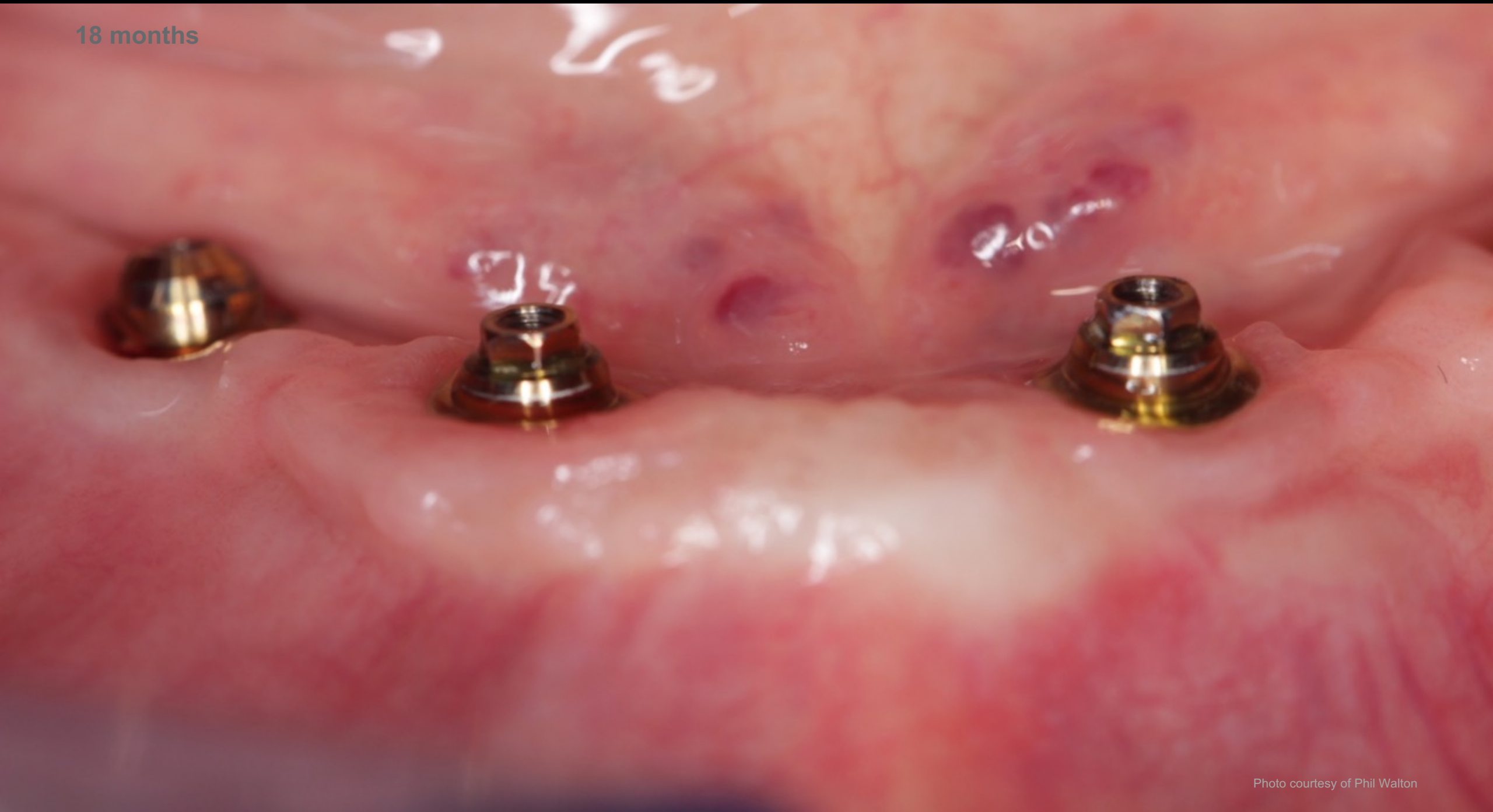18 months



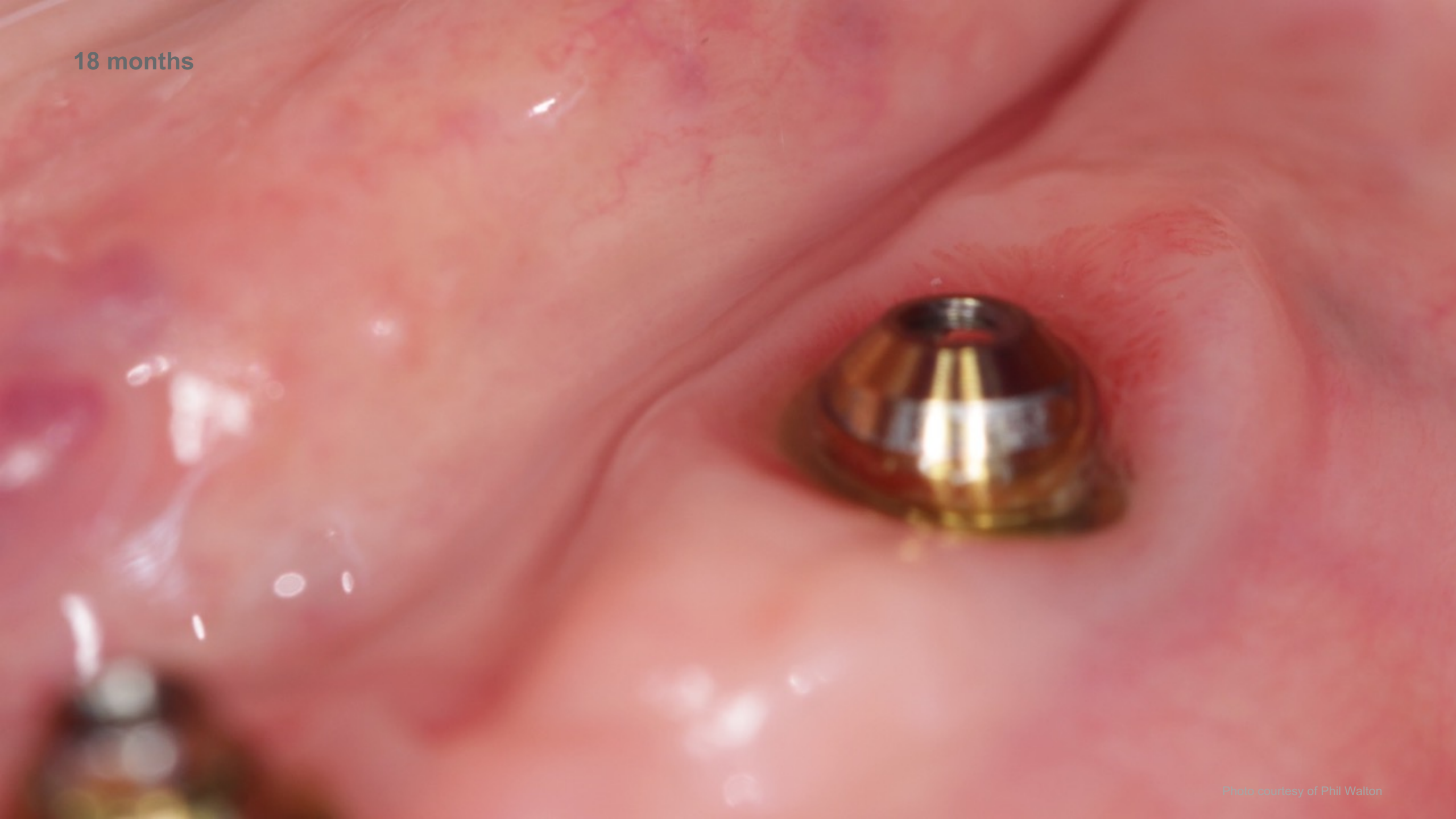18 months



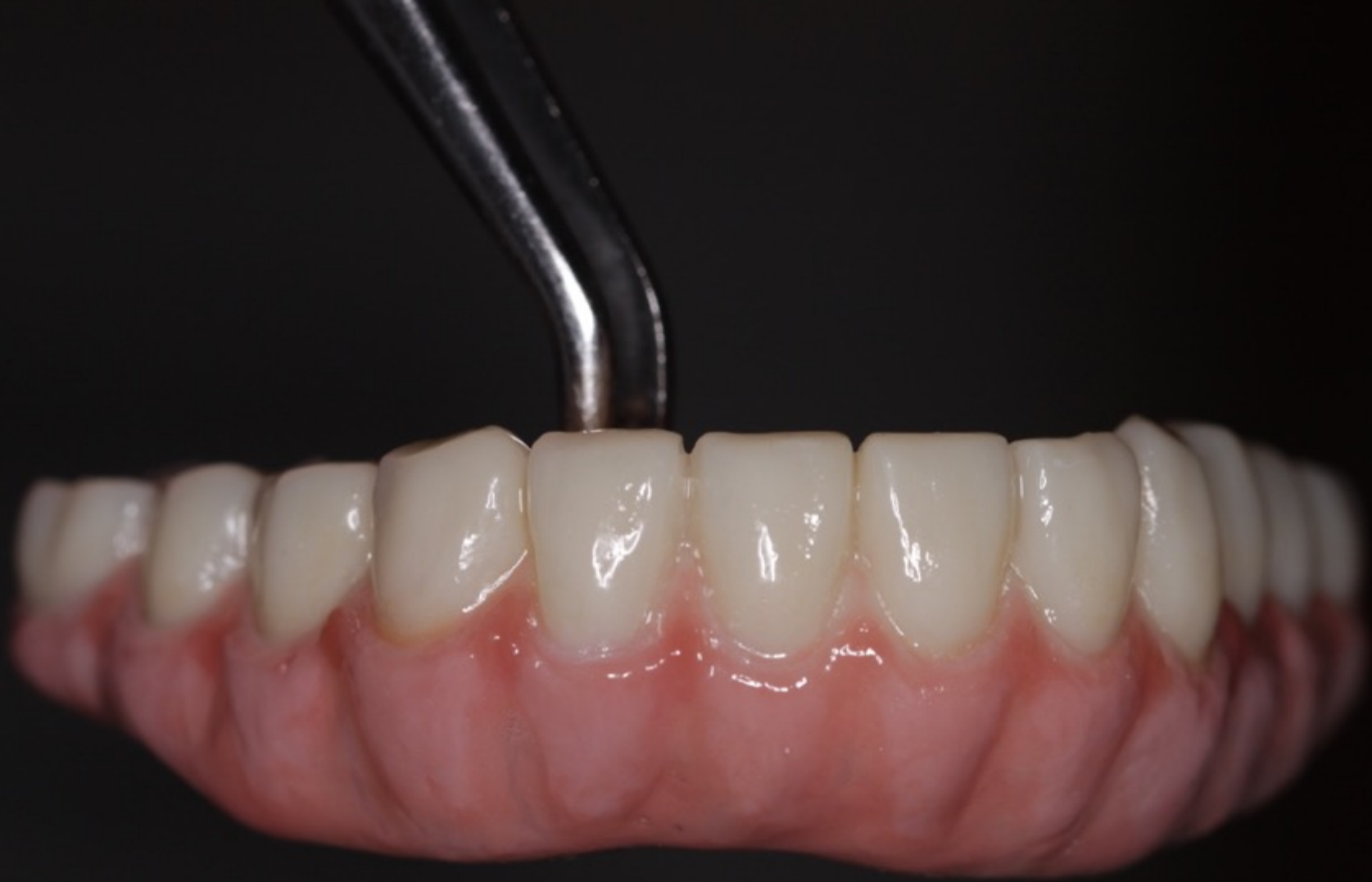18 months



18 months

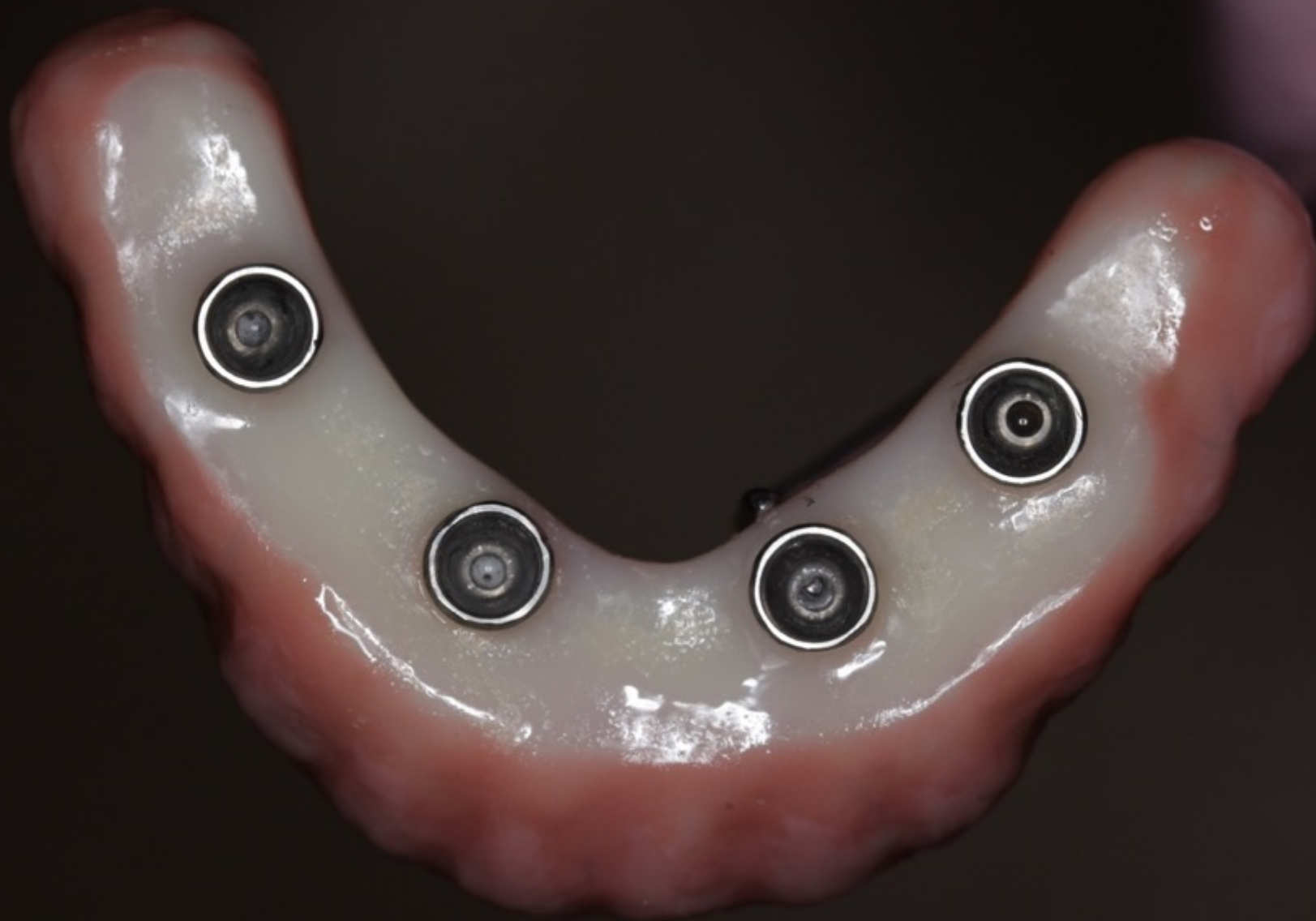

18 months



Zirconia final

18 months



Intaglio surface

18 months

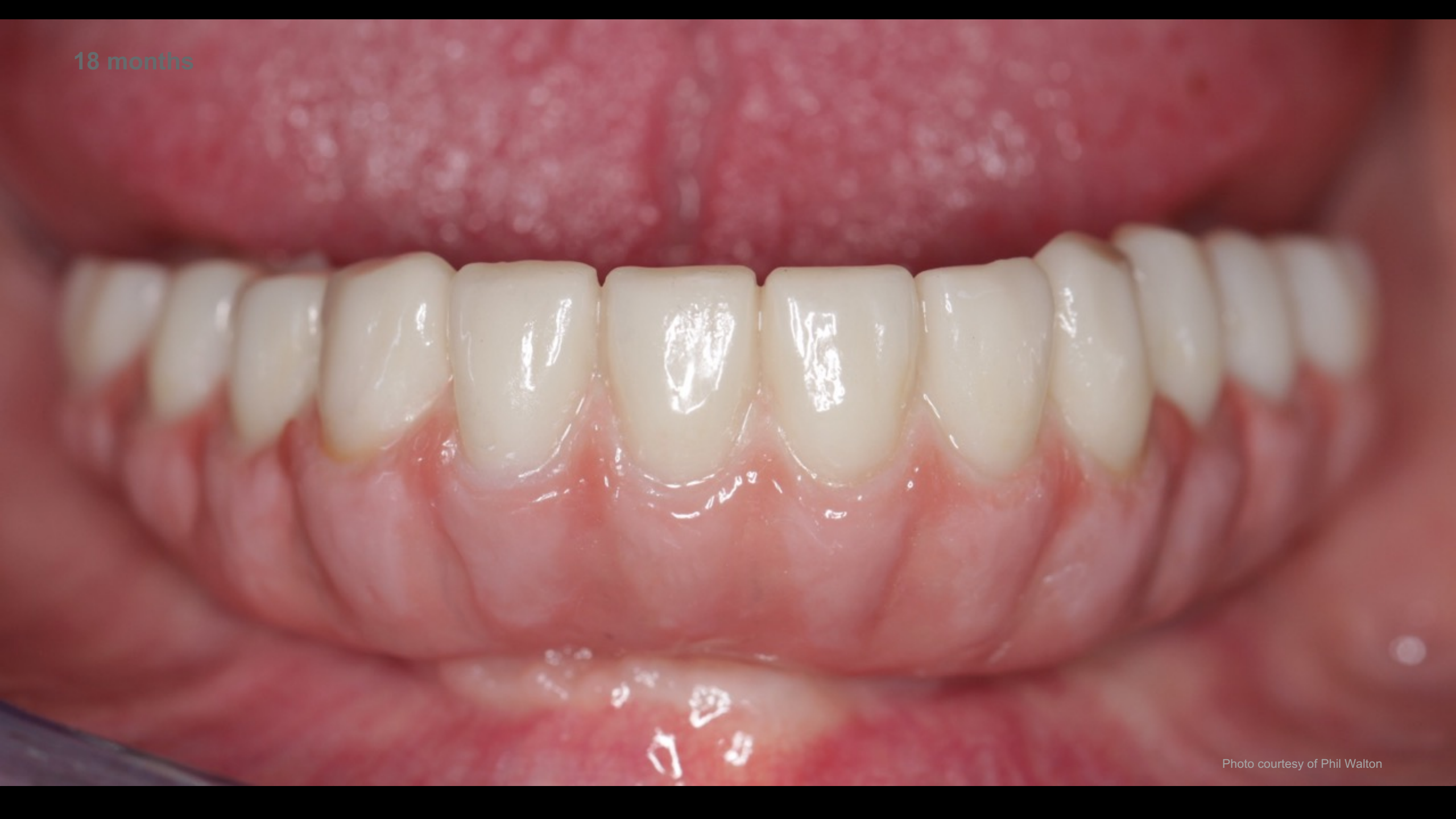

Photo courtesy of Phil Walton

18 months

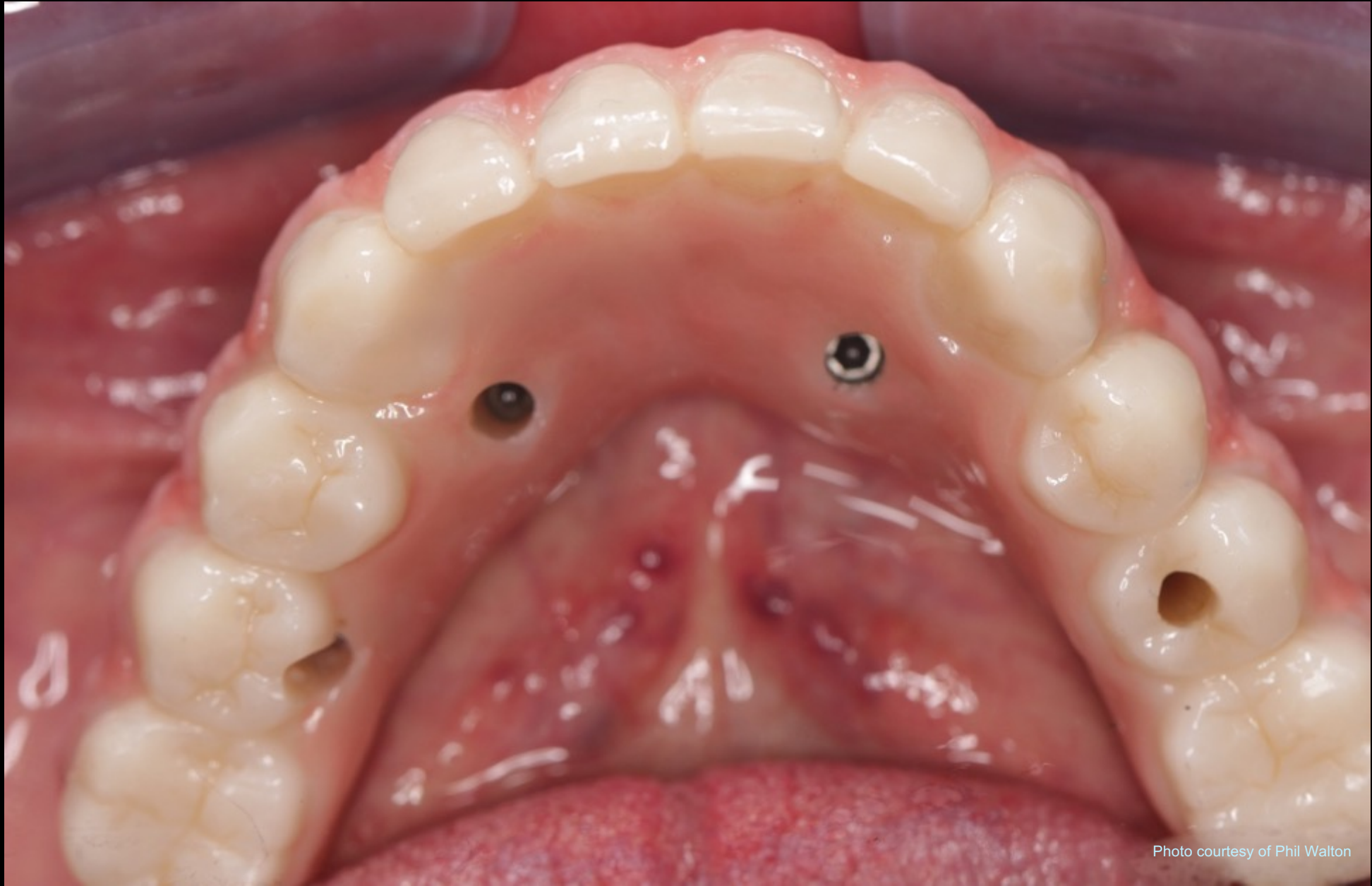


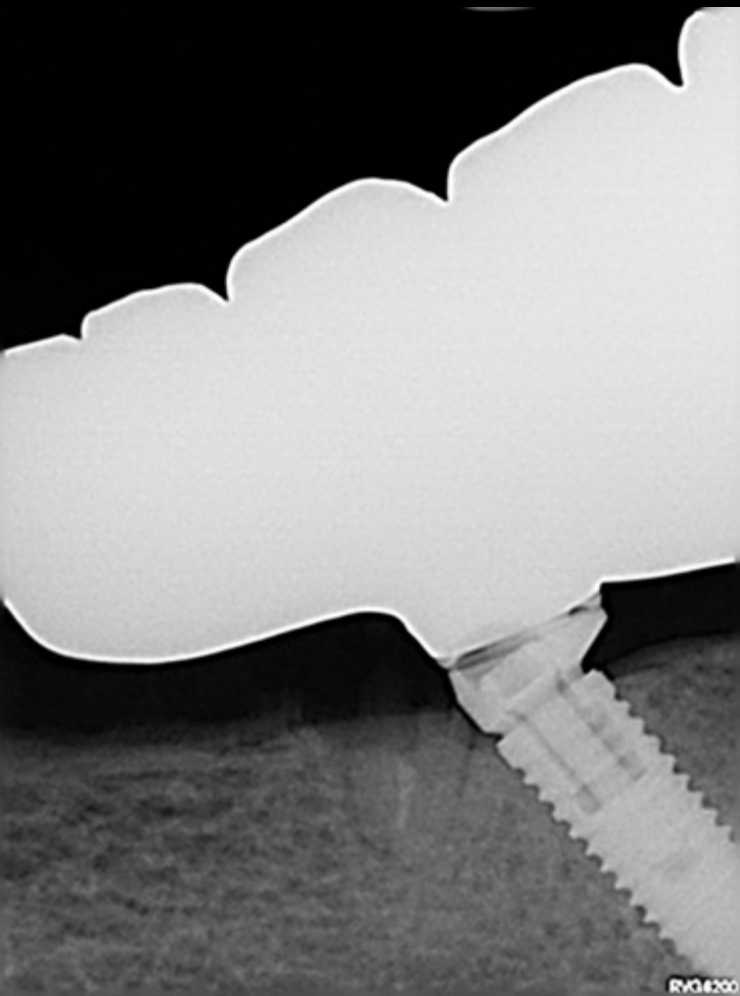
Photo courtesy of Phil Walton

18 months

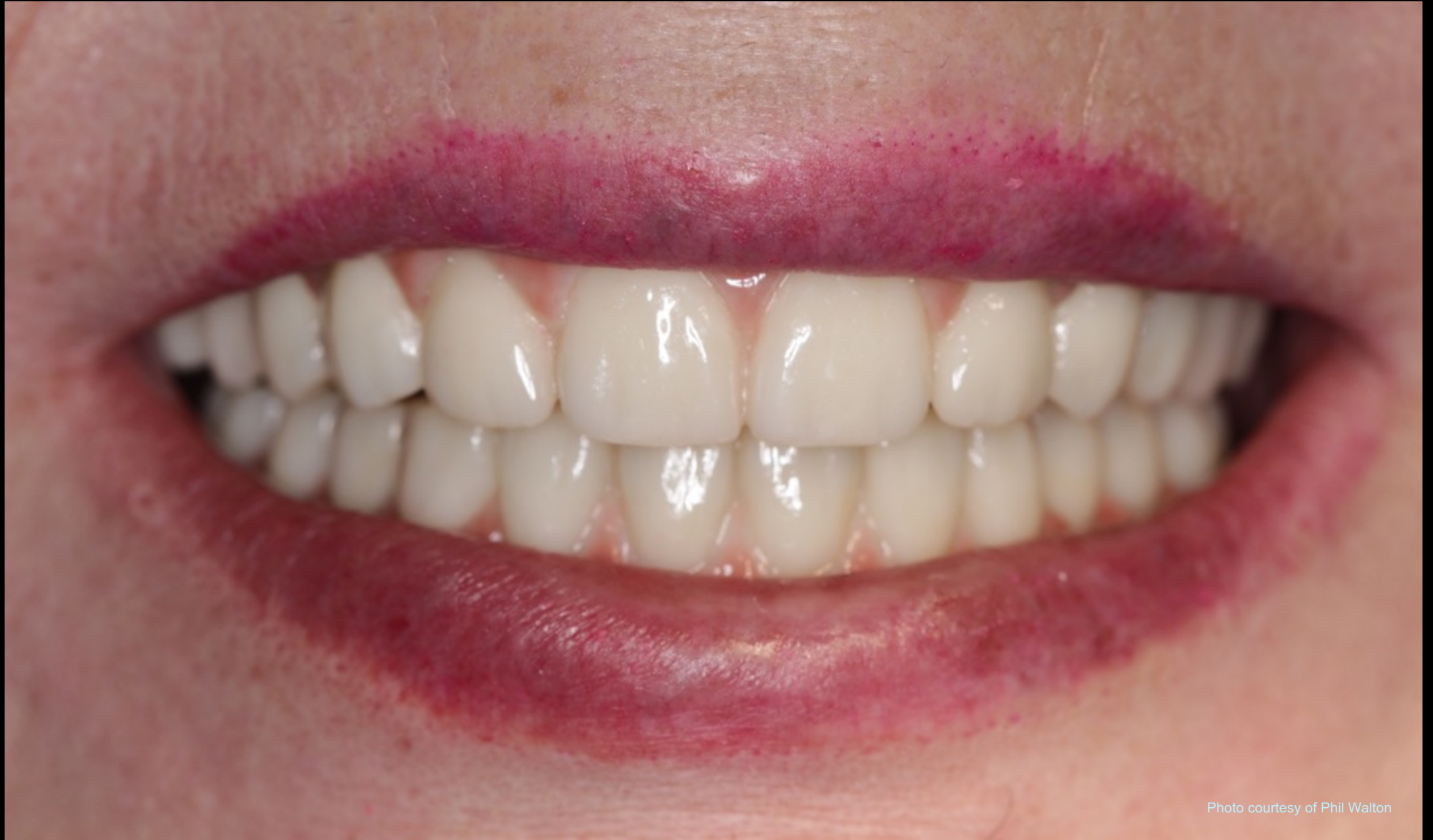

Photo courtesy of Phil Walton

18 months



Case courtesy of Dr. Phil Walton



Copying or reproducing this presentation or any portion thereof without permission is expressly prohibited.

MKT-4921 Rev. 00 (03/21, GMT 73821) © Nobel Biocare USA, LLC, 2021. All rights reserved. Nobel Biocare, the Nobel Biocare logotype and all other trademarks are, if nothing else is stated or is evident from the context in a certain case, trademarks of Nobel Biocare. Please refer to nobelbiocare.com/trademarks for more information. Product images are not necessarily to scale. Please contact the local Nobel Biocare sales office for current product assortment and availability. Caution: Federal (United States) law restricts this device to sale by or on the order of a dentist or physician. See Instructions For Use for full prescribing information, including indications, contraindications, warnings and precautions. Nobel Biocare does not take any liability for any injury or damage to any person or property arising from the use of this clinical case. This clinical case is not intended to recommend any measures, techniques, procedures or products, or give advice, and is not a substitute for medical training or your own clinical judgement as a healthcare professional. Viewers should never disregard professional medical advice or delay seeking medical treatment because of something they have seen in this clinical case. Full procedure is not shown. Certain sequences have been cut.