

Extraction site preservation



Dan Holtzclaw, DDS, MS.
Austin, Texas, USA

“The use of blended bone allograft containing a 70:30 ratio of mineralized to demineralized cortical bone particulate can be successfully utilized to facilitate the placement of dental implants with as little as 12 to 14 weeks of healing”

Patient information:

60-years-old male, well controlled diabetes and hypertension, no drug allergies, no history of tobacco use, complaint of pain and swelling at the mandibular first right molar.

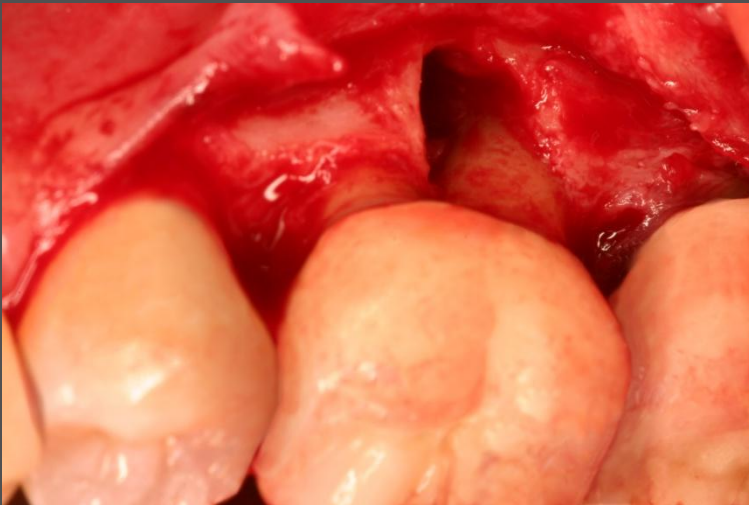
Indication:

Significant dehiscence defect of mandibular buccal plate, tooth extraction necessary.

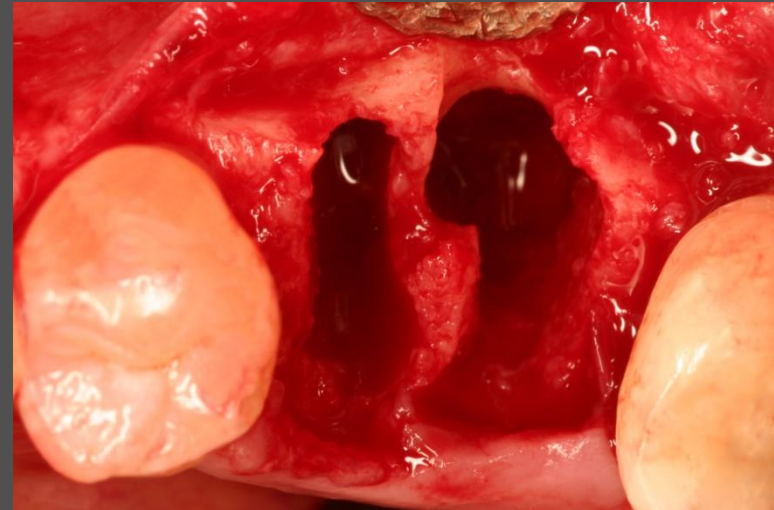
Solution:

Extraction of hopeless tooth, followed by bone grafting with creos allo.gain 70/30 mineralized/demineralized bone particulate, and covered with a barrier membrane. After 3 months of healing, a NobelSpeedy Replace implant was placed.

Extraction site preservation

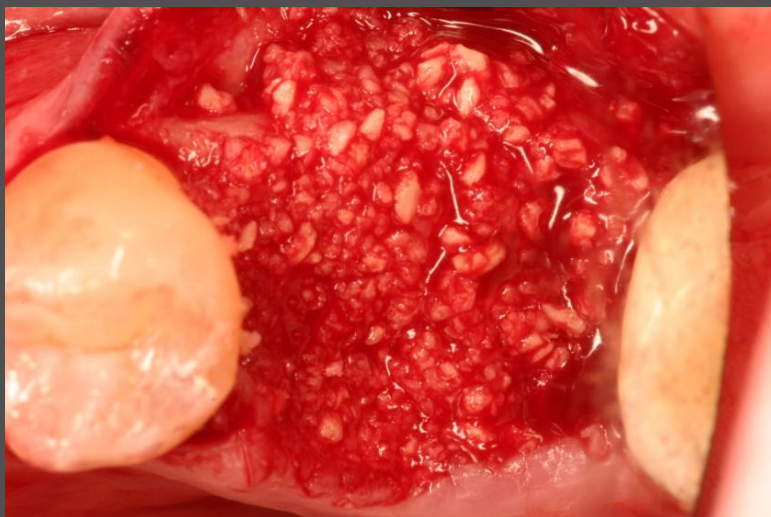


Dehiscence defect of mandibular buccal plate prior to tooth extraction.

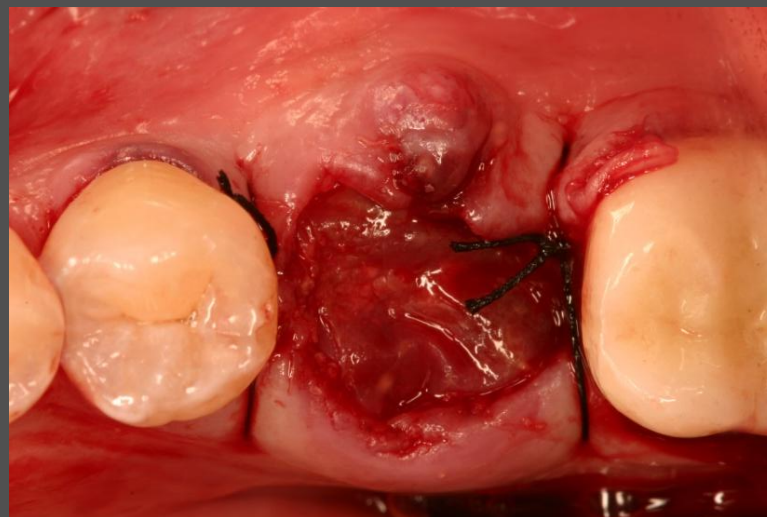


Significant bone deficiency following tooth extraction and degranulation.

Extraction site preservation

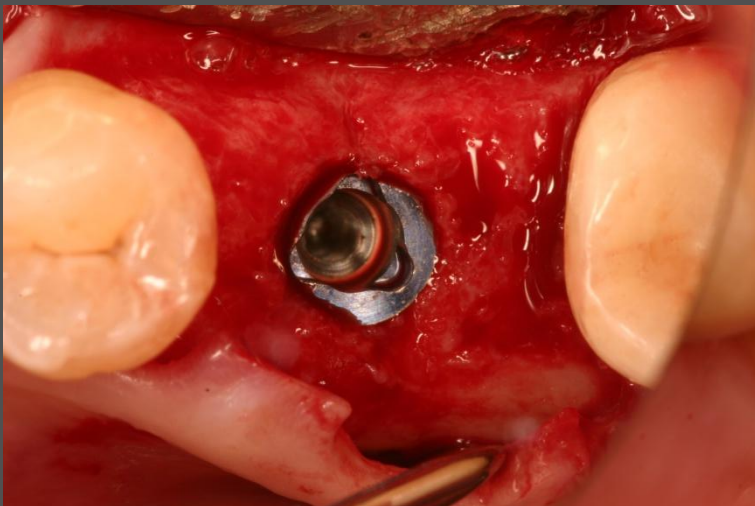


Placement of creos allo.gain 70/30 mineralized/ demineralized bone particulate.

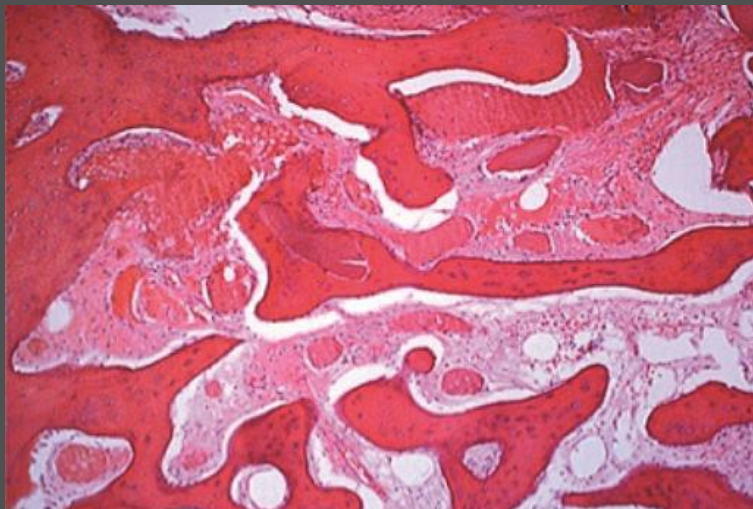


Intentional non-primary closure of the surgical site following site preservation.

Extraction site preservation



Note significant bone regeneration after only 3 months upon dental implant placement.



H&E stain of bone core sample from surgical site at the time of implant placement. Note live bone formation around the graft particles.