

# Esthetics with NobelProcera<sup>®</sup> Implant Crown



Luc and Patrick Rutten, Dental Technicians, Tessenderlo, Belgium  
Periodontics, Dr. Mic Demanet, Antwerp, Belgium  
Prosthodontics Dr. Roel Leroy, Antwerp, Belgium

*“New CAD/CAM products such as full-contour zirconia (FCZ), angulated screw channel (ASC) and high translucency multilayered zirconia (HT ML) have become an important products in our daily work. Due to the ASC concept it is possible to use screw-retained restorations in almost every situation.”*

**Patient:**

Male, 26 years old

**Clinical situation:**

Missing upper left lateral incisor.

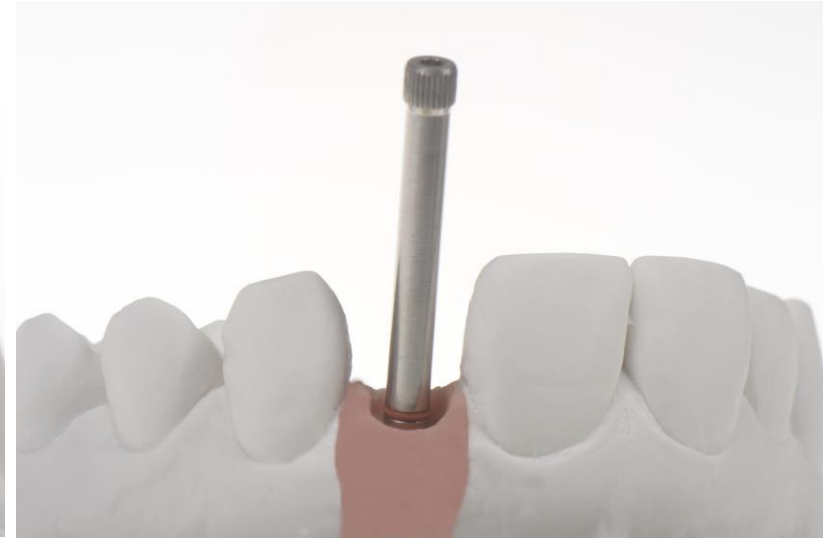
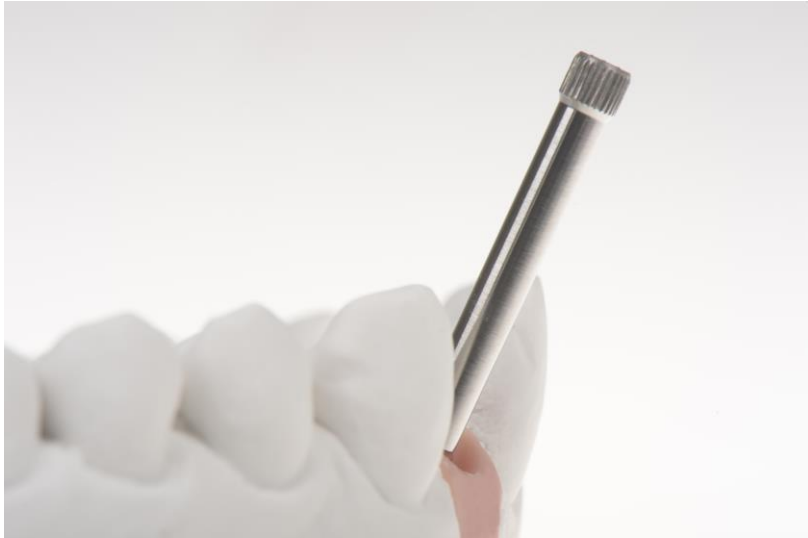After consultation with the dentist, a NobelActive NP Implant was chosen. The clinician preferred a screw-retained crown.

**Restorative solution:**

NobelProcera Implant Crown with angulated screw channel (ASC) was created with NobelProcera 2G scanner and the NobelDesign software.

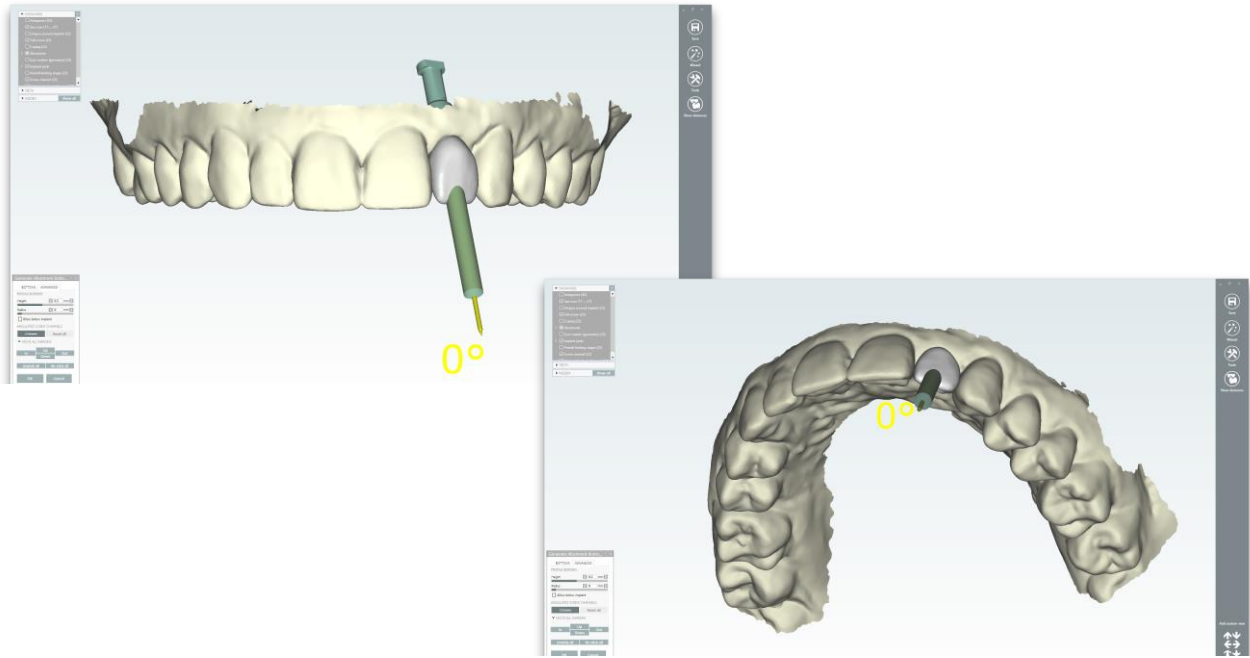
NobelDesign software allowed the design of ASC and reduction of the buccal plane by 0.5 mm. The cut-back was layered with small amount of dentine and translucency/enamel. Tooth morphology was chosen from a library which simplified the work.

# Esthetics with NobelProcera<sup>®</sup> Implant Crown

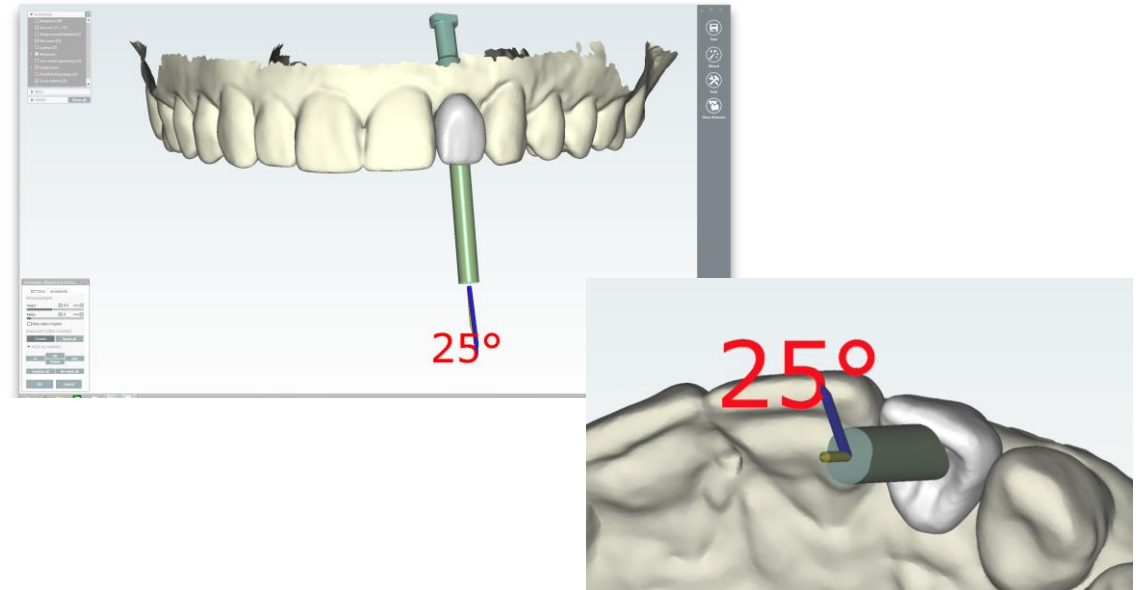


Master cast with guide pin showing the inclination of the implant from sagittal, occlusal and labial view.

# Esthetics with NobelProcera<sup>®</sup> Implant Crown

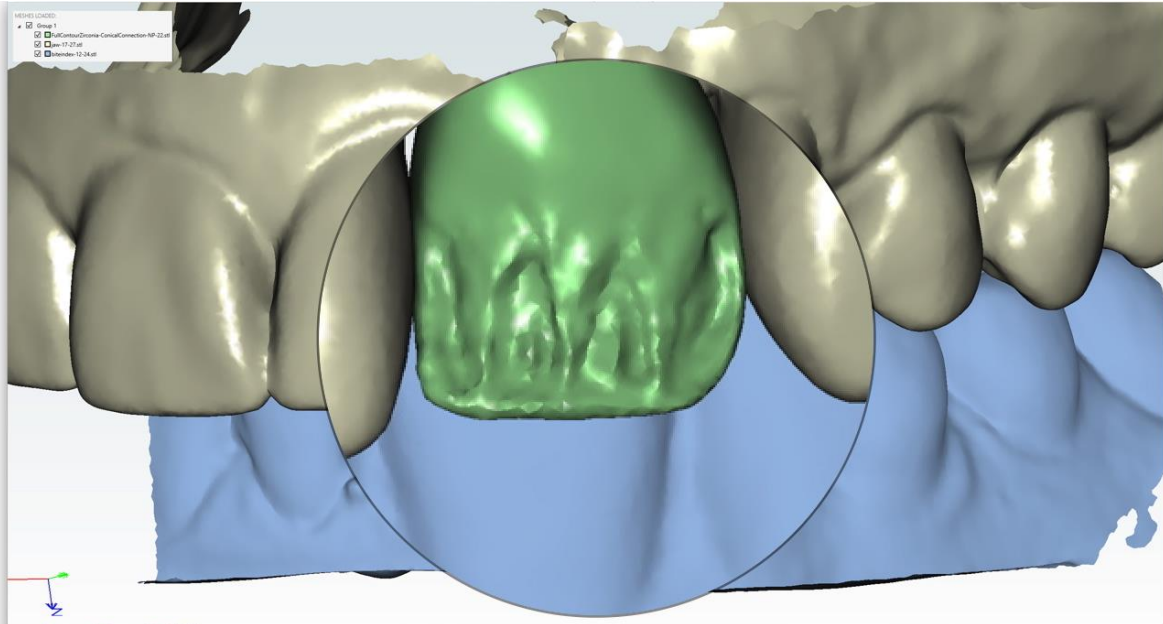


NobelDesign software shows the potential protrusion of the incisal edge when simulating a straight screw channel. Buccal and incisal view.

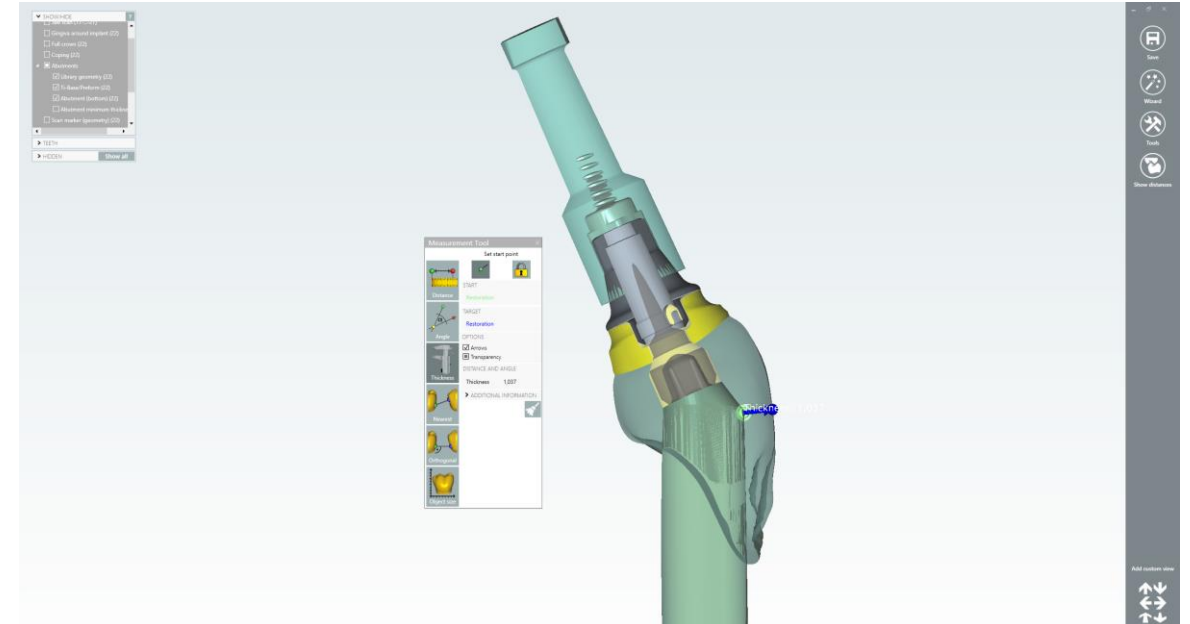


Design of the NobelProcera Implant Crown with 25° screw channel angulation to avoid damaging the incisal edge. Buccal and occlusal view.

# Esthetics with NobelProcera® Implant Crown

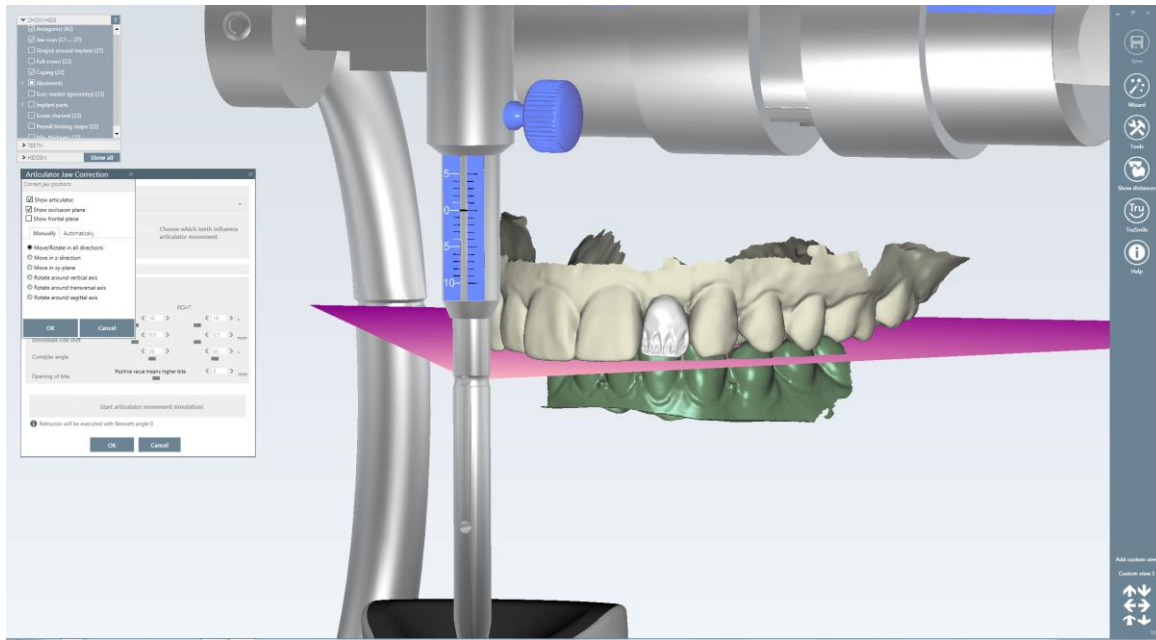


Design of the incisal edge by using cut-back tools of the NobelDesign software. Irregularities were designed to allow partial veneering.

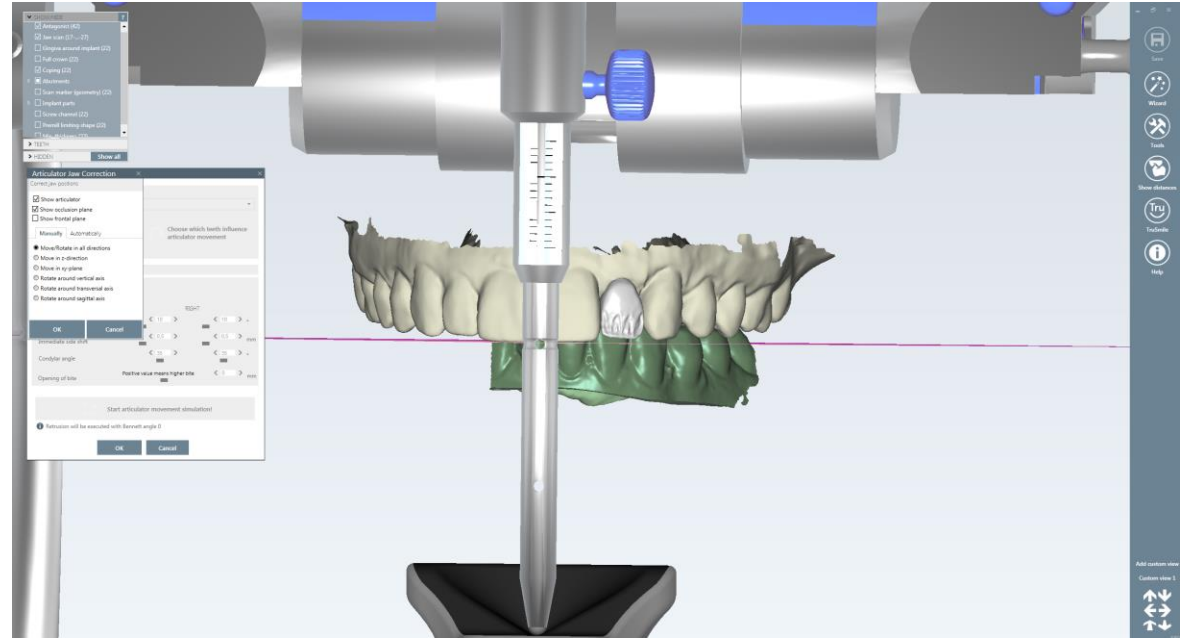


Cross section of the crown and angulated screw channel.

# Esthetics with NobelProcera® Implant Crown

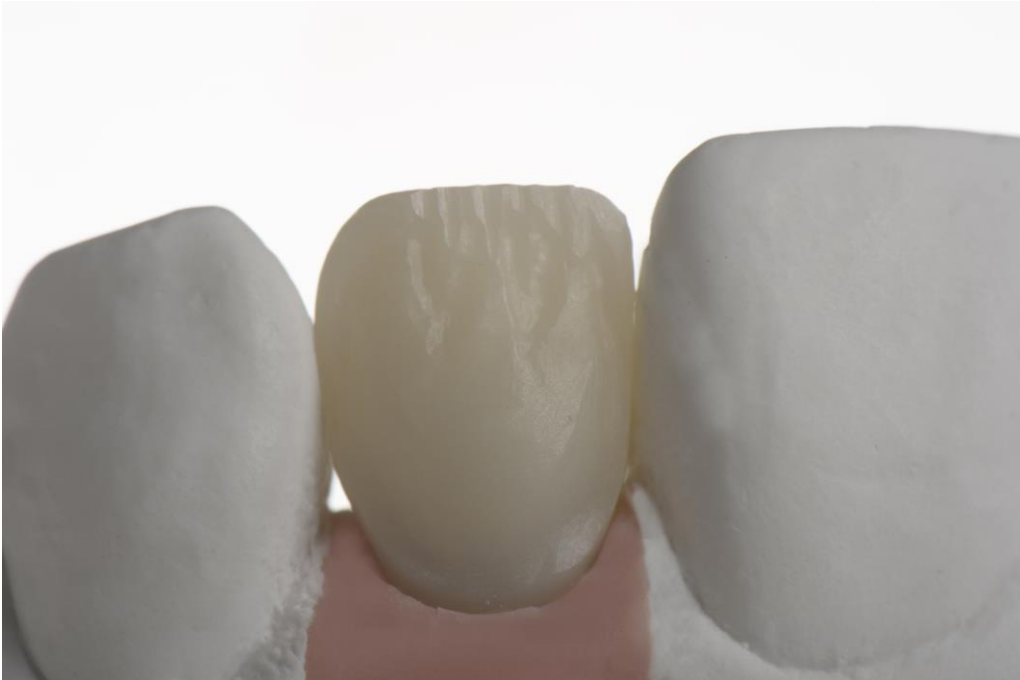

Mounted digitally in a virtual articulator according to Frankfort plane (purple line) with standard settings. Sagittal view.

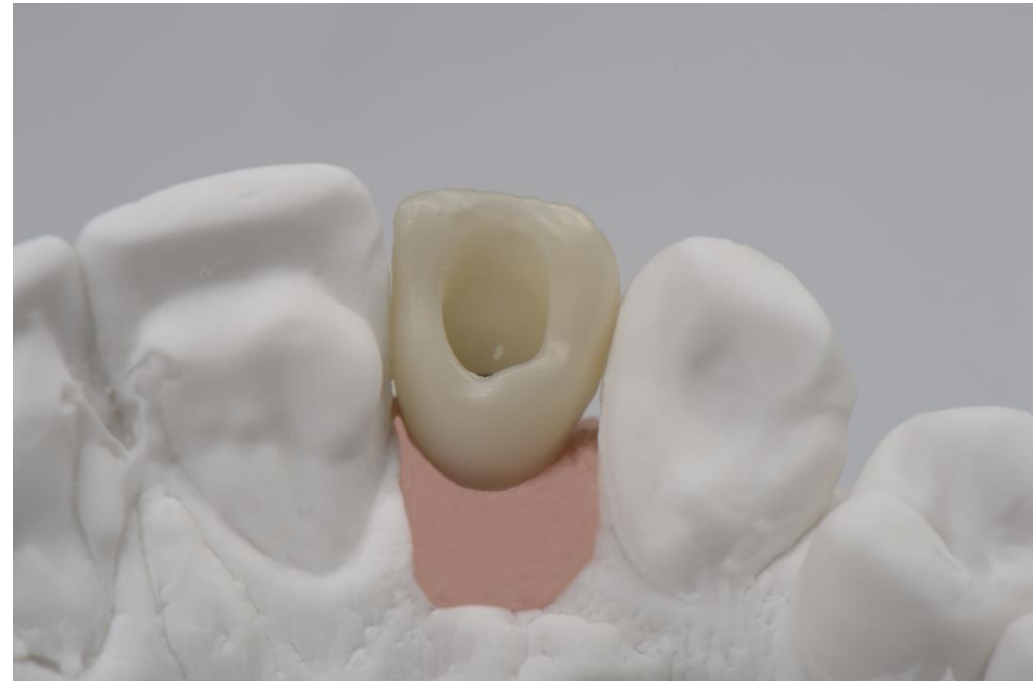

Buccal view.

# Esthetics with NobelProcera<sup>®</sup> Implant Crown

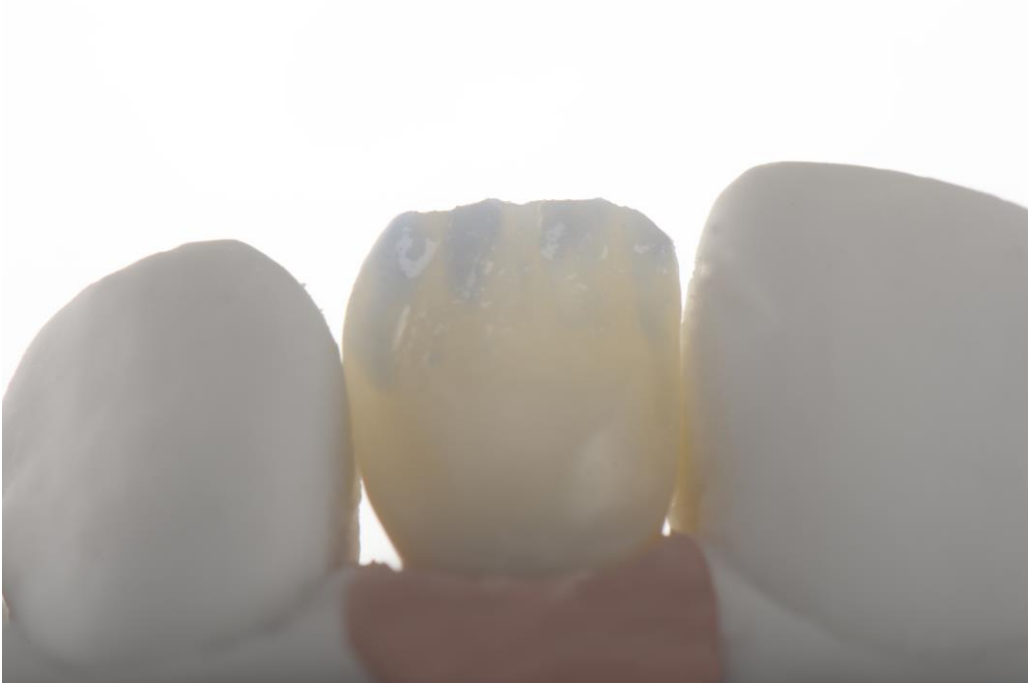

NobelProcera Implant Crown designed using NobelProcera 2G scanner and NobelDesign software. As received from centralized milling center.

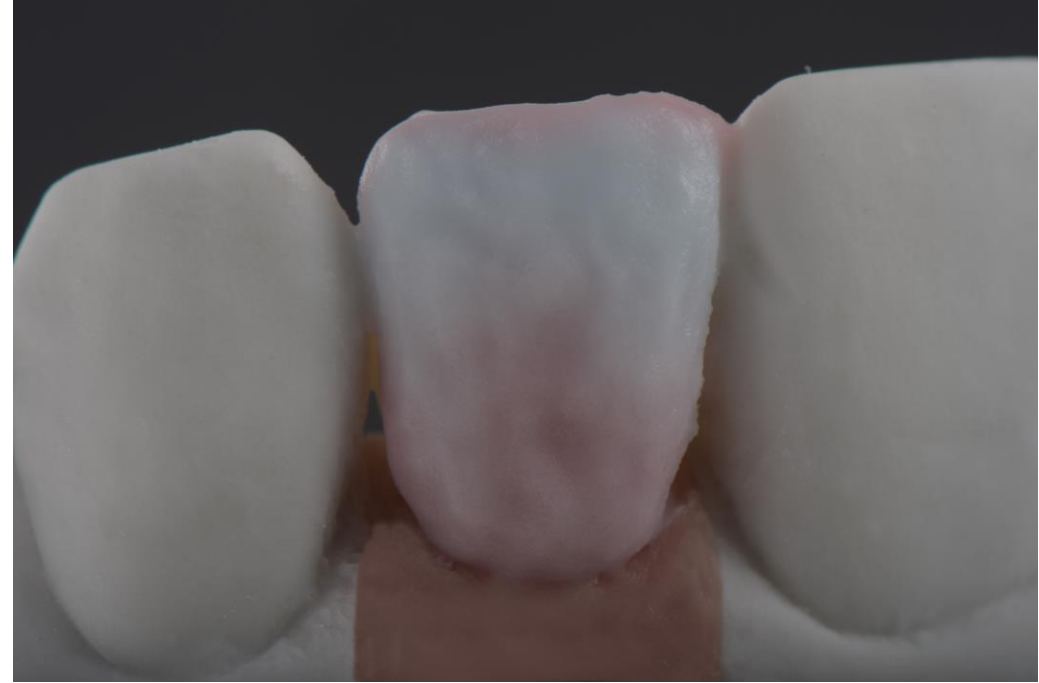

NobelProcera Implant Crown. Palatal view.  
Incisal edge has been built up in zirconia to avoid chipping of the layered part.

# Esthetics with NobelProcera<sup>®</sup> Implant Crown

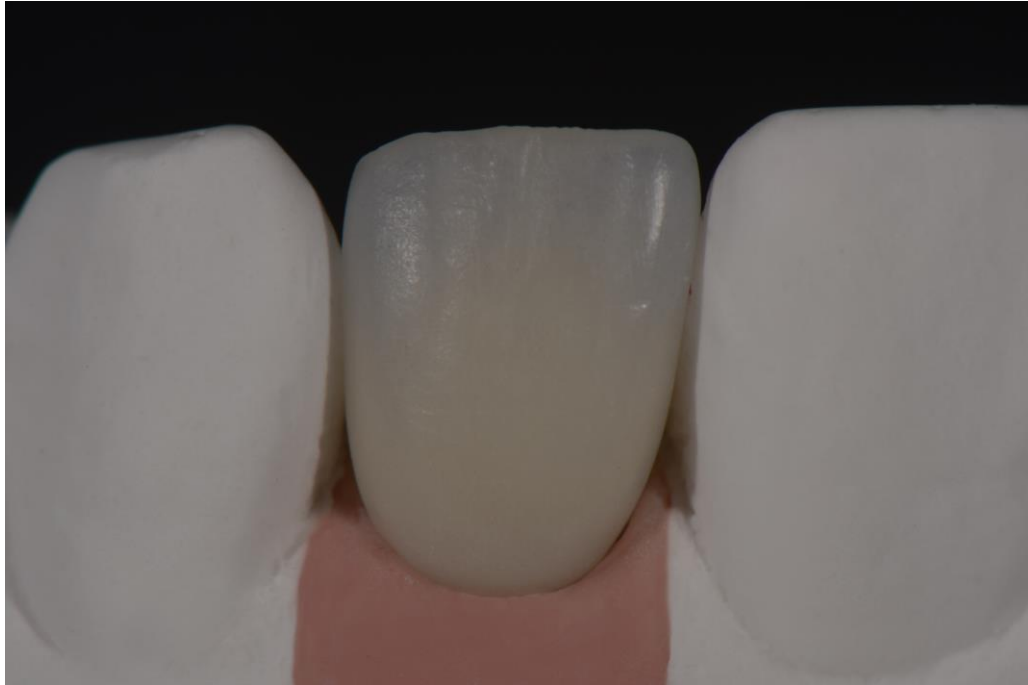

NobelProcera Implant Crown veneered with translucent material between the digitally designed dentin mamelons.



Tooth shape completed with dentin, enamel and the incisal halo effect.

# Esthetics with NobelProcera<sup>®</sup> Implant Crown



Finished bisque restoration on the master cast.



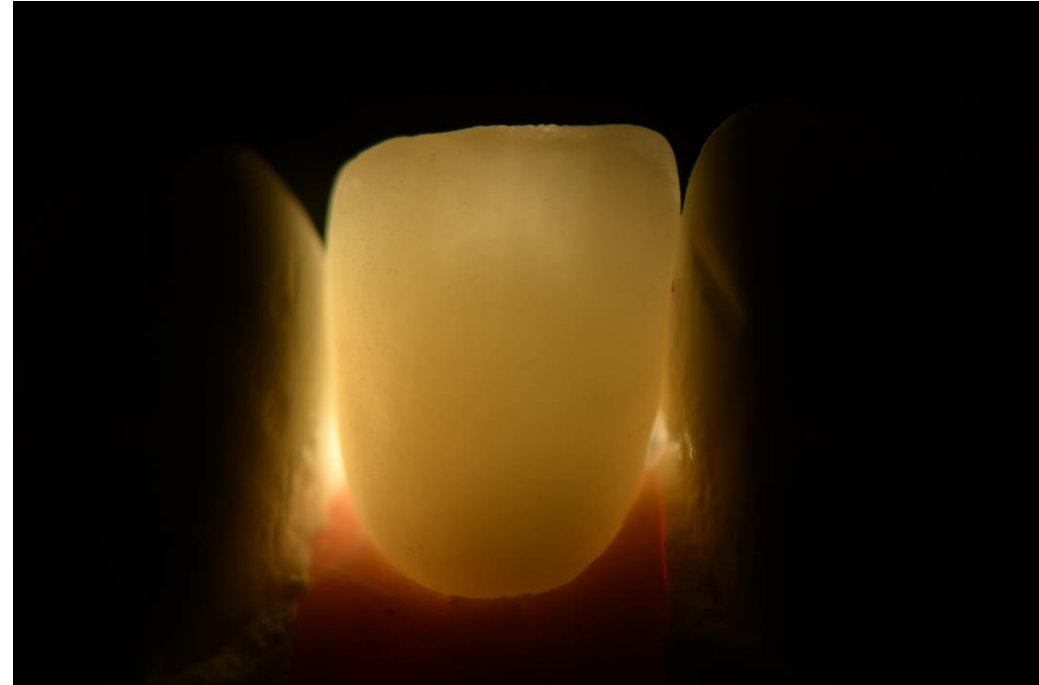Finalized NobelProcera Implant Crown with guide pin to show the protected incisal edge. The complete incisal edge is designed in zirconia.



# Esthetics with NobelProcera<sup>®</sup> Implant Crown

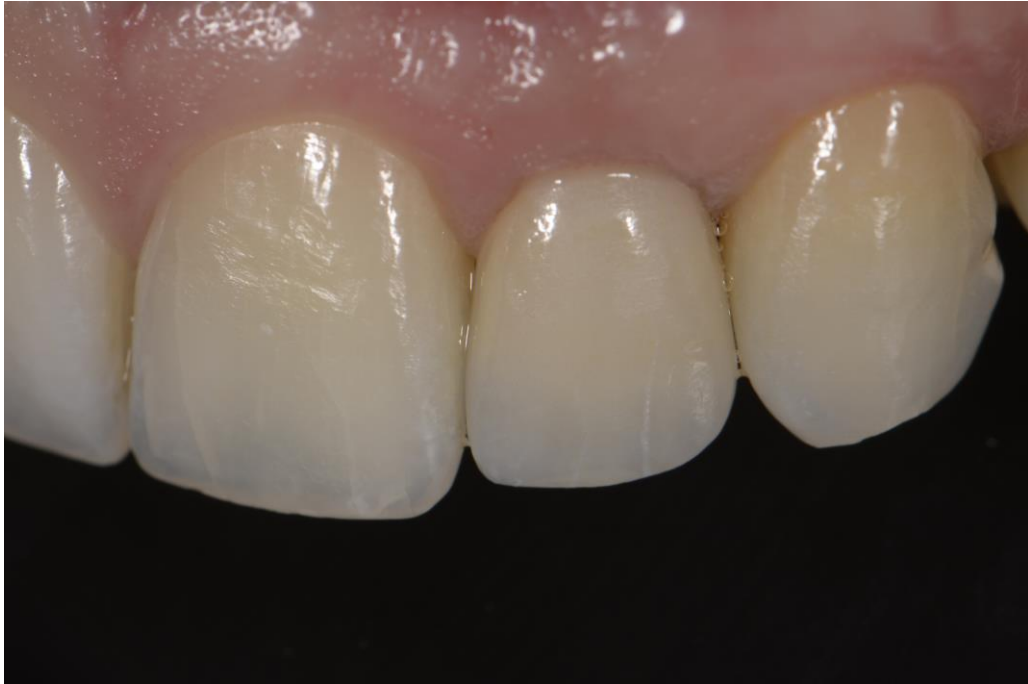

Showcasing that the body has more saturation and the incisal part more translucency.

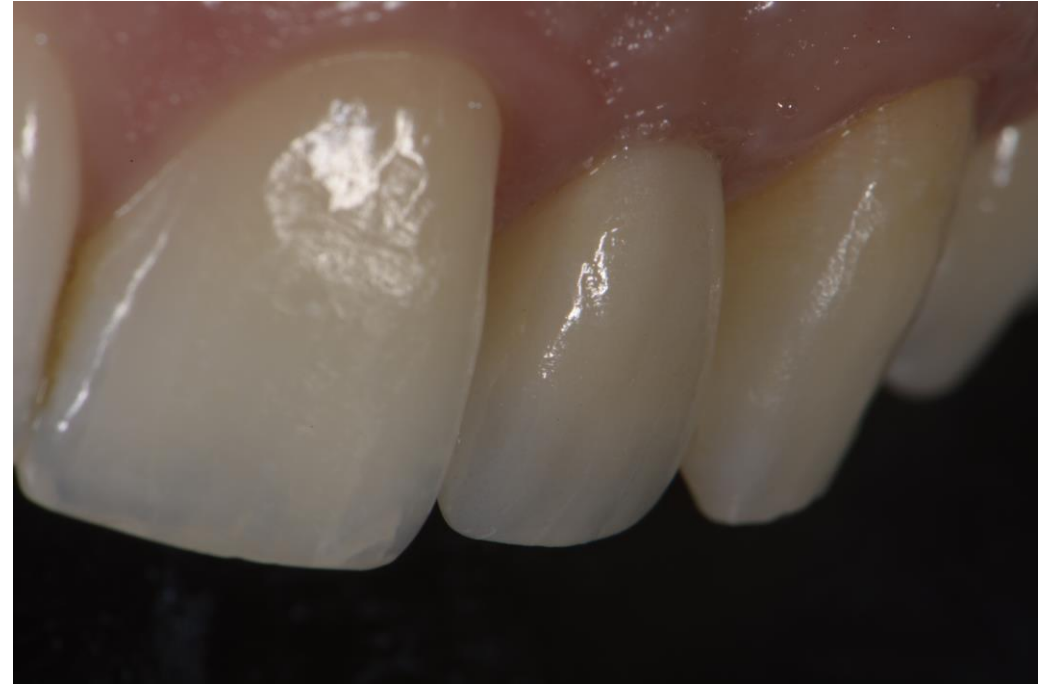

Finalized NobelProcera Implant Crown in transmitted light.

# Esthetics with NobelProcera<sup>®</sup> Implant Crown

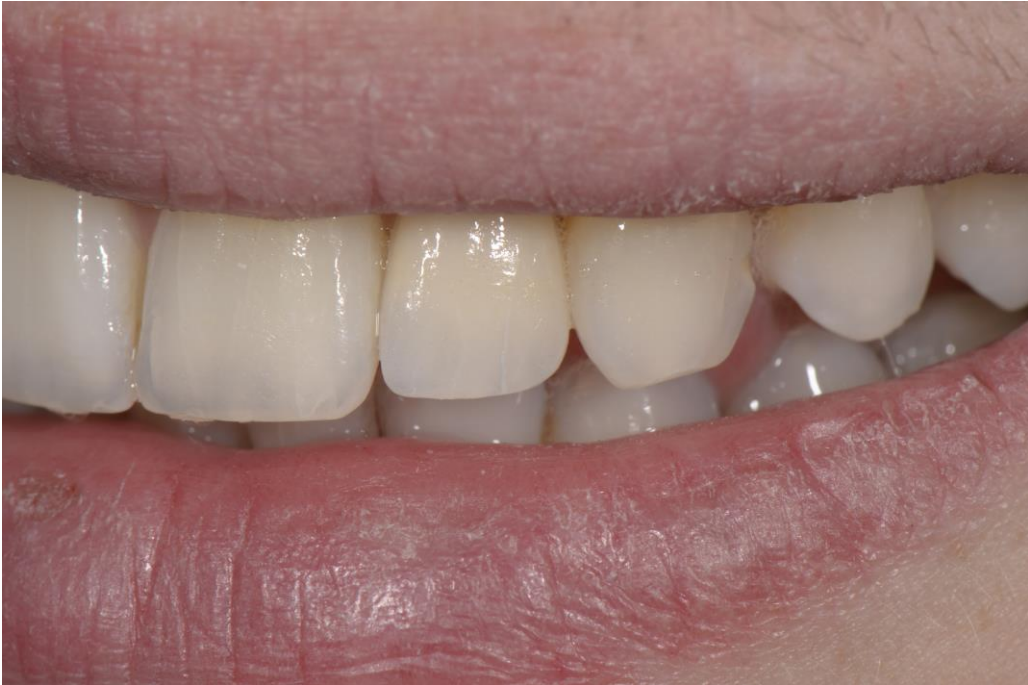

NobelProcera Implant Crown placed in patient's mouth.  
Healthy soft tissue and perfect emergence profile.

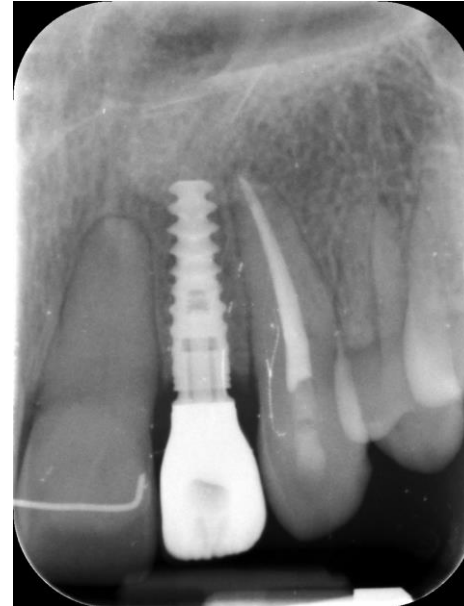

Good integration in the oral environment.

# Esthetics with NobelProcera<sup>®</sup> Implant Crown



Smile line: Partially veneered zirconia restoration chosen to better create the texture and luster on feldspathic ceramic instead of on a zirconia surface. This is more important on the anterior than posterior.



X-ray taken six months after placing the final restoration.